

Available online at [www.sciencedirect.com](http://www.sciencedirect.com)

ScienceDirect

journal homepage: [www.e-jmii.com](http://www.e-jmii.com)

## Correspondence

# Fatal myositis, rhabdomyolysis and compartment syndrome after ChAdOx1 nCoV-19 vaccination



## KEYWORDS

COVID-19;  
Vaccine;  
ChAdOx1 nCoV-19;  
Rhabdomyolysis;  
Compartment syndrome

Dear Editor,

During the COVID-19 surge, vaccination is a key strategy to protect vulnerable populations.<sup>1</sup> As vaccine rollouts extend to less well-studied populations, novel descriptions of rare but important adverse events have emerged. Here, we present a case of fatal rhabdomyolysis and compartment syndrome after ChAdOx1-nCoV-19 vaccination.

A 44-year-old previously healthy man developed generalized myalgia after his second dose of the adenoviral-based vaccine. He presented to ER with progressive weakness and brown urine two weeks later. On admission, his blood tests showed markedly elevated creatinine, creatine kinase, and severe metabolic acidosis. His bilateral forearm and gastrocnemius muscles were tense, tender and his skin was mottled. Computed tomography revealed bilateral retroperitoneal fluid collection and swelling and edematous change of his psoas muscles (Fig. 1a).

The patient was promptly intubated and initiated on continuous venovenous hemofiltration because of severe metabolic acidosis and anuria. Emergent fasciotomy was performed over his four limbs to relieve pressure from acute compartment syndrome. Muscle biopsy revealed neutrophilic myositis and small-vessel vasculitis with fibrin thrombi and C4d deposition (Fig. 1b & c). The myositis panel was positive for anti-PM-Scl 100 autoantibodies. A

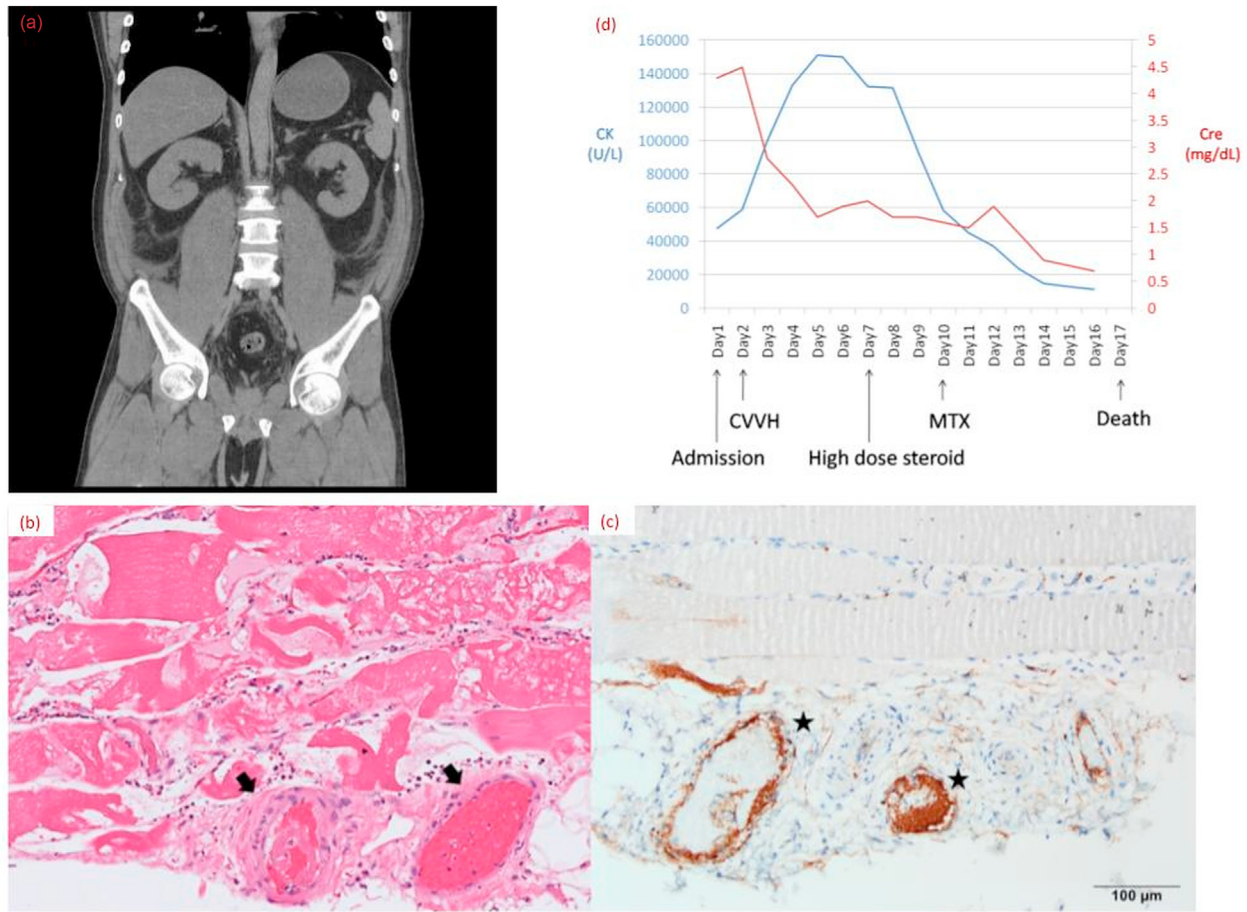
heliotrope rash later developed over his eyelids. Dermatomyositis superimposed with rhabdomyolysis was impressed, and methylprednisolone (0.6 mg/kg/day) was given, followed by a pulsed dose of cyclophosphamide (3.6 mg/kg/day). In response to steroid therapy on day 7, his creatine kinase immediately peaked at 151058 U/L and declined rapidly thereafter (Fig. 1d). However, the limb wounds during 8-hourly wet dressing change became infected. Initial blood cultures on admission and on day 3 did not yield any pathogen. On day 5 of admission, his open fasciotomy wounds became contaminated with carbapenem-resistant *Acinetobacter baumannii* (CRAB) and despite maximal support and appropriate antibiotics, the patient died of CRAB sepsis and multiorgan failure on day 17.

All published reports of post-COVID-19 vaccination rhabdomyolysis, comprising five men and three women, are listed in Table 1. Two required dialysis, one died of multi-organ failure; both were elderly women who presented after mRNA COVID-19 vaccines. Four published cases of post-COVID-19 vaccination myositis have been reported from India following ChAdOx1-nCoV-19 vaccination.<sup>2,3</sup> One was a 46-year-old woman who was notable for a myositis profile positive for anti-Jo-1 and anti-Ro-52 autoantibodies who also developed rhabdomyolysis after the 2nd ChAdOx1-nCoV-19 dose.<sup>3</sup> All four patients with immune-mediated myositis received steroids ± mycophenolate mofetil and survived, despite one episode of pneumocystosis.

Our case is the first fatality to be reported among ethnic-Chinese and in a man without prior associations of advanced age, statin use, strenuous exercise, or myopathy. A proposed mechanism for post-vaccination rhabdomyolysis is an exaggerated immune response, in a predisposed individual, to previously circulating self-antigens or to released muscle-specific antigens following myonecrosis. Post-vaccination myositis, like COVID-19 associated myocarditis, may be increasingly observed because of the

<https://doi.org/10.1016/j.jmii.2022.04.003>

1684-1182/Copyright © 2022, Taiwan Society of Microbiology. Published by Elsevier Taiwan LLC. This is an open access article under the CC BY-NC-ND license (<http://creativecommons.org/licenses/by-nc-nd/4.0/>).



**Figure 1.** (a) Computed tomography (CT) without contrast of his abdomen, pelvis showed bilateral retroperitoneal fluid collection and swelling and edematous change of his bilateral psoas muscles. (b) Hematoxylin-eosin stain of muscle showed focal vasculitis (arrows) with intravascular fibrin thrombi. The myositis was characterized by endomysial and perimysial neutrophilic and lymphocytic infiltrates, along with focal necrosis of the muscle. (c) Immunohistochemical stain of muscle against C4d revealed intravascular immune complex deposition along the endothelium (stars). (d) Clinical course showing serum creatine kinase (CK) and serum creatinine (Cre) in relation to interventions. Abbreviations used: CVVH = continuous venovenous hemofiltration, MTX = methotrexate, CP = cyclophosphamide.

**Table 1** Published cases of rhabdomyolysis associated with COVID-19 vaccinations.

Author, Year Country	Vaccine	Age, Sex	Peak CK Level	Severity	Possible associated factors
1. Tan et al., 2021 UK	ChAdOx1 nCoV-19 (AstraZeneca)	27, M	250,000 U/L	Mild	Known CPT2 deficiency
2. Mack et al., 2021 USA	mRNA-1273 (Moderna)	80, M	6546 U/L	Mild	COVID-19 infection 3 months ago
3. Nassar et al., 2021 USA	BNT161b2 mRNA (Pfizer/BioNTech)	21, M	>22,000 U/L	Mild	Social marijuana
4. Faissner et al., 2021 Germany	mRNA-1273 (Moderna)	28, F	17,959 U/L	Mild	—
5. Gelbenegger et al., 2021 Austria	ChAdOx1 nCoV-19 (AstraZeneca)	19, M	44,180 U/L	Mild	Avid swimmer
6. Elias et al., 2021 Portugal	BNT161b2 mRNA (Pfizer/BioNTech)	81, M	17,000 U/L	Mild	—
7. Ajmera et al., 2021 USA	mRNA-1273 (Moderna)	85, F	>14,000 U/L	Fatal	Rosuvastatin use
8. Hakroush et al., 2021 Germany	BNT161b2 mRNA (Pfizer/BioNTech)	79, F	14,243 U/L	Severe	ANCA
9. Present report, 2021 Taiwan	ChAd-Ox1 Adenovirus-based (AstraZeneca)	44, M	151058 U/L	Fatal	Anti-PM Scl 100

high antigenic similarity between the SARS-CoV-2 spike protein and human proteins.<sup>4</sup>

In conclusion, we present a man in his prime who developed fulminant myositis, rhabdomyolysis, and renal failure after ChAdOx1-nCoV-19 vaccination. More awareness of this potential complication may ameliorate outcomes.

## References

1. Huang JH, Chang HT, Liao CH, Chiu KM. Rapid response of a medical center upon the surge of COVID-19 epidemic in Taiwan. *J Microbiol Immunol Infect* 2022;**55**:1–5.
2. Maramattom BV, Philips G, Thomas J, Santhamma SGN. Inflammatory myositis after ChAdOx1 vaccination. *Lancet Rheumatol* 2021;**3**:e747–9.
3. Gupta K, Sharma GS, Kumar A. COVID-19 vaccination-associated anti-Jo-1 syndrome. *Reumatologia* 2021;**59**:420–2.
4. Murphy WJ, Longo DL. A possible role for anti-idiotypic Antibodies in SARS-CoV-2 infection and vaccination. *N Engl J Med* 2022;**386**:394–6.

Szu-Ting Huang

*Division of Infectious Diseases, Department of Medicine,  
National Taiwan University Hospital and National Taiwan  
University College of Medicine, Taipei, Taiwan*

Tai-Ju Lee

*Division of Allergy, Immunology and Rheumatology,  
Department of Medicine, National Taiwan University  
Hospital, Taipei, Taiwan*

Kai-Hsiang Chen

Hsin-Yun Sun

*Division of Infectious Diseases, Department of Medicine,  
National Taiwan University Hospital and National Taiwan  
University College of Medicine, Taipei, Taiwan*

Wei-Ting Chen

*Department of Emergency Medicine, National Taiwan  
University Hospital and National Taiwan University College  
of Medicine, Taipei, Taiwan*

Song-Chou Hsieh

*Division of Allergy, Immunology and Rheumatology,  
Department of Medicine, National Taiwan University  
Hospital, Taipei, Taiwan*

Aristine Cheng\*

Yee-Chun Chen

*Division of Infectious Diseases, Department of Medicine,  
National Taiwan University Hospital and National Taiwan  
University College of Medicine, Taipei, Taiwan*

\*Corresponding author. Division of Infectious Diseases,  
Department of Medicine, National Taiwan University Hos-  
pital and National Taiwan University College of Medicine,  
No.7, Zhongshan S. Rd. Zhongzheng Dist., Taipei City,  
10002, Taiwan. Fax: +886 2 23971412.

E-mail address: [aristine@hotmail.com](mailto:aristine@hotmail.com) (A. Cheng)

4 February 2022

Available online 25 April 2022