

Available online at www.sciencedirect.com

ScienceDirect

journal homepage: www.e-jmii.com

Correspondence

Supraglottitis as the sole manifestation of COVID-19 in a patient who received two doses of mRNA vaccine



KEYWORDS

Supraglottitis;
Epiglottitis;
COVID-19;
SARS-CoV-2;
Vaccination;
Case report

Dear Editor,

A 50-year-old male presented to the emergency department with fever, sore throat, and odynophagia for a day. Past medical history was significant for hypertension, diabetes (hemoglobin A1c of 8.1%), morbid obesity (body mass index of 44.7 kg/m²), obstructive sleep apnea and surgical history of childhood tonsillectomy. He had received two-dose series of mRNA-1273 (Moderna) vaccine eight months prior to presentation. His temperature was elevated at 39.2 °C and the oxygen saturation was at 96% on ambient air. On physical examination, he had a non-toxic appearance and his breathing was non-labored. Nasopharyngeal multiplex polymerase chain reaction test for respiratory pathogens was only positive for severe acute respiratory syndrome coronavirus 2 (SARS-CoV-2). Bedside flexible fiberoptic laryngoscope revealed minimally edematous epiglottis, markedly edematous arytenoids and aryepiglottic folds, and mobile true vocal cords (Fig. 1A and B). Mixture of saliva and pus was observed in the supraglottis. Computed tomography (CT) neck with intravenous (IV) contrast showed a homogeneous low-density soft tissue thickening involving the supraglottis and there was thickening of the anterior and posterior commissure with narrowing of the laryngeal airway (Fig. 1C and D). The chest radiograph showed clear lung

fields. The patient was started on IV dexamethasone and ampicillin/sulbactam for supraglottitis and IV remdesivir for coronavirus disease 2019 (COVID-19), both of which were discontinued at discharge. The fever and sore throat subsided within 48 h and he was able to tolerate full solid food. Throat culture for group A *Streptococcus* and blood culture had no growth. He was discharged home on day 3 of admission with oral amoxicillin/clavulanate to complete a 7-day course of antibiotics to cover empirically for any possible bacterial superinfection. Telephone follow-up at one week confirmed complete resolution of symptoms.

To our best knowledge, this is the first case of supraglottitis secondary to SARS-CoV-2 in a patient who completed two-dose series of mRNA vaccine.

In view of the paucity of literature on epiglottitis/supraglottitis associated with COVID-19, a universal definition of such diseases cannot be established and the causative relationship is difficult to determine. However, there were ten reported cases of epiglottitis/supraglottitis related to COVID-19 (Supplementary Table S1).^{1–10} Six of them had acute epiglottitis at the time of COVID-19 diagnosis (one required cricothyroidotomy, one required intubation, and the rest only required medical management).^{1–3,5,9,10} Four cases had delayed onset of epiglottitis approximately three weeks after the initial COVID-19 diagnosis, that all required emergent airway placements.^{4,6–8} These cases possibly represented bacterial superinfection on the inflamed epiglottis after COVID-19. All ten cases received antibiotics, and all but two were treated with steroids as well. There was no mortality associated with those cases.

None of the case reports outlined in the reference had documented history of vaccination against SARS-CoV-2 and more than half required advanced airway management due to epiglottitis. Our patient had positive anti-spike antibody from the vaccine and the absence of anti-nucleocapsid

<https://doi.org/10.1016/j.jmii.2022.04.010>

1684-1182/Copyright © 2022, Taiwan Society of Microbiology. Published by Elsevier Taiwan LLC. This is an open access article under the CC BY-NC-ND license (<http://creativecommons.org/licenses/by-nc-nd/4.0/>).

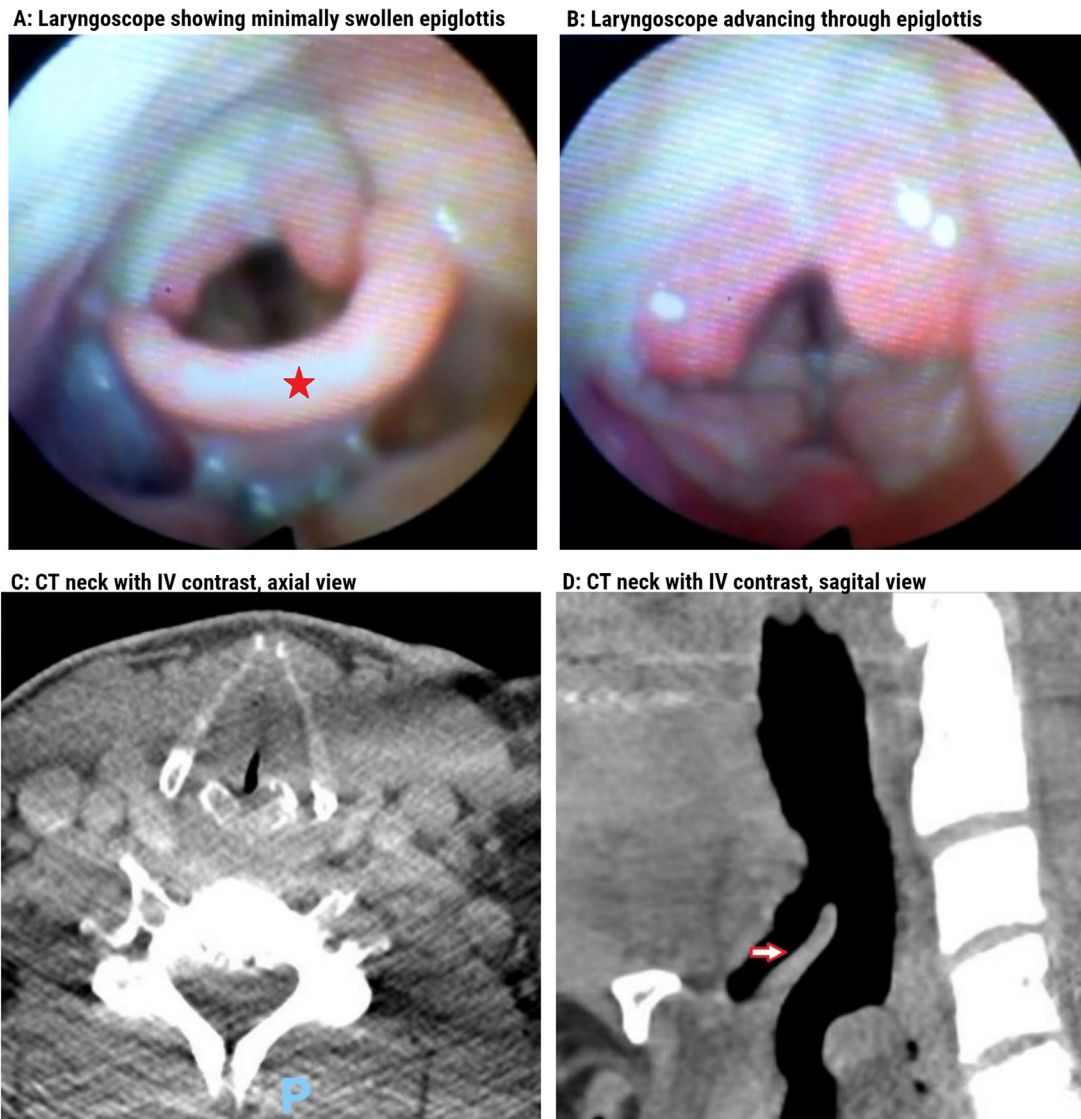


Figure 1. Supraglottitis due to COVID-19. **A.** Bedside flexible fiberoptic laryngoscope showed minimally swollen epiglottis (asterisk). **B.** Soft tissue swelling can be seen in the supraglottic areas after the laryngoscope advancing through epiglottis. **C.** Computed tomography (CT) neck axial view showed homogeneous low-density soft tissue thickening involving the aryepiglottic folds, false cords and glottis bilaterally and there was thickening of the anterior and posterior commissure with narrowing of the laryngeal airway. **D.** Sagittal view of the CT neck showed mild edema of the epiglottis (arrow).

antibody suggested a newly acquired SARS-CoV-2 infection, which implied supraglottitis was his first manifestation of COVID-19.

Epiglottitis is not a common presentation of COVID-19 but it should be recognized by clinicians. Whether or not the vaccination had halted the progression of COVID-19 into the lower respiratory tract was not clear in this case. However, given the ongoing COVID-19 pandemic and increasing prevalence of the Omicron variant, which may have more upper respiratory tract involvements; further studies to characterize epiglottitis and COVID-19 are necessary. SARS-CoV-2 should be listed as one of the potential causes of epiglottitis/supraglottitis.

Declaration of competing interest

None.

Acknowledgments

None.

Appendix A. Supplementary data

Supplementary data to this article can be found online at <https://doi.org/10.1016/j.jmii.2022.04.010>.

References

1. Fondaw A, Arshad M, Batool S, Robinson B, Patel T. COVID-19 infection presenting with acute epiglottitis. *J Surg Case Rep* 2020;2020(9):rjaa280.
2. Nadiger M, Ness-Cochinwala M, Sanchez-Vegas C, Sendi P, Ho B, Totapally BR, et al. Pediatric COVID-19 presenting as supraglottitis with vocal cord hypomobility. *SAGE Open Medical Case Reports* 2021;9. 2050313X21989465.
3. Alqaisi S, Almomani A, Alwakeel M, Akbik B. 239: epiglottitis case report: a unique presentation of COVID-19 infection. *Crit Care Med* 2021;49(1):105.
4. Emberey J, Velala SS, Marshall B, Hassan A, Meghjee SP, Malik MJ, et al. Acute epiglottitis due to COVID-19 infection. *European J Case Reports Internal Med* 2021;8(3).
5. Smith C, Mobarakai O, Sahra S, Twito J, Mobarakai N. Case report: epiglottitis in the setting of COVID-19. *IDCases* 2021;24:e01116.
6. Renner A, Lamminmäki S, Ilmarinen T, Khawaja T, Paajanen J. Acute epiglottitis after COVID-19 infection. *Clinical Case Reports* 2021;9(7).
7. Cordial P, Le T, Neuenschwander J. Acute epiglottitis in a COVID-19 positive patient. *Am J Emerg Med* 2022;51:427. e421–2.
8. Min S, Sorin C, Carino G. Patient with recent COVID-19 infection presenting with acute upper airway obstruction. *Chest* 2021;160(4):A375.
9. Gezer B, Karabagli H, Sahinoglu M, Karagoz AS. Acute epiglottitis is a rare clinical presentation of coronavirus disease 2019: a case report. *Infectious Diseases* 2021:1–3.
10. Iwamoto S, Sato MP, Hoshi Y, Otsuki N, Doi K. COVID-19 presenting as acute epiglottitis: a case report and literature review. *Auris Nasus Larynx* 2021. In press.

Kai-Ming Chang*

Marcia E. Epstein

Division of Infectious Diseases, Department of Medicine,
Donald and Barbara Zucker School of Medicine at Hofstra/
Northwell Health, Manhasset, NY, USA

William A. Kennedy III

Department of Otolaryngology - Head and Neck Surgery,
Donald and Barbara Zucker School of Medicine at Hofstra/
Northwell Health, NY, USA

Negin Niknam

Division of Infectious Diseases, Department of Medicine,
Donald and Barbara Zucker School of Medicine at Hofstra/
Northwell Health, Manhasset, NY, USA

*Corresponding author. 400 Community Drive, Manhasset,
NY 11030, USA. Fax: +1 516-562-2626.

E-mail address: kaimingchangmd@gmail.com (K.-M. Chang)

1 March 2022

Available online 28 April 2022