

## Primary Mediastinal Gray Zone Lymphoma in an Immunocompetent Young Adult

**Aisyah Wirdah<sup>1\*</sup>, Yenny Dian Andayani<sup>2</sup>, Mediarty Syahrir<sup>2</sup>, Norman Djamaludin<sup>2</sup>, Krisna Murti<sup>3</sup>, Ali Zainal Abidin<sup>1</sup>**

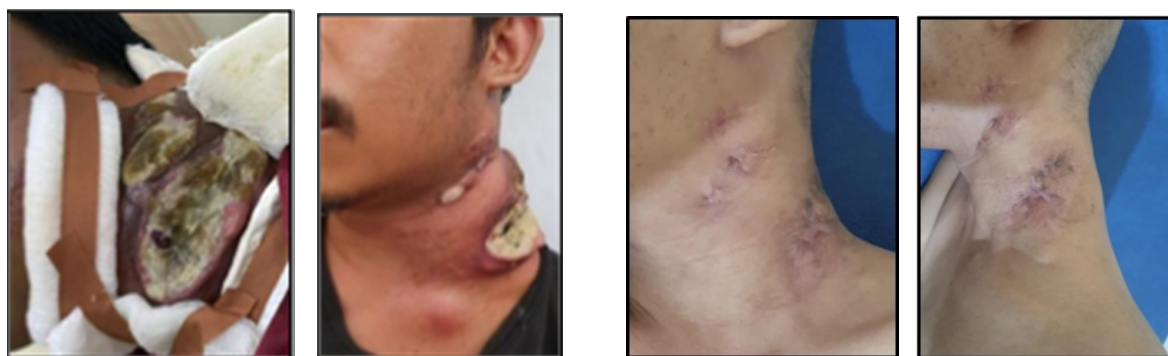<sup>1</sup>Department of Internal Medicine, Faculty of Medicine Universitas Sriwijaya - Mohammad Hoesin General Hospital, Palembang, Indonesia.

<sup>2</sup>Division of Medical Hematology Oncology, Department of Internal Medicine, Faculty of Medicine, Universitas Sriwijaya - Mohammad Hoesin General Hospital, Palembang, Indonesia.

<sup>3</sup>Pathology Anatomy Division, Faculty of Medicine, Universitas Sriwijaya - Mohammad Hoesin General Hospital, Palembang, Indonesia.

**\*Corresponding Author:**

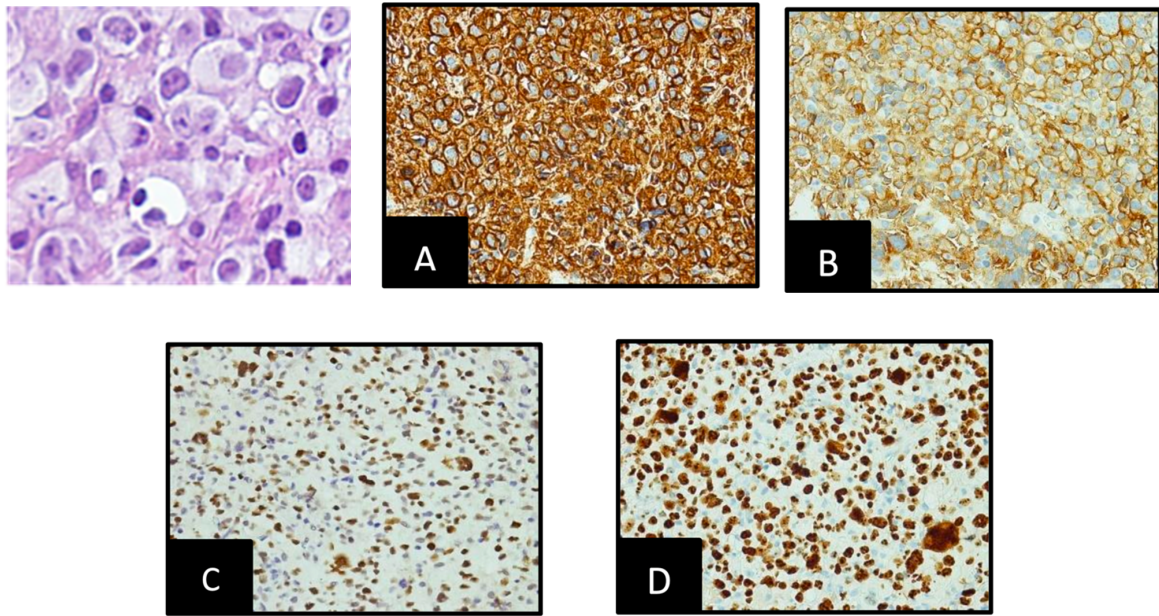
Aisyah Wirdah, MD. Department of Internal Medicine, Faculty of Medicine Universitas Sriwijaya - Mohammad Hoesin General Hospital. Jl. Dr. Muhammad Ali, Sekip Jaya, Kota Palembang, Sumatera Selatan 30114, Indonesia. Email: aisyahwirdah297@gmail.com; aisyahwirdah@fk.unsri.ac.id.



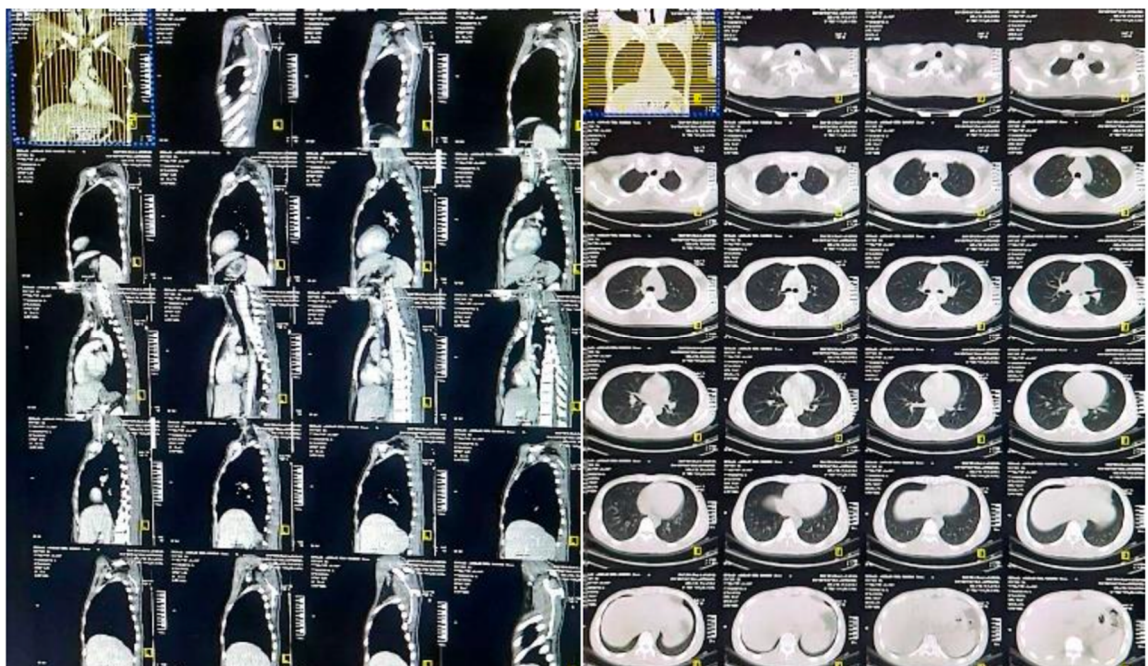
**Figure 1.** An open wound and a bulge on the left side of the neck before and after treatment.

Primary Mediastinal Gray Zone Lymphoma (PMGZL) is a rare non-Hodgkin lymphoma occurring predominantly in young men.<sup>1</sup> MGZL exhibits pathologic characteristics that are intermediate between those of nodular-sclerosis classical Hodgkin lymphoma (NSCHL) and primary mediastinal large B-cell lymphoma (PMBL), and it is characteristically CD30+. PMGZL is an aggressive large B cell lymphoma originating in the mediastinum.<sup>2</sup> The diagnosis of PMBCL mainly depends on the pathological features, imaging examination and clinical features. The case may lead to diagnostic challenge and/or poor prognosis. Here, we report a case of Primary Mediastinal Gray Zone Lymphoma in an immunocompetent patient who responded to chemotherapy.

A 28-year-old man presented to our hospital with a rapidly growing nodule on the left side of the neck and bilateral axillae, accompanied by history of weight loss. He has been experiencing a nodule around the left side of his neck since two years ago and had done FNAC and diagnosed as extrapulmonary tuberculosis (EPTB). On examination of the left side of the neck revealed; mobile mass 9 cm x 7 cm in size, preauricular lymph node 3 cm x 3 cm in size, supraclavicular lymph node 1 cm x 0.5 cm in size, as well as bilateral mobile axillary lymph node, each with the size of 4 cm x 4 cm x 2 cm. Other physical examination results were unremarkable. Laboratory test results suggested haemoglobin 10.4 g/dL, WBC 14250/ mm<sup>3</sup>, ESR 78 mm/hr, D-dimer 1.81 mcg/mL, fibrinogen 452 mg/dl.



**Figure 2.** Pathological Anatomy. Hematoxylin & Eosin, A). CD 20 positive. B). CD 30 positive. C). Ki-67 + >50%, D). CD79a positive.



**Figure 3.** CT scan of the thorax with contrast.

Anti-HIV, HBsAg and anti-HCV results were non-reactive. Chest CT scan revealed enlarged anterior mediastinal lymph node with diameter of 2.9 cm, right paratracheal lymph nodes with diameter of 1.2 cm and 1.1 cm, right perihilar lymph node with diameter of 1.3 cm, as well as left perihilar lymph node with diameter of 0.9 cm. We also detected hypodense lesion of

the spleen with the size of 2.3 cm x 1.6 cm. The patient underwent a biopsy with pathology biopsy and immunohistochemistry (IHC), the result of which showed CD 20+, CD 3-, CD 30+ CD79a +, MUM1 +, Ki67 80-90% +, CD15-, BCL6+ and BCL 2+.

For this patient, we started an R-CHOP regimen (Rituximab 375 mg/m<sup>2</sup> (d1), Cyclophopamid

750 mg/m<sup>2</sup> (d1), Doxorubicin 50 mg/m<sup>2</sup> (d1), Vincristine 1.2 mg/m<sup>2</sup> (d1) and 1 Prednisone 100 mg (d1-d5). We presented the patient with PMGZL has achieved a complete response to R-CHOP chemotherapy regimen.

## REFERENCES

1. Hodgkin lymphoma guidelines: Diagnosis, staging, risk stratification [Internet]. Emedicine; 2016. Accessed on March 5, 2017. Available on: <http://emedicine.medscape.com/article/2500018-overview#showall>.
2. Portnow LJ, Baehring J. B-cell lymphoma. NCCN clinical practice guidelines in oncology. Version 2. 2023.