

# Efficacy of Probiotic on Duodenal TNF- $\alpha$ Expression and the Histological Findings in the Liver and Lung in Animal Model Canine Coronavirus

Iwan Sahrial Hamid<sup>1,\*</sup>, Juni Ekowati<sup>2</sup>, Rondius Solfaine<sup>3</sup>, Shekhar Chhetri<sup>4</sup>, Muhammad Thohawi Elziyad Purnama<sup>5</sup>

Iwan Sahrial Hamid<sup>1,\*</sup>, Juni Ekowati<sup>2</sup>,  
Rondius Solfaine<sup>3</sup>, Shekhar Chhetri<sup>4</sup>,  
Muhammad Thohawi Elziyad Purnama<sup>5</sup>

<sup>1</sup>Department of Veterinary Science, Faculty of Veterinary Medicine, Universitas Airlangga, Surabaya, 60115, INDONESIA.

<sup>2</sup>Department of Pharmaceutical Science, Faculty of Pharmacy, Universitas Airlangga, Surabaya, 60115, INDONESIA.

<sup>3</sup>Laboratory of Pathology, Faculty of Veterinary Medicine, Universitas Wijaya Kusuma Surabaya, Surabaya, 60225, INDONESIA.

<sup>4</sup>Department of Animal Science, College of Natural Resources, Royal University of Bhutan, Lobesa, Punakha, 13001, BHUTAN.

<sup>5</sup>Department of Veterinary Anatomy, Faculty of Veterinary Medicine, Universitas Airlangga, Surabaya, 60115, INDONESIA.

## Correspondence

Iwan Sahrial Hamid

Department of Veterinary Science, Faculty of Veterinary Medicine, Universitas Airlangga, Surabaya, 60115, INDONESIA.

E-mail: iwan-s-h@fkh.unair.ac.id

## History

- Submission Date: 17-03-2022;
- Review completed: 08-04-2022;
- Accepted Date: 13-04-2022.

DOI : 10.5530/pj.2022.14.76

Article Available online

http://www.phcogj.com/v14/i3

## Copyright

© 2022 Phcogj.Com. This is an open-access article distributed under the terms of the Creative Commons Attribution 4.0 International license.

## ABSTRACT

Currently, Canine coronavirus (CCoV) is an enteric pathogen of the Alphacoronavirus-1 species that causes mild to severe diarrhea in puppies. The pathogenesis of this infection will cause severe lymphopenia and lead to death in puppies. This study aimed to determine the administration of probiotics on TNF- $\alpha$  expression, histological findings of the liver and lung in mice infected with CCoV. A total of 28 mice were randomly assigned into seven treatment groups, i.e. (C-) placebo; (C+) active CCoV vaccine induction; (T1) CCoV + Isopronosin; (T2) CCoV + Lactobacillus acidophilus probiotic; (T3) CCoV + Lactobacillus Acidophilus and Bifidobacterium probiotics; (T4) CCoV + colostrum fermentation probiotic; (T5) CCoV + ginger, turmeric and ginger probiotics. Thereafter, the expression of TNF- $\alpha$  in the duodenum was stained using immunohistochemistry, liver and lung were stained using hematoxylin eosin. The data were analyzed using the ANOVA test followed by the Tukey test with a significance level ( $p < 0.05$ ). TNF- $\alpha$  expression on T4 and T5 decreased significantly ( $p < 0.05$ ) compared to C+, T1, T2 and T3. Histologic findings of the liver in the C- and T4 groups showed normal features in the central vein. On the other hand, glycogen accumulation was found in hepatocyte cells, hemorrhage with sinusoid dilation, lymphocyte infiltration in centro lobular area in group C+. Lung histology showed normal features of sinusoids and alveolar septa in groups C- and T4. Meanwhile, intra-alveolar hemorrhage was found with neutrophil cell infiltration and fibrin plasma accumulation in group C+. In conclusion, colostrum fermentation probiotics can reduce TNF- $\alpha$  expression in the duodenum and improve the liver and lung physiology in mice infected with CCoV.

**Key words:** Biodiversity, Canine coronavirus, Liver, Lung, Probiotic, TNF- $\alpha$ .

## INTRODUCTION

Canine coronavirus (CCoV) is an enteric pathogen, currently included in the Alphacoronavirus-1 species which causes mild to severe diarrhea in puppies, whereas infection is fatal if there is secondary infection by other pathogens. In pathogenesis, this infection will cause severe and prolonged lymphopenia due to a decrease in CD4 cells and lead to death in puppies.<sup>1</sup>

Probiotics are beneficial live microorganisms that provide benefits to the body. Lactobacillus species are probiotics that have been studied, with physiological and immunological effects such as regulation of T (NK) cell activity, preventing influenza virus infection in experimental animals and increasing levels of interferon- $\gamma$  (IFN- $\gamma$ ).<sup>2</sup> *L. acidophilus* can upregulate anti-viral genes through the Toll-like receptor pathway, is able to resist bile acids, improve the physiological environment of the intestine and prevent obesity.<sup>3</sup> Probiotics as dietary supplements containing live microbials have beneficial effects on host animals by increasing the balance of microflora in the digestive tract.<sup>4</sup> The bacterial groups in question are *L. acidophilus*, *B. bifidum*, *B. pseudolongum* and *S. faecalis*. These bacteria are lactic acid bacteria which have the ability to produce lactase to digest lactose and also stimulate proteolytic and cellulolytic enzymes, so that the final result is an increase in nutrient uptake.<sup>5</sup>

An experimental study shows that probiotics can be used to control microorganisms that contaminate food, selectively microorganisms in probiotics can reduce idiopathic diarrhea in turkeys, also reduce salmonella colonies in turkeys and broilers.<sup>6</sup> Lactic acid microbes are a group of bacteria that do not form spores, are gram-positive, producing lactic acid as the end product, which are generally good non-pathogenic bacteria. These lactic acid bacteria are known as Probiotics.<sup>7</sup> Organisms that are classified as lactic acid bacteria are Lactobacillus, Pediococcus, Bifidobacterium and Streptococcus. The most widely used probiotics belong to the Lactobacillus group such as *L. casei*, *L. acidophilus*, *L. rhamnosus*<sup>8</sup> and the Bifidobacterium group such as *B. bifidum*, *B. longum*, *B. breve*.<sup>9</sup> This study aimed to determine the administration of probiotics on duodenal TNF- $\alpha$  expression, histological findings of the liver and lung in mice infected with CCoV.

## MATERIALS AND METHODS

### Ethical approval

This study was approved by the Animal Ethics and Care Committee Faculty of Veterinary Medicine, Universitas Airlangga (No: 2.KE.071.05.2020). This ethical approval conducted to avoid animal abuse and distress.

### Experimental design

A total of 28 mice were randomly assigned into seven treatment groups, i.e. (C-) placebo; (C+)

**Cite this article:** Hamid IS, Ekowati J, Solfaine R, Chhetri S, Purnama MTE. Efficacy of Probiotic on Duodenal TNF- $\alpha$  Expression and the Histological Findings in the Liver and Lung in Animal Model Canine Coronavirus. Pharmacogn J. 2022;14(3): 591-597.

active CCoV vaccine induction; (T1) CCoV + Isopronosin; (T2) CCoV + Lactobacillus acidophilus probiotic; (T3) CCoV + Lactobacillus Acidophilus and Bifidobacterium probiotics; (T4) CCoV + colostrum fermentation probiotic; (T5) CCoV + ginger, turmeric and ginger probiotics. Mice were adapted to feed pellets and drink *ad libitum*. After being adapted for a week, all treatment groups were injected subcutaneously with CCoV vaccines (Vanguard Plus 5<sup>+</sup>, Zoetis) at a dose of 60 mg/kg BW<sup>1</sup> except for group C-. At the end of the treatment, all cervical mice were decapitated and then duodenal organ dissection for immunohistochemical (IHC) staining, liver and lung for hematoxylin eosin (HE) staining.

### IHC and HE staining

The duodenum was stored in formaldehyde 15% for 48 h. Furthermore, alcohol was used as a dehydration agent with concentration of 70%, 80% and 96%. Xylol was used for clearing process and continued making paraffin block with 60°C of the temperature. The skin tissue that has received paraffin blocks then sliced using a microtome machine and then transferred into a water bath before being placed on a glass object. Immunohistochemistry staining was used primary antibody TNF- $\alpha$  anti-mice for 1 h in 27°C. The dilution was given 10  $\mu$ l for TNF- $\alpha$ . Then, the specimen washed in phosphate buffered saline (PBS) with a pH of 7.4 for 3 times every 5 min. The next preparations were added streptavidin-horseradish peroxidase for 60 min in 27°C and washed in PBS with pH 7.4. Then, the specimens were added chromogen 3,3-Diaminobenzidine tetrahydrochloride for 20 min and washed with aquadest for 5 min.<sup>10</sup>

HE staining was conducted according to routine protocols.<sup>11</sup> Briefly, after deparaffinization and rehydration, 5  $\mu$ m longitudinal sections were stained with hematoxylin solution for 5 min followed by 5 dips in 1% acid ethanol (1% HCl in 70% ethanol) and then rinsed in distilled water. Then the sections were stained with eosin solution for 3 min and followed by dehydration with graded alcohol and clearing in xylene. The mounted slides were then examined and photographed using a Nikon E200 trinocular microscope (Tokyo, Japan).

### Statistical analysis

Data were expressed as mean  $\pm$  standard deviation (SD) and analyzed statistically using ANOVA test followed by Tukey test for comparison between groups. Differences were considered significant at  $p < 0.05$ . The analysis performed using SPSS v25 (IBM, USA).

## RESULTS AND DISCUSSION

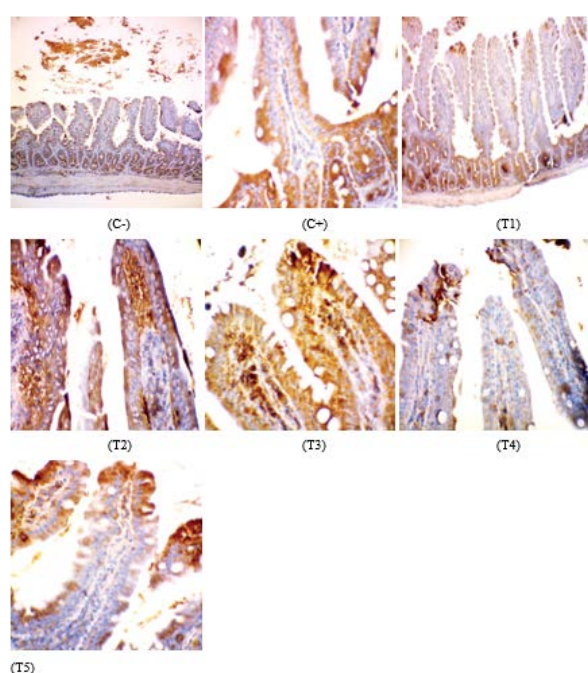
The alleviation in duodenal TNF- $\alpha$  expression was significant ( $p < 0.05$ ) in the C- ( $5.92 \pm 0.92^{a,***}$ ), T4 ( $9.91 \pm 2.13^{b,***}$ ) and T5 ( $11.08 \pm 0.99^{ab,***}$ ) groups, respectively. Meanwhile, TNF- $\alpha$  expression was not significant ( $p > 0.05$ ) between the C+ ( $21.08 \pm 1.17^e$ ) and T1 groups ( $17.75 \pm 1.13^{de}$ ) (Table 1).

In this study, TNF- $\alpha$  expression was revealed by the presence of brown on duodenal IHC stain (Figure 1). Streptokinase forms an antigen complex that is recognized by antibodies and then attaches to the duodenal cylindrical epithelium so that the antigen becomes an indicator of the inflammatory process. Furthermore, it is recognized by the Presenting Cell (APC) antigen in the form of macrophages so that the antigen is phagocytosed into small pieces which will bind to MHC (Major Histocompatibility Complex). The antigen is carried to the surface of the cytoplasm which then binds to the duodenal cylindrical

**Table 1: Expression of TNF- $\alpha$  on duodenal epithelial cells at the end of the study.**

Treatment	Expression of TNF- $\alpha$
C-	$5.92 \pm 0.92^{a,***}$
C+	$21.08 \pm 1.17^e$
T1	$17.75 \pm 1.13^{de}$
T2	$15.58 \pm 2.69^{d,**}$
T3	$14.16 \pm 1.83^{cd,***}$
T4	$9.91 \pm 2.13^{b,***}$
T5	$11.08 \pm 0.99^{ab,***}$

Values are expressed in mean  $\pm$  SD ( $n = 4$  animals for each seven groups). Values are represented statistically <sup>a,b,c,d,e</sup> when compared with C- group value; \* $p < 0.05$ , \*\* $p < 0.01$ , \*\*\* $p < 0.001$ , when compared with C+ group value.



**Figure 1:** (C- and T4) there was no TNF- $\alpha$  expression in the mucosal and submucosal layers; (C+ and T1) TNF- $\alpha$  expression in the epithelium and parietal layers; (T2) TNF- $\alpha$  expression in the lamina propria; (T3) TNF- $\alpha$  expression in the epithelium and lamina propria; (T5) TNF- $\alpha$  expression in the epithelium and intestinal crypt.

epithelial cells to produce TNF- $\alpha$ .<sup>12</sup> TNF- $\alpha$  expression appeared to be increased compared to the C-, T4 and T5 groups. The percentage above shows an increase in TNF- $\alpha$  expression due to the induction of streptokinase which activates macrophages to produce cytokines that stimulate inflammation in duodenal epithelial cells. Secretion of cytokines causes the aggregation and activation of neutrophils as well as the release of proteolytic enzymes in cell damage. Cytokines activate fibroblast tissue in the duodenal epithelium and increase the proliferation of the extracellular matrix.<sup>13</sup>

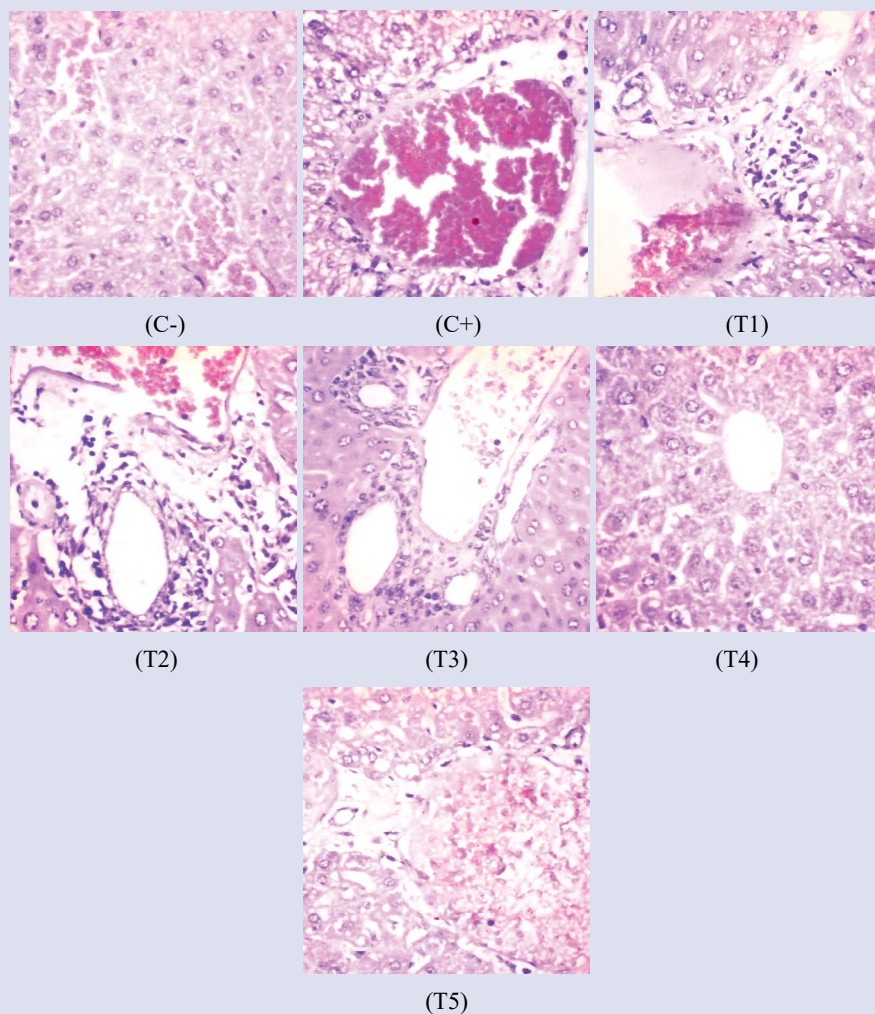
TNF- $\alpha$  mediates a variety of biological responses including inflammation, infection, injury and cell apoptosis.<sup>14</sup> The effect of TNF- $\alpha$  is initiated by cytokine binding to the receptor, which causes activation of a major transcription factor including nuclear factor kappa B (NF- $\kappa$ B). Such activation then induces genes involved in the inflammatory response.<sup>15</sup> In addition, TNF- $\alpha$  can also trigger apoptosis by binding to death receptors. TNF bonds with death receptors with apoptotic effects through caspase 8 or 10 activation.<sup>16</sup>

The formation of this DISC (Death Inducing Signaling Complex) results in activation of caspase-8 or -10, which then activates caspase-3 as the executor.<sup>17</sup> Cytokine-activated cells may produce and secrete the same cytokines as paracrine signaling or to enhance and stabilize signals in secreting cells *via* autocrine regulation.<sup>18</sup> The autocrine or

paracrine mechanism of TNF- $\alpha$  production involves several proteins, including NF- $\kappa$ B, I $\kappa$ B $\alpha$  and A20 inhibitors, IKK and IKKK kinase signaling carriers, TNF- $\alpha$  cytokines and TNFR1 receptors. TNF- $\alpha$  activates the NF- $\kappa$ B pathway in duodenal epithelial cells.<sup>19</sup> In addition to being produced by active macrophages, TNF- $\alpha$  is also produced by epithelial cells during degeneration.<sup>20</sup> In this case TNF- $\alpha$  can also be autocrine produced by target cells. By increasing the production of TNF- $\alpha$  by autocrine mechanism, it can exacerbate the effect of TNF- $\alpha$ .<sup>21</sup>

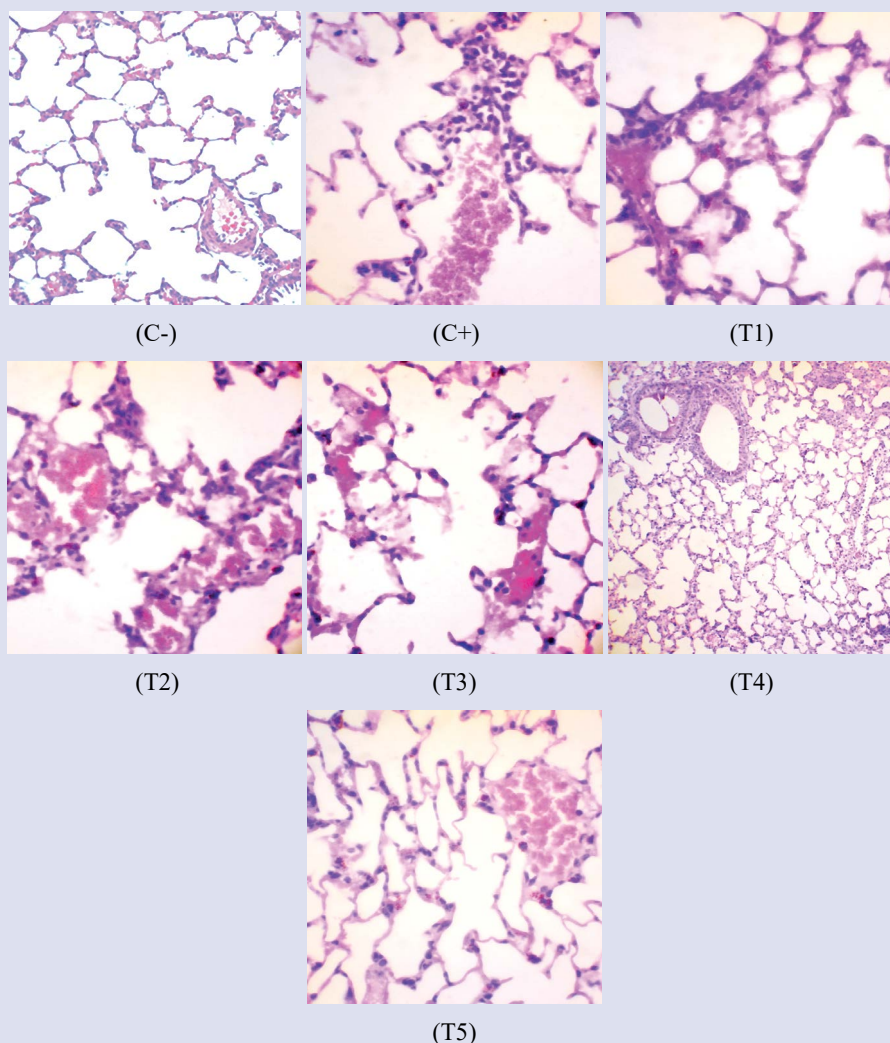
The results of the liver histology findings showed that there were changes, both degeneration and necrosis, as well as signs of toxicity or infection. There is hyperemia, and an indication of the presence of inflammatory cells in the form of leukocytosis is seen as if the mice were infected with infectious agents or induced by chemicals. These results indicate that there were pathological changes in the C+, T1, T2, T3 and T5 groups compared to the C- and T4 groups (Figure 2).

This is due to the role of probiotics which do not interfere with the work of the liver, so that it does not cause changes in its histological structure. Probiotics are beneficial living microorganisms that are taken orally into the animal's body. It is hoped that living microbes can have a positive effect on health by improving the properties of natural microbes that live in the animal's body so that it can restore the balance of the ratio between pathogenic and non-pathogenic bacteria in the digestive tract.<sup>22</sup>



**Figure 2:** (C-) Congestion and dilatation of sinusoids in the centrilobular area; (C+) Glycogen accumulation, lymphocyte infiltration and congestion in the portal vein area. There was necrosis in the centrilobular and periportal areas; (T1) Sinusoid dilatation with infiltration of neutrophil and necrotic cells at the portal triad; (T2) Proliferation in the portal vein, infiltration of lymphocytes and centrilobular necrotic cells; (T3) Lymphocyte infiltration, sinusoid dilation and proliferation of periportal areas; (T4) Normal liver; (T5) Periportal necrotic and hyaline accumulation in centro lobular followed by lymphocyte infiltration.





**Figure 3:** (C-) Normal lungs; (C+) Intra-alveolar hemorrhage with neutrophil cell infiltration and accumulation of plasma fibrin; (T1) Diffuse alveolar disorders, accumulation of hyaline tissue, intra-alveolar hemorrhage, neutrophil cell infiltration, alveolar septa hyperplasia; (T2) Mononuclear cell infiltration with alveolar epithelial desquamation and diffuse intra-alveolar hemorrhage; (T3) Hyaline accumulation with alveolar desquamation accompanied by hemorrhage and lymphocyte infiltration with fibrin clots in alveolar septa; (T4) Normal alveolar septa; (T5) Diffuse alveolar damage with plasma accumulation and intra-bronchial hemorrhage.

The absence of changes in liver histopathology is due to the nature of the work of the probiotics themselves which only survive and work in the digestive coating only and attach to intestinal cells, and do not participate in the blood circulation system. This is the first stage for colonization, and can further be modified for the host animal's immunization / immune system.<sup>23</sup> A number of probiotics have shown strong adherence to human intestinal cells such as *Lactobacillus casei*, *Lactobacillus acidophilus*, *Lactobacillus plantarum* and a large number of *Bifidobacteria*.<sup>24</sup> Probiotic strains of *Lactobacillus rhamnosus* HN001 (DR20™), *Lb. acidophilus* HN017 and *Bifidobacterium lactis* HN019 (DR10™) in Balb / c strain mice during an interval of 8 days at a dose of 1011 / rat / day, the results obtained were that probiotics did not cause effect of changes on the health condition of white mice.<sup>25</sup> Probiotic microorganisms are able to regulate several aspects of the host animal's immune system, by stimulating the formation of IgA in the intestinal mucosal lining. In addition, the ability of probiotic microbes to release metabolic products can reduce the development of pathogenic microbes in the digestive tract, a condition that can increase the immunity of host animals. The resulting metabolic compounds are antibiotics for pathogenic microbes, so that the disease caused by these pathogenic microbes will be reduced and can disappear or heal by itself. This will

provide benefits to the health of the host animal so that it is resistant to disease. The use of probiotics in livestock is reported to reduce urease activity, an enzyme that works to hydrolyze urea to ammonia, so that the formation of ammonia is reduced.<sup>26</sup>

Lungs of group C- showed normal findings. The T4 group was slightly different from the C-group by showing normal alveolar septa. Darker brown color and more black spots were found in the C+ group. The lungs of the control group without treatment were reddish white but in the negative exposure group mice had dark colored lungs and black spots on the lung surface (Figure 3). Dangerous infectious agents will envelop the lungs simultaneously which will affect the performance of the alveoli in the lungs. Alveolar performance changes are characterized by changes in the alveolar lumen width, alveolar membrane and alveolar relationships.<sup>27</sup>

From the treatment group, giving probiotics had the largest alveolar lumen width. This proves that this treatment group has the greatest effect in inhibiting the infectious agent that causes dilatation of the pulmonary alveoli.<sup>28</sup> The width of the alveoli is seen from the distance between the alveolar cell walls with each other. The wider the distance between the alveoli, the better the condition of the alveoli of the lungs

of mice.<sup>29</sup> The emergence of tumor nodules in the C+ group was due to the proliferation of excess epithelial cells from the alveolar membrane which caused the alveolar lumen to become narrow and irregular in shape due to cell rupture.<sup>30</sup> Infectious activity can be seen through the appearance of an increase in the number of epithelial cells in the bronchioles and alveoli septa and cell nuclei that appear irregular.<sup>31</sup> By administering probiotics the cell structure in the nodule is not too tight and cell proliferation can be inhibited, so that the higher the extract dose given, the more effective it is to inhibit the proliferation of nodule-forming cells.<sup>32</sup> The effectiveness of probiotics is due to the fact that their antioxidant properties work more effectively on the intestinal tissue, skin and lungs.<sup>33</sup>

## CONCLUSION

Colostrum fermentation probiotics can reduce TNF- $\alpha$  expression in the duodenum. Meanwhile, an improvisation on the liver and lung physiology also was revealed in the colostrum fermentation probiotics treatment group.

## AUTHORS' CONTRIBUTIONS

ISH supervised the study. JE and RS conducted the study. MTEP helped in the statistical analysis of the data. MTEP and SC helped in the preparation of tables, revised and submitted the manuscript. All authors read and approved the final manuscript.

## ACKNOWLEDGMENTS

The authors acknowledge the Institute of Research and Innovation, Universitas Airlangga and Faculty of Veterinary Medicine, Universitas Airlangga for providing fund support to carry out this study based on grant number 664/UN3.14/PT/2020.

## CONFLICTS OF INTEREST STATEMENT

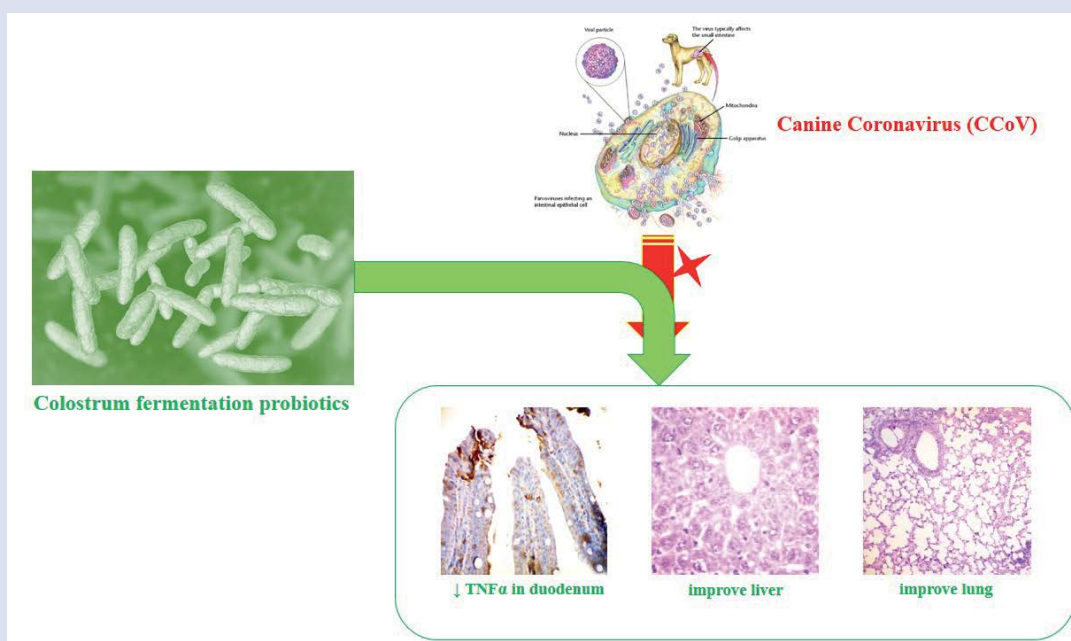
The authors declare that they have no competing interests.

## REFERENCES

1. Castro TX, Cássia NRD, Gonçalves LP, Costa EM, Marcello GC, Labarthe NV, et al. Clinical, hematological and biochemical findings in puppies with coronavirus and parvovirus enteritis. *Can Vet J*. 2013;54(9):885.
2. Prescott SL, Dunstan JA, Hale J, Breckler L, Lehmann H, Weston S, et al. Clinical effects of probiotics are associated with increased interferon- $\gamma$  responses in very young children with atopic dermatitis. *Clin Exp Allergy*. 2005;35(12):1557-1564.
3. Cerdó T, García-Santos JA, Bermúdez MG, Campoy C. The role of probiotics and prebiotics in the prevention and treatment of obesity. *Nutrients*. 2019;11(3):635.
4. Thomas LV. Probiotics—the journey continues. *Int J Dairy Technol*. 2016;69(4):469-480.
5. Borriello SP, Hammes WP, Holzapfel W, Marteau P, Schrezenmeier J, Vaara M, et al. Safety of probiotics that contain lactobacilli or bifidobacteria. *Clin Infect Dis*. 2003;36(6):775-780.
6. Forkus B, Ritter S, Vlysidis M, Geldart K, Kaznessis YN. Antimicrobial probiotics reduce *Salmonella enterica* in turkey gastrointestinal tracts. *Sci Rep*. 2017;7(1):1-9.
7. Ljungh A, Wadstrom T. Lactic acid bacteria as probiotics. *Curr Iss Intestinal Microbiol*. 2006;7(2):73-90.
8. Maragkoudakis PA, Zoumpopoulou G, Miaris C, Kalantzopoulos G, Pot B, Tsakalidou E. Probiotic potential of *Lactobacillus* strains isolated from dairy products. *Int Dairy J*. 2006;16(3):189-199.
9. Picard C, Fioramonti J, Francois A, Robison T, Neant F, Matuchansky C. Bifidobacteria as probiotic agents—physiological effects and clinical benefits. *Aliment Pharmacol Ther*. 2005;22(6):495-512.
10. Purnama MTE, Rahmaningtyas IH, Pratama AR, Prastika Z, Kartikasari AM, Cahyo NPD. Tadpole serum activity (*Rana catesbeiana*) in caspase-3 as a marker of the role of apoptosis and total cytotoxic T lymphocytes in albino rats' epithelial cells induced by neoplasia. *Vet World*. 2019;12(1):63.
11. Hamid IS, Ekowati J, Purnama MTE. *Kaempferia galanga* L. Inhibiting Effect on Vascular Endothelial Growth Factor (VEGF) and Cyclooxygenase-2 (Cox-2) Expression on Endothelium of Chorioallantoic Membrane. *Indian Vet J*. 2019;96(09):80-82.
12. Balkwill F. TNF- $\alpha$  in promotion and progression of cancer. *Cancer Metastasis Rev*. 2006;25(3):409.
13. Horiuchi T, Mitoma H, Harashima SI, Tsukamoto H, Shimoda T. Transmembrane TNF- $\alpha$ : structure, function and interaction with anti-TNF agents. *Rheumatol*. 2010;49(7):1215-1228.
14. Sukmanadi M, Effendi MH, Fikri F, Purnama MTE. Role of Capsaicin in the Repair of Cellular Activity in Mice Liver. *Pharmacogn J*. 2021;13(6).
15. Crisostomo PR, Wang Y, Markel TA, Wang M, Lahm T, Meldrum DR. Human mesenchymal stem cells stimulated by TNF- $\alpha$ , LPS, or hypoxia produce growth factors by an NF $\kappa$ B-but not JNK-dependent mechanism. *Am J Physiol Cell Physiol*. 2008;294(3):C675-C682.
16. Wang L, Du F, Wang X. TNF- $\alpha$  induces two distinct caspase-8 activation pathways. *Cell*. 2008;133(4):693-703.
17. Alikhani M, Alikhani Z, Raptis M, Graves DT. TNF- $\alpha$  *in vivo* stimulates apoptosis in fibroblasts through caspase-8 activation and modulates the expression of pro-apoptotic genes. *J Cell Physiol*. 2004;201(3):341-348.
18. Boyle JJ, Weissberg PL, Bennett MR. Tumor necrosis factor- $\alpha$  promotes macrophage-induced vascular smooth muscle cell apoptosis by direct and autocrine mechanisms. *Arterioscler Thromb Vasc Biol*. 2003;23(9):1553-1558.
19. Zhu G, Du Q, Wang X, Tang N, She F, Chen Y. TNF- $\alpha$  promotes gallbladder cancer cell growth and invasion through autocrine mechanisms. *Int J Mol Med*. 2014;33(6):1431-1440.
20. Li J, Zhang Y, Chen L, Lu X, Li Z, Xue Y, et al. Cervical cancer HeLa cell autocrine apoptosis induced by coimmobilized IFN- $\gamma$  plus TNF- $\alpha$  biomaterials. *ACS App Mater Interface*. 2018;10(10):8451-8464.
21. Huerta-Yopez S, Vega M, Garban H, Bonavida B. Involvement of the TNF- $\alpha$  autocrine-paracrine loop, *via* NF- $\kappa$ B and YY1, in the regulation of tumor cell resistance to Fas-induced apoptosis. *Clin Immunol*. 2006;120(3):297-309.
22. Suryadiningrat M, Kurniawati DY, Mujiburrahman A, Purnama MTE. Dietary polyvinyl alcohol and alginate nanofibers ameliorate hyperglycemia by reducing insulin and glucose-metabolizing enzyme levels in rats with streptozotocin-induced diabetes. *Vet World*. 2021;14(4):847.
23. Dai WF, Zhang JJ, Qiu QF, Chen J, Yang W, Ni S, et al. Starvation stress affects the interplay among shrimp gut microbiota, digestion and immune activities. *Fish Shellfish Immunol*. 2018;80:191-199.
24. Apajalahti J, Vienola K. Interaction between chicken intestinal microbiota and protein digestion. *Anim Feed Sci Technol*. 2016;221:323-330.
25. Karczewski J, Troost FJ, Konings I, Dekker J, Kleerebezem M, Brummer RJM, et al. Regulation of human epithelial tight junction proteins by *Lactobacillus plantarum* *in vivo* and protective effects on the epithelial barrier. *Am J Physiol Gastrointest Liver Physiol*. 2010;298(6):G851-G859.
26. Palacios MC, Haros M, Rosell CM, Sanz Y. Characterization of an acid phosphatase from *Lactobacillus pentosus*: regulation and biochemical properties. *J App Microbiol*. 2005;98(1):229-237.
27. Ioachimescu OC, Stoller JK. Diffuse alveolar hemorrhage: diagnosing it and finding the cause. *Cleveland Clin J Med*. 2008;75(4):258.

28. Green RJ, Ruoss SJ, Kraft SA, Berry GJ, Raffin TA. Pulmonary capillaritis and alveolar hemorrhage: update on diagnosis and management. *Chest*. 1996;110(5):1305-1316.
29. Lara AR, Schwarz MI. Diffuse alveolar hemorrhage. *Chest*. 2010;137(5):1164-1171.
30. Fabbrizzi A, Amedei A, Lavorini F, Renda T, Fontana G. The lung microbiome: Clinical and therapeutic implications. *Int Emerg Med*. 2019;14(8):1241-1250.
31. Yang K, Dong W. Perspectives on Probiotics and Bronchopulmonary Dysplasia. *Front Pediatr*. 2020;8:605.
32. Sukmanadi M, Effendi MH, Fikri F, Purnama MTE. Liver-Histological Improvement after Capsaicin Administration in Mice with Aflatoxin B1 Toxication. *Pharmacogn J*. 2021;13(6).
33. Forsythe P. Probiotics and lung diseases. *Chest*. 2011;139(4):901-908.

## GRAPHICAL ABSTRACT



## ABOUT AUTHORS



Iwan Sahrial Hamid: Lecturer and researcher at the Division of Pharmacology, Pharmacognosy, and Pharmacotherapy, Faculty of Veterinary Medicine, Universitas Airlangga. Research interest in phytochemistry and ethnomedicine.



Juni Ekowati: Lecturer and researcher at the Department of Pharmacy, Faculty of Pharmacy, Universitas Airlangga. Research interest in phytochemicals and herbal extracts for medical applications.



Rondius Solfaine: Lecturer and researcher at the Pathology Laboratory, Faculty of Veterinary Medicine, Universitas Wijaya Kusuma. Research interests in the field of organ pathology and veterinary forensics.



Shekhar Chhetri: Lecturer and researcher at the Department of Animal Science, College of Natural Resources, Royal University of Bhutan, Bhutan. Research interest in domestic animal husbandry. Currently as an academic peerlist at Universitas Airlangga.



Muhammad Thohawi Elziyad Purnama: Lecturer and researcher at the Division of Veterinary Anatomy, Faculty of Veterinary Medicine, Universitas Airlangga. Research interests in the fields of anatomy, biomaterials and animal welfare.

**Cite this article:** MHamid IS, Ekowati J, Solfaine R, Chhetri S, Purnama MTE. Efficacy of Probiotic on Duodenal TNF- $\alpha$  Expression and the Histological Findings in the Liver and Lung in Animal Model Canine Coronavirus. *Pharmacogn J.* 2022;14(3): 591-597.