



Original Article

Effectiveness of H-files and Pro-Taper universal systems in removing Gutta-percha during endodontic retreatment: A comparative study



Sundus Atique, FCPS^a, Kamran Ali, PhD^a, Saad Haroon, MClintDent^b,
Alia Ahmed, FCPS^c, Muhammad Q. Javed, FCPS^{d,*}, Muhammad S. Zafar, PhD^{e,f,g,h} and
Ayman M. Abulhamael, MSc, FRCDSⁱ

^a Department of Preclinical Oral Health Sciences, College of Dental Medicine, Qatar University, Doha, Qatar

^b Department of Endodontics, Specialist Endodontist, Primary Health Care Corporation, Qatar

^c Department of Operative Dentistry, College of Dentistry, Riphah International University, Islamabad, Pakistan

^d Department of Conservative Dental Sciences, College of Dentistry, Qassim University, Buraidah, Qassim, KSA

^e Department of Restorative Dentistry, College of Dentistry, Taibah University, Almadinah Almunawwarah, KSA

^f Centre of Medical and Bio-allied Health Sciences Research, Ajman University, Ajman, 346, United Arab Emirates

^g School of Dentistry, University of Jordan, Amman, Jordan

^h Department of Dental Materials, Islamic International Dental College, Riphah International University, Islamabad, Pakistan

ⁱ Department of Endodontics, Faculty of Dentistry, King Abdulaziz University, Jeddah, KSA

Received 9 January 2024; revised 13 March 2024; accepted 12 April 2024; Available online 24 April 2024

الخلاصة

الهدف: الهدف من هذه الدراسة هو مقارنة فعالية المبراد اليدوية نوع هيدستروم و بين مبراد البروتيبير المستخدمة في علاج وإعادة علاج الجذور، في إزالة اقمام الجوتابيركا أثناء إعادة المعالجة اللبية باستخدام تقنية التصوير الإشعاعي الرقمي.

الطرق: هذه الدراسة تمت خارج الأجسام الحية / دراسية مختبرية، استخدمت تقنية أخذ العينات المتتالية غير الاحتمالية. واستخدمت الدراسة ستين من الأسنان الأمامية الدائمة احادية الجذور ذات القنوات المستقيمة. بعد تحضير الأسنان تم حشو القنوات واروانها بأقمام الجوتابيركا ومالي الفجوات ومن ثم تم الاحتفاظ بها لمدة اربعة عشر يوما في بيئة رطبة في درجة حرارة 37 مئوية. ثم تم اختيار ثلاثة وثلاثين من الأسنان بصورة عشوائية لمجموعتي المراقبة (المجموعة الأولى) والمجموعة التجريبية (المجموعة الثانية). تمت عملية إزالة الجوتابيركا بمبراد الهيدستروم اليدوية في المجموعة الاولى ومبراد البروتيبير الممكنة المستخدمة في علاج الجذور وإعادة علاج الجذور في المجموعة الثانية. وتم الحصول على إشعاعات رقمية باستخدام برنامج كيرستريم (كودك) إصدار رقم RVG VER.6.10.8.3-A ، وجرى تحليلها لمعرفة الفرق بين الشوالب التي تمثل بقايا الجوتابيركا. واستخدم برنامج AutoCAD 2006 في توضيح قنوات

الجذور وبقايا حشوات الجذور. واستخدم اختبار العينة المستقلة t لمقارنة مجموع ما تبقى من الجوتابيركا في كلتا المجموعتين.

النتائج: لم تتم ملاحظة أي فروق ذات دلالة إحصائية في بقايا حشو العصب باستخدام الطرق المختلفة التي تم اختبارها ومقارنتها. في كلا المجموعتين، كان الجزء المتبقي من حشو العصب محصوراً في الثلث الأسفل من الجذور.

الاستنتاجات: تعد مبراد البروتيبير الممكنة ومبراد الهيدستروم اليدوية فعالة بنفس القدر لإزالة حشو العصب من الأسنان احادية الجذور ذات القنوات المستقيمة.

الكلمات المفتاحية: طب الأسنان؛ علاج جذور الأسنان؛ دراسة في المختبر . دراسة مقارنة؛ التصوير الشعاعي للأسنان؛ إعادة المعالجة

Abstract

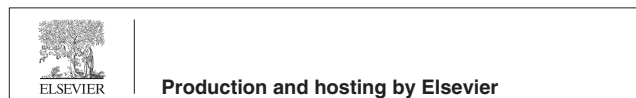Objective: This research was aimed at assessing the effectiveness of manual H-files versus a combination of a Pro-Taper universal rotary canal preparation system and retreatment system in removing gutta-percha (GP) during endodontic retreatment, by using a digital radiography technique.

Methods: This ex vivo study used a non-probability consecutive sampling technique. The study sample comprised 60 extracted anterior permanent teeth, each with one root with a straight root canal (RC). After preparation, RCs were obturated with GP and sealer. Subsequently, teeth were stored for 2 weeks in a humid

* Corresponding address: Department of Conservative Dental Sciences, College of Dentistry, Qassim University, Buraidah, PO box 1162, Qassim 51452, KSA

E-mail: m.anayat@qu.edu.sa (M.Q. Javed)

Peer review under responsibility of Taibah University.



environment at 37 °C. Thirty teeth each were randomly assigned to the control (group I), and experimental (group II) groups. GP removal was performed with H-files (group I) or a combination of a Pro-Taper universal rotary canal preparation system and retreatment system (group 2). Digital radiographs were acquired with Carestream digital radiovisio-graphy software (Kodak; version-VER.6.10.8.3-A), and the presence of residual GP was analyzed. AutoCAD (2006) software was used to demarcate the RC and residual root filling. The residual GP in both groups was compared with independent sample t-tests.

Results: The remaining root filling did not significantly differ when GP was removed with conventional Hedstrom files versus a combination of Pro-Taper Universal preparation and retreatment file systems. The residual GP was confined to the apical third of the canals in both groups.

Conclusions: Pro-Taper Universal preparation and retreatment file systems have similar effectiveness to manual H-files in GP removal in straight canals.

Keywords: Comparative study; Dental radiography; Dentistry; Endodontics; In vitro; Retreatment

© 2024 The Authors. Published by Elsevier B.V. This is an open access article under the CC BY-NC-ND license (<http://creativecommons.org/licenses/by-nc-nd/4.0/>).

Introduction

Endodontic treatment (ET) includes debridement of the diseased pulp of a tooth, followed by instrumentation and root canal system (RCS) obturation to achieve an apical, lateral, and coronal seal.¹ When performed optimally, ET has a high success rate. Nevertheless, ET failure may still occur for a variety of reasons, including apical leakage, iatrogenic root perforation, missed canals, and over/under extension of the RC obturation material. These factors may result in a failure to decrease the number of micro-organisms in the RCS and peri-radicular tissues to below the critical threshold level and may subsequently lead to ET failure.²

The management options for ET failure include ortho-grade retreatment,³ surgical endodontics,⁴ and extraction.⁵ Non-surgical endodontic retreatment (NER) is currently the preferred treatment if the tooth is restorable. NER is a conservative option that preserves the tooth, and minimizes the morbidity and complications associated with surgical endodontics.⁵ The primary objective of NER is to minimize bacterial contamination of the RCS through removal of the existing root filling, followed by cleaning, debridement, and three-dimensional filling of the RCS.⁵

GP removal during endodontic retreatment (ER) can be accomplished with an array of endodontic tools, including hand files,⁶ heat carriers, rotary instruments, ultrasonic files/tips, and solvents.⁷ Conventionally, H-files have been used alongside K-files for GP removal. GP removal is expedited by the use of solvents, such as orange extract, xylene,

chloroform, and turpentine.^{8–10} The effective dentine cutting ability of H-files make them suitable for retrieving separated instruments and GP from the RCS as part of NER.^{11,12}

The Pro-Taper Universal rotary system (PURS) (Dentsply Maillefer, Ballaigues, Switzerland) comprise assorted shaping (S1 and S2) and finishing (F1, F2, F3, F4, and F5) files, whereas, the Pro-Taper Universal Rotary system for Retreatment (PURSR) (Dentsply Maillefer, Ballaigues, Switzerland) comprises three retreatment files (D1 with an active tip, and D2 and D3 with passive tips).¹³ All PURSR files have a convex-triangular cross-section, and a tip diameter/taper/length of 0.09/0.30/16 mm (D1 for the coronal third of the RCS), 0.08/0.25/18 mm (D2 for the middle third of the RCS), and 0.07/0.20/22 mm (D3 for the apical third of the RCS). Many studies have compared PURSR with other systems, both manual and rotary; however, no studies have compared PURS and PURSR against H files.

The efficacy of instruments for root-filling (RF) removal has been evaluated with various methods. The most commonly used technique for assessing the extent of RF removal is radiography. This method is rapid, non-invasive, and easily performed.¹⁴ Nonetheless, radiographs provide a two-dimensional visualization of three-dimensional objects. This limitation may be mitigated by using cone-beam computerized tomography¹⁵ or by obtaining simultaneous radiographic images from bucco-lingual and proximal views. Digital radiography is preferred over conventional radiography because it provides an immediate view, offers improved resolution, is time-saving, and minimizes problems associated with the chemical processing of radiographic films.¹⁶

Longitudinal sectioning before photographic or microscopic analysis has also been suggested.¹⁷ Remaining RF can be quantified by imaging and measurement with computer software.¹⁸ Although this method provides direct visual access to the RC, it may pose difficulties in predictably sectioning teeth and may introduce a risk of disrupting the root structure.

Alternative methods, such as screen projection of photographs, micro-computed tomography, scanning electron microscopy, stereo-microscopy, digitalized image assessment with a scanner, and computed tomography, have been used in prior studies.^{19–22} The advent of micro-computed tomography technology has enabled more accurate, noninvasive assessment of residual GP in the RCS by revealing the three-dimensional root morphology; however, this technology is expensive and is not readily available.

Although H files are commonly used for GP removal during ER, the evidence in the literature is insufficient to compare their efficacy with that of PURSR plus PURS. Therefore, this research was aimed at assessing the comparative effectiveness of manual H-files and a combination of a Pro-Taper universal rotary canal preparation system and retreatment system for removing gutta-percha (GP) during ER, through a digital radiography technique. The null hypothesis (H_0) was no difference in efficiency between the Pro-Taper universal rotary canal preparation system plus retreatment system and manual H-files in GP removal from straight RCs during ER. The alternative hypothesis (H_A) was better performance of the combined Pro-

Taper universal rotary canal preparation system plus retreatment system than manual H-files in GP removal from straight RCs during ER.

Materials and Methods

All teeth used in the study had fully formed apices. A sample consisting of 60 permanent anterior teeth with one straight root and one canal were collected. The sample size of 60 was calculated with the World Health Organization sample size calculator with pooled SD = 3.585, residual GP with H files = 6.31,²¹ residual GP with rotary files = 3.98,²³ level of significance = 5%, and study power = 80%.

We collected teeth that had already been extracted because of advanced periodontal disease, and orthodontic and prosthodontic prescriptions. No patient sex or age requirements were imposed. All included teeth had fully formed apices and type I Vertucci's canal configuration (one orifice and one apical exit). Teeth with curved roots, root caries, intra-canal calcifications/obstructions, internal resorption, and previously RC treated teeth were excluded.

All teeth were prepared by a single experienced endodontist and were decoronated at CEJ with a high-speed air turbine, thus leaving 15–16 mm of the root (Figure 1A). RCs were cleaned with a 15-K file (Dentsply Maillefer; Ballaigues, Switzerland) and 2 ml 1% NaOCl until the apical foramen was negotiated. The working length (WL) was calculated for all teeth.

RCs were prepared with a step-back technique with apical preparation up to size 40-K files (Dentsply Maillefer; Ballaigues, Switzerland), followed by step back with subsequent K file instruments (45, 50, 55) (Figure 1B). Irrigation with 2 ml 1% NaOCl was conducted before the next file size was used. A closed-end side-vented irrigation needle was placed 2 mm from the WL. After completion of the RC instrumentation, the canal was filled with 17% EDTA solution for 3 min to remove the smear layer. Finally, RCs were flushed with 1% NaOCl (2 ml) and dried with paper points. The RCs were obturated with GP (DiaDent®), AH plus sealer® (Dentsply; Sirona USA) through the warm vertical technique with System B® (Kerr Dental) for the canal's apical part, and obtura II® (Obtura Spartan) as backfill (Figure 1C and D). Roots were stored in damp gauze for 2 weeks at 37 °C to facilitate setting of the sealer.

The teeth were assigned randomly to two groups, each with 30 specimens, according to a random number table. Chloroform, as the solvent, was placed in the canals' coronal third for 5 min before the insertion of files for GP retrieval. For group I (control group), the retrieval of GP was performed with standardized assorted H-files, until size 40²⁴ (Dentsply Maillefer; Ballaigues, Switzerland). H-files of numbers 40, 35, 30, 25, and 20 were consecutively used for GP/sealer removal, until the approximate WL was reached. The H-files were used in a 1/4th turn, push–pull, and circumferential filing motion. Subsequently, the apical area of the canals was prepared with assorted H-files (numbers 20, 25, 30, 35, and 40) sequentially until no GP/sealer was detected.

In group II (experimental group), Pro-Taper Universal Retreatment, shaping, and finishing files (up to F4)

(© Dentsply Sirona, all rights reserved) were used with an electric motor (Dentsply; X-Smart) (speed = 300 RPM; torque = 3 Ncm) for GP removal. First, PURSR instruments were used sequentially in canals (D1, coronal third; D2, middle third; D3, apical third) to remove GP/sealer. Canal instrumentation was subsequently performed with assorted PURS instruments (S1/S2/F1/F2/F3/F4). The irrigation protocol followed during the GP/Sealer removal was identical to that used during the initial tooth preparation and obturation phase. Removal time was recorded with a stopwatch for both groups. The stopwatch was started when the first instrument was used for GP removal and was stopped when the final instrument was withdrawn after GP removal was considered complete.

Evaluation

Digital periapical radiographs (DPRs) for all teeth were acquired from the bucco-lingual and proximal directions with a Kodak RVG digital radiography system. Subsequently, differences in radio-opacity within the canals indicating residual GP were analyzed in each tooth by a single operator using Kodak dental imaging software (version 6.10.8.3). The RC and residual GP were outlined with AutoCAD 2006 software by a trained operator (S.A).

The AutoCAD software tool is used to measure the volumes of two- or three-dimensional objects. The total volume of the object can be calculated, and the tool's add/subtract option can be used to calculate subvolumes. After the residual GP fragments were outlined by a trained operator, the same principle was applied to calculate the total volume of each canal on a two-dimensional DPR. The remaining amount of GP on each DPR was then outlined with the same software. Subsequently, the remaining outlined GP volume was calculated objectively in AutoCAD software (Figure 2).

Data analysis

Data were analyzed in SPSS-24 software (IBM). Mean \pm SD were calculated for the coronal, middle, apical, and total residual GP in both groups, in both the bucco-lingual and proximal directions. Total residual GP in both groups was compared with independent sample t-tests with a significance level (p-value) set at <0.05.

Results

Root length in both groups

The mean root length in both groups combined was 15.005 mm \pm 0.34 mm (Table 1). The difference in length between groups was insignificant ($p > 0.5$).

Evaluation of residual root filling material

No residual GP was observed in the coronal and middle thirds of the RCs in both groups. The residual

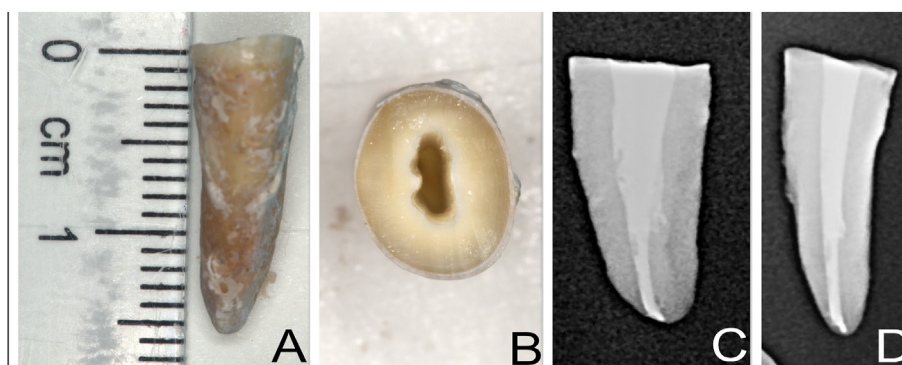


Figure 1: (A) Post decoronation 16 mm root. (B) Root cross-sectional post canal preparation view. (C) and (D) Post-obturation periapical radiographs.

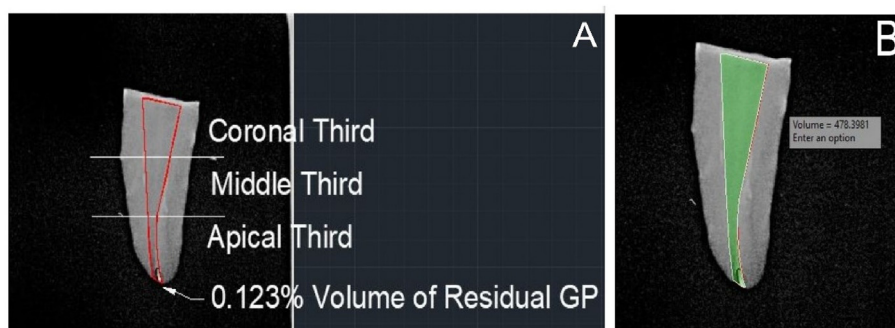

Figure 2: (A) and (B) Sample AutoCAD images for calculating the volume of residual GP.

Table 1: Root lengths of the teeth (mm).

Groups	Mean \pm SD
Group I (Hedstrom)	15.03 \pm 0.30
Group II (ProTaper)	14.98 \pm 0.38
Total	15.005 \pm 0.34

GP was confined to the apical third of the RCs in both groups. The mean percentage volume of residual GP in the canals (both in bucco-lingual and proximal direction) was higher in the control group than the experimental group (Table 2). However, the difference was statistically insignificant ($p > 0.5$). Thus, the alternative hypothesis (H_A) was rejected, and the null hypothesis (H_0) was supported.

Removal time

H-files required more time for GP removal than ProTaper files (Table 3). However, the difference in removal time between groups was insignificant ($p > 0.5$).

Table 2: Residual GP percentage volume recorded on bucco-lingual and proximal radiographs (mean \pm SD).

Groups	Bucco-lingual Mean \pm SD	Proximal Mean \pm SD
Hedstrom files	1.86 \pm 3.09	0.86 \pm 1.73
ProTaper files	0.11 \pm 0.47	0.06 \pm 0.23

Table 3: Time required for GP removal.

Groups	Time (minutes) Mean \pm SD
Hedstrom files	8.93 \pm 1.18
ProTaper files	6.18 \pm 1.32

Procedural errors

No incidence of intra-canal instrument separation, or any visible signs of plastic deformation of Ni–Ti rotary instruments or hand files were observed in either group. In addition, no iatrogenic errors, such as perforations, blockages, or ledges, were recorded.

Discussion

This research was aimed at comparing the effectiveness of the traditional method with rotary NiTi preparation and retreatment systems for GP removal in the RCS during ER procedures. Prior research has suggested that attaining a completely clean RC during ER can be challenging.²⁵

Despite the procedural difficulties and time involved, NER remains widely considered the preferred choice for endodontic failures.²⁶ The success rates for retreatment procedures range from 40% to 100%.²⁷ ER outcomes depend on numerous factors, including patient age; treated tooth type; interindividual anatomical variation in the

same teeth, the seal of the coronal restoration, the method used to access the existing filling in RC, and the possibility of repairing defects (iatrogenic or pathologic).^{28–31}

GP, a thermoplastic material for RC filling, is typically used in conjunction with various sealers.³² Access to necrotic pulp remnants and residual microorganisms requires efficient removal of the GP and sealer, followed by appropriate chemico-mechanical root canal re-instrumentation.³³ On the basis of prior research, no existing techniques can ensure the complete removal of old filling materials from the RC.^{15,34}

In the current study, decoronation of teeth was performed at the cements-enamel junction, thereby leaving 15–16 mm of roots. Although decoronation does not simulate retreatment in clinical conditions, it enables standardization of specimens by controlling variables, such as the tooth crown's morphology, and access to the RCS, thus providing a more reliable means of comparing the methods used for retreatment in endodontics.³⁵

All procedures were performed by a single operator to eliminate operator-dependent confounders, and the measuring instruments were all standardized. The Ni–Ti rotary files used on a low-speed electric motor at low torque were applied according to the manufacturer's instructions. These factors enhance tactile feedback and minimize the risk of file separation.

Radiographic evaluation is the most frequently used method to assess the extent of root filling material removal.^{36,37} However, the assessment process may be complicated if two-dimensional dental radiographs are used. These limitations were addressed herein by exposing radiographs from both the bucco-lingual and proximal views. Moreover, digital images were evaluated with AutoCAD 2006 software to reliably quantify the residual filling material and minimize subjectivity in the evaluation process. The radiographic method allowed us to avoid longitudinal tooth sectioning, during which sealer/tooth-filling material may be lost.³⁸ Some studies have suggested combining radiographic assessment of the residual root filling materials (RFM) and longitudinal sectioning, to provide a more accurate picture of the remaining RFM.³⁹

Various scoring systems have been used to calculate the quantity of residual RFM, and to assess the efficacy of the technique used for removal. Hülsmann and Stotz⁴⁰ have proposed scores for the evaluation of residual RFM in RC after longitudinal sectioning. The residual RFM in the root has been divided into six categories ranging from complete RFM removal to the presence of many residual (GP) masses >2 mm in the apical, coronal, and middle thirds of the RC. Other researchers have used comparable scoring systems with fewer categories, such as severe {>75%}, moderate {50–75%}, mild {25–50%}, or no residual debris {0–25%}.¹⁹ Despite its benefits, the examination of sectioned teeth is time-consuming and does not provide any information about the volume of residual RFM; moreover, it does not offer insights into potential canal transportation errors, which can influence retreatment outcomes.⁴¹

The choice of solvent in the current research was influenced by the existing literature as well as the relevance to

current clinical practice. The relative efficacy of various solvents has been extensively investigated.⁴² Solvents have been used for years for softening and removal of GP. Historically, chloroform has been the preferred solvent for GP softening, because of its demonstrated effectiveness.⁴³ However, cytotoxicity and potential carcinogenicity remain major concerns, particularly after its extrusion into the periapical tissues. Several other solvents have been used to explore less toxic alternatives. GP retrieval with Ni–Ti rotary files, with or without solvent, has also been documented.⁴⁴

Although this research did not indicate significant differences between groups, previous research has suggested that rotary instruments achieve cleaner dentinal walls than manual techniques.⁴⁵ Hullaman and Blum have reported lower volumes of residual RFM in the middle and apical thirds of the RC with the use of rotary instruments rather than hand instruments.⁴⁶ The percentage RFM in the apical third of the RC was higher than that in the coronal and middle thirds of the RC, in agreement with prior research,⁴⁷ as noted in the radiographic/microscopic evaluation of study samples. This finding underscores that the apical third is a critical zone requiring thorough instrumentation.

Teeth with one straight RC were chosen to minimize variability in this study. Because variations might still have been encountered in root canal anatomy, thus making strict standardization difficult, we removed the coronal portion of the root to achieve consistent root length for instrumentation and obturation. To better recapitulate clinical conditions, we stored the teeth in the study at 37 °C under 100% humidity after obturation.²¹ Many studies have used extracted teeth to analyze residual GP. One study has used resin blocks,⁴⁸ which are easy to obtain and standardize; however, the nature of their substrate differs from that of the tooth tissue, and they do not recapitulate some aspects of the RCS of natural teeth.

The efficacy of removal of RFM can be measured according to the time required.⁴⁹ A comparison of the time required for RFM removal with various rotary and manual techniques has been reported.⁵⁰ Given the frequent use of rotary NiTi systems in contemporary endodontics, the findings of our study may support informed clinical decision-making. Determining when RC filling material removal is complete is clinically and experimentally challenging. Because of the lack of specific scientific methods of measurement, operators must make subjective decisions. Different criteria have been used for assessment, thus potentially resulting in a lack of standardization within and between studies. Endpoints also vary across studies. The techniques used among operator considerably vary: some operators stop when the canals are deemed clean,⁵¹ whereas others stop when no remaining RFM is visible on the last used instrument.²² Other studies have used endpoints of removal of no further RFM after reaching full WL^{52,53} or no RFM visible in the canal with the naked eye.¹⁴ Although some studies have suggested cleaning canals until smooth dentinal chips begin to appear, this approach is no longer used because of its impracticality. A more reliable and scientific method would

be to use a radiograph to determine the endpoint. When no RFM is evident on the check radiograph, the removal of the old RFM may be considered complete.⁴⁶

Limitations

Some limitations of the study must be acknowledged. First, the study sample was small and used only anterior natural teeth with straight canals. Second, two-dimensional radiographs were used to assess the volume of residual GP after ER was performed.

Future recommendations

Future studies involving larger sample sizes, including a variety of natural teeth with variable degrees of root curvature, are recommended to enhance the generalizability and applicability of the research findings. Moreover, incorporation of three-dimensional imaging techniques, such as Micro-CT and CBCT, is recommended for measuring the volumes of the canal and the residual GP, thus increasing the reliability of the results.

Conclusions

This in vitro study compared the efficacy of GP removal with Hedstrom and ProTaper rotary files during NER. Evaluation of DPR indicated the presence of residual GP in the apical third of teeth in both groups. Although the ProTaper appeared to be more efficient in GP removal, no significant differences were observed between the study and control groups. Full WL was achieved in all RCs. Under similar conditions, the ProTaper systems and Hedstrom files were equally effective in removing GP during ER in teeth with straight single canals.

The inability of both study groups (ProTaper systems and Hedstrom files) to completely remove GP from RCs apical third highlights the importance of using a combination of mechanical instruments and adequate irrigation techniques/materials for achieving adequate removal of GP from the RCS in the apical third. This combined method may ultimately enhance the clinical success of ER procedures as well as patient satisfaction.

Source of funding

This research did not receive any specific grant from funding agencies in the public, commercial, or not-for-profit sectors.

Conflict of interest

The authors have no conflict of interest to declare.

Ethical approval

Given the study's in vitro nature, the ethical review board of Riphah University exempted the research from oversight (ref. No. IID/IRC/2019/008/010, Dated: 29/08/2019).

Authors contributions

Conceptualization, SA and AA; methodology, SA and MQJ; software, SA and MQJ; validation, MSZ, KA, and AMA; formal analysis, SH and KA; investigation, SA; resources, SH and SA; data curation, SA and SH; writing—original draft preparation, SA, MQJ, and AA; writing—review and editing, SH, MSZ, AMA, and KA; visualization, MSZ and AMA; supervision, AA; project administration, SA and MQJ. All authors have critically reviewed and approved the final draft and are responsible for the content and similarity index of the manuscript.

References

1. Al Yahya RS, Al Attas MH, Javed MQ, Khan KI, Atique S, Abulhamael AM, et al. Root canal configuration and its relationship with endodontic technical errors and periapical status in premolar teeth of a Saudi sub-population: a cross-sectional observational CBCT study. *Int J Environ Res Publ Health* **2023**; *20*(2): 1142.
2. Tandra Das T, Pradeep S. Microbial etiology of root canal treatment failure. *Int J Pharm Technol* **2016**; *8*(3):4458.
3. Sağlam H. Non-surgical endodontic retreatment of anterior tooth with a large periapical lesion and extruded gutta percha with 36 Months follow-up: a case report. *Open J Stomatol* **2021**; *11*(4): 166–178. <https://doi.org/10.4236/ojst.2021.114014>.
4. Surgical endodontic management after conventional root canal treatment failure: a case report. *Int J Oral Health Dent* **2020**; *4*(1). <https://doi.org/10.18231/2395-499x.2018.0013>.
5. Roda RS, Gettleman BH, Johnson SC. Nonsurgical retreatment. In: Berman LH, Hargreaves KM, editors. *Pathways of pulp*. St. Louis, Missouri: Elsevier; 2021 [Chapter 10].
6. Margasahayam S v, Beble GD, Shenoy VU, Patil AB, Khan SA. Efficacy of passive ultrasonic activation assisted hand vs. Rotary retreatment files in the removal of root canal filling material: an in vitro study. *J Clin Diagn Res* **2020**. <https://doi.org/10.7860/jcdr/2020/42735.13487>. Published online.
7. Agrawal P, Ramanna PK, Arora S, Sivarajan S, Jayan A, Sangeetha KM. Evaluation of efficacy of different instrumentation for removal of gutta-percha and sealers in endodontic retreatment: an in vitro study. *J Contemp Dent Pract* **2019**; *20*(11): 1269–1273. <https://doi.org/10.5005/jp-journals-10024-2670>.
8. Boariu M, Nica LM, Marinescu A, Ganea EV, Velea O, Pop DM, et al. Efficiency of eucalyptol as organic solvent in removal of gutta-percha from root canal fillings. *Rev Chem* **2015**; *66*(6): 907–910.
9. Khiyani S. Evaluation of the dissolving efficacy of four organic solvents on gutta-percha: an in vitro study. *IOSR J Dent Med Sci* **2017**; *16*(7): 83–86.
10. Maria R, Dutta SD, Thete SG, Alattas MH. Evaluation of antibacterial properties of organic gutta-percha solvents and synthetic solvents against *Enterococcus faecalis*. *J Int Soc Prev Community Dent* **2021**; *11*(2): 179–183. <https://doi.org/10.4103/jspcd.JISPCD-422-20>.
11. Gencoglu N, Helvacioğlu D. Comparison of the different techniques to remove fractured endodontic instruments from root canal systems. *Eur J Dermatol* **2009**; *3*(2): 90–95. <https://doi.org/10.1055/s-0039-1697413>.
12. Silva PA, Alcalde MP, Vivan RR, Duarte MAH. Comparison of the self-adjusting file and hedström file used as supplementary instruments for the remaining filling material removal during retreatment of c-shaped canals: a Micro-CT study. *Eur Endod J* **2020**; *5*(2): 112–118. <https://doi.org/10.14744/ej.2020.50570>.

13. Capar ID, Arslan H, Ertas H, Gök T, Saygili G. Effectiveness of ProTaper Universal retreatment instruments used with rotary or reciprocating adaptive motion in the removal of root canal filling material. *Int Endod J* 2015; 48(1): 79–83. <https://doi.org/10.1111/iej.12279>.
14. Schirmeister JF, Hermanns P, Meyer KM, Goetz F, Hellwig E. Detectability of residual Epiphany and gutta-percha after root canal retreatment using a dental operating microscope and radiographs - an ex vivo study. *Int Endod J* 2006; 39(7): 558–565. <https://doi.org/10.1111/j.1365-2591.2006.01126.x>.
15. Zhang MM, Fang GF, Chen XT, Liang YH. Four-year outcome of nonsurgical root canal retreatment using cone-beam computed tomography: a prospective cohort study. *J Endod* 2021; 47(3): 382–390. <https://doi.org/10.1016/j.joen.2020.10.020>.
16. Ting NA, Broadbent JM, Duncan WJ. Dental radiography in New Zealand: digital versus film. *N Z Dent J* 2013; 109(3): 107–114.
17. Gokturk H, Yucler AC, Sisman A. Effectiveness of four rotary retreatment instruments during root canal retreatment. *Cumhuriyet Dental J* 2015; 18(1): 25–36. <https://doi.org/10.7126/cdj.58140.5000039374>.
18. Taşdemir T, Yildirim T, Çelik D. Comparative study of removal of current endodontic fillings. *J Endod* 2008; 34(3): 326–329. <https://doi.org/10.1016/j.joen.2007.12.022>.
19. Ezzie E, Fleury A, Solomon E, Spears R, He J. Efficacy of retreatment techniques for a resin-based root canal obturation material. *J Endod* 2006; 32(4): 341–344. <https://doi.org/10.1016/j.joen.2005.09.010>.
20. Saad AY, Al-Hadlaq SM, Al-Katheeri NH. Efficacy of two rotary NiTi instruments in the removal of gutta-percha during root canal retreatment. *J Endod* 2007; 33(1): 38–41.
21. Hammad M, Qualtrough A, Silikas N. Three-dimensional evaluation of effectiveness of hand and rotary instrumentation for retreatment of canals filled with different materials. *J Endod* 2008; 34(11): 1370–1373. <https://doi.org/10.1016/j.joen.2008.07.024>.
22. Barletta FB, Rahde NDM, Limongi O, Moura AAM, Zanesco C, Mazocatto G. In vitro comparative analysis of 2 mechanical techniques for removing gutta-percha during retreatment. *J Can Dent Assoc* 2007; 73(1).
23. Masiero AV, Barletta FB. Effectiveness of different techniques for removing gutta-percha during retreatment. *Int Endod J* 2005; 38(1): 2–7.
24. Kasam S, Mariswamy AB. Efficacy of different methods for removing root canal filling material in retreatment - an in-vitro study. *J Clin Diagn Res* 2016; 10(6). <https://doi.org/10.7860/JCDR/2016/17395.7904>.
25. Zmener O, Pameijer CH, Banegas G. Retreatment efficacy of hand versus automated instrumentation in oval-shaped root canals: an ex vivo study. *Int Endod J* 2006; 39(7): 521–526. <https://doi.org/10.1111/j.1365-2591.2006.01100.x>.
26. Anisa PDN, Prisinda D. Non-surgical root canal re-treatment of maxillary right lateral incisor in geriatric patient. *Jurnal Kedokteran Gigi Universitas Padjadjaran* 2020; 32(3): 232–243. <https://doi.org/10.24198/jkg.v32i3.29548>.
27. Paik S, Sechrist C, Torabinejad M. Levels of evidence for the outcome of endodontic retreatment. *J Endod* 2004; 30(11): 745–750. <https://doi.org/10.1097/01.don.0000137636.93933.51>.
28. Imura N, Pinheiro ET, Gomes BPFA, Zaia AA, Ferraz CCR, Souza-Filho FJ. The outcome of endodontic treatment: a retrospective study of 2000 cases performed by a specialist. *J Endod* 2007; 11: 1278–1282. <https://doi.org/10.1016/j.joen.2007.07.018>.
29. Pedro FM, Marques AT, Pereira TM, Bandeca MC, Lima SN, Kuga MC, Tonetto MR, et al. Status of endodontic treatment and the correlations to the quality of root canal filling and coronal restoration. *J Contemp Dent Pract* 2016; 17(10): 830–836. <https://doi.org/10.5005/jp-journals-10024-1939>.
30. Yancheshmeh SSY. Examining the factors affecting endodontic therapy failure. *J Mol Biol Res* 2020; 10(1): 1–5. <https://doi.org/10.5539/jmbr.v10n1p1>.
31. Dioguardi M, Di Gioia G, Illuzzi G, Arena C, Caponio VC, Caloro GA, et al. Inspection of the microbiota in endodontic lesions. *Dent J* 2019; 7(2): 47. <https://doi.org/10.3390/dj7020047>.
32. Pandey P, Aggarwal H, Tikku AP, Singh A, Bains R, Mishra S. Comparative evaluation of sealing ability of gutta percha and resilon as root canal filling materials- a systematic review. *J Oral Biol Craniofac Res* 2020; 10(2): 220–226. <https://doi.org/10.1016/j.jobcr.2019.12.004>.
33. Zandi H, Petronijevic N, Mdala I, Kristoffersen AK, Enersen M, Rôças IN, et al. Outcome of endodontic retreatment using 2 root canal irrigants and influence of infection on healing as determined by a molecular method: a randomized clinical trial. *J Endod* 2019; 45(9): 1089–1098. <https://doi.org/10.1016/j.joen.2019.05.021>.
34. de Carvalho Maciel AC, Zaccaro Scelza MF. Efficacy of automated versus hand instrumentation during root canal retreatment: an ex vivo study. *Int Endod J* 2006; 39(10): 779–784. <https://doi.org/10.1111/j.1365-2591.2006.01148.x>.
35. Kumar T, Mittal S, Keshav V, Kaur R, Maakhni E. A comparative evaluation of remaining dentin thickness following biomechanical preparation of teeth using different rotary file systems: an in vitro study. *Journal of Conservative Dentistry and Endodontics* 2022; 25(1): 32–36.
36. Santos LGP, Felipe WT, Souza BDM, Konrath AC, Cordeiro MMR, Felipe MCS. Radiographic and scanning electron microscopic assessment of root canal filling remnants after endodontic re-instrumentation. *Braz Dent Sci* 2017; 20(1): 80–91. <https://doi.org/10.14295/bds.2017.v20i1.1325>.
37. Kfir A, Tsesis I, Yakirevich E, Matalon S, Abramovitz I. The efficacy of five techniques for removing root filling material: microscopic versus radiographic evaluation. *Int Endod J* 2012; 45(1): 35–41. <https://doi.org/10.1111/j.1365-2591.2011.01944.x>.
38. Masiero AV, Barletta FB. Effectiveness of different techniques for removing gutta-percha during retreatment. *Int Endod J* 2005; 38(1): 2–7. <https://doi.org/10.1111/j.1365-2591.2004.00878.x>.
39. Bramante CM, Betti LV. Efficacy of Quantec rotary instruments for gutta-percha removal. *Int Endod J* 2000; 5: 463–467. <https://doi.org/10.1046/j.1365-2591.2000.00340.x>.
40. Hülsmann M, Stotz S. Efficacy, cleaning ability and safety of different devices for gutta-percha removal in root canal retreatment. *Int Endod J* 1997; 30(4): 227–233. <https://doi.org/10.1046/j.1365-2591.1997.00036.x>.
41. Gorni FGM, Gagliani MM. The outcome of endodontic retreatment: a 2-yr follow-up. *J Endod* 2004; 30(1): 1–4. <https://doi.org/10.1097/00004770-200401000-00001>.
42. Dotto L, Sarkis-Onofre R, Bacchi A, Pereira GKR. The use of solvents for gutta-percha dissolution/removal during endodontic retreatments: a scoping review. *J Biomed Mater Res B Appl Biomater* 2021; 109(6): 890–901. <https://doi.org/10.1002/jbm.b.34753>.
43. Karataş E, Kol E, Bayrakdar IS, Arslan H. The effect of chloroform, orange oil and eucalyptol on root canal transportation in endodontic retreatment. *Aust Endod J* 2016; 42(1): 37–40. <https://doi.org/10.1111/aej.12126>.
44. Bhagavaldas M, Diwan A, Kusumvalli S, Pasha S, Devale M, Chava D. Efficacy of two rotary retreatment systems in removing Gutta-percha and sealer during endodontic

- retreatment with or without solvent: a comparative in vitro study. *J Conserv Dent* 2017; 20(1): 37–40. <https://doi.org/10.4103/0972-0707.209075>.
45. Alakabani TF, Faus-Llácer V, Faus-Matoses I, Ruiz-Sánchez C, Zubizarreta-Macho Á, Sauro S, et al. The efficacy of rotary, reciprocating, and combined non-surgical endodontic retreatment techniques in removing a carrier-based root canal filling material from straight root canal systems: a micro-computed tomography analysis. *J Clin Med* 2020; 9(6):1989. <https://doi.org/10.3390/jcm9061989>.
 46. Hülsmann M, Bluhm V. Efficacy, cleaning ability and safety of different rotary NiTi instruments in root canal retreatment. *Int Endod J* 2004; 37(7): 468–476. <https://doi.org/10.1111/j.1365-2591.2004.00823.x>.
 47. Reddy S, Neelakantan P, Saghiri MA, Lotfi M, Subbarao CV, Garcia-Godoy F, et al. Removal of gutta-percha/zinc-oxide-eugenol sealer or gutta-percha/epoxy resin sealer from severely curved canals: an in vitro study. *Int J Dent* 2011. <https://doi.org/10.1155/2011/541831>. Published online.
 48. Iizuka N, Takenaka S, Shigetani Y, Okiji T. Removal of resin-based root canal filling materials with K3 rotary instruments: relative efficacy for different combinations of filling materials. *Dent Mater J* 2008; 27(1): 75–80. <https://doi.org/10.4012/dmj.27.75>.
 49. Beasley RT, Williamson AE, Justman BC, Qian F. Time required to remove guttacore, thermafil plus, and thermoplasticized gutta-percha from moderately curved root canals with protaper files. *J Endod* 2013; 39(1): 125–128. <https://doi.org/10.1016/j.joen.2012.10.014>.
 50. Muraleedhar Av, Satish SV, Patil AM, Kovvuru SK, Patil S. Comparative evaluation of efficacy of three different rotary retreatment systems with manual instrumentation in removing gutta-percha from root canals – an in vitro study. *J Evol Med Dent Sci* 2021; 10(14): 1025–1030. <https://doi.org/10.14260/jemds/2021/219>.
 51. Ferreira JJ, Rhodes JS, Pitt Ford TR. The efficacy of gutta-percha removal using ProFiles. *Int Endod J* 2001; 34(4): 267–274. <https://doi.org/10.1046/j.1365-2591.2001.00379.x>.
 52. Taşdemir T, Er K, Yildirim T, Çelik D. Efficacy of three rotary NiTi instruments in removing gutta-percha from root canals. *Int Endod J* 2008; 41(3): 191–196. <https://doi.org/10.1111/j.1365-2591.2007.01335.x>.
 53. Co N. Non-surgical retreatment: experimental studies on the removal of root filling materials. *Rev Literat Arts Am* 2010; 4(2): 111–126.

How to cite this article: Atique S, Ali K, Haroon S, Ahmed A, Javed MQ, Zafar MS, Abulhamael AM. Effectiveness of H-files and Pro-Taper universal systems in removing Gutta-percha during endodontic retreatment: A comparative study. *J Taibah Univ Med Sc* 2024;19(3):537–544.