



Review Article

Review of adverse events associated with COVID-19 vaccines, highlighting their frequencies and reported cases

Harshini Yaamika, B. Pharm, Divya Muralidas, B. Pharm and Karthikeyan Elumalai, Ph.D*

Department of Pharmaceutical Chemistry, Saveetha Institute of Medical and Technical Sciences, Chennai, Tamilnadu, India

Received 21 May 2023; revised 14 July 2023; accepted 28 August 2023; Available online 5 September 2023



المخلص

تتناول هذه المراجعة الأحداث الجانبية السلبية المرتبطة بالجهاز المناعي والأمراض المناعية الذاتية (التي تعرف بالأحداث الجانبية السلبية بعد التطعيم) المرتبطة بلقاحات كوفيد-19، وتسلسل الضوء على تكرارها، والحالات المبلغ عنها، والصلة مع فئات اللقاحات المحددة. مفهوم "قلة الصفحات الجلدية المناعية المستحثة باللقاح" مهم في التعامل مع التشكك في اللقاحات. فهم هذه المفاهيم يساعد العاملين في الرعاية الصحية على تحديد وإدارة الأحداث الجانبية المحتملة بعد التطعيم. على الرغم من ندرتها، يمكن أن تسبب الأحداث الجانبية السلبية بعد التطعيم قلقاً وتوتراً بين المجتمع. يجب على العاملين في الرعاية الصحية والوكالات الصحية العامة مراقبة هذه الأحداث بنشاط والتعامل معها للحفاظ على ثقة المجتمع في برامج التطعيم. يتضمن ذلك الكشف السريع عن الحوادث المشبوهة، وتبني إجراءات للتخفيف من الأخطار، وإبلاغ المجتمع بمعلومات دقيقة وشفافة. البحث المستمر والمراقبة أمران ضروريان لفهم الآليات الممكنة وراء هذه الأحداث الجانبية وتطوير استراتيجيات لتقليل حدوثها.

الكلمات المفتاحية: تطعيم كوفيد-19؛ التهاب العضلة القلبية؛ الآثار الجانبية الدورية؛ التطعيم؛ الالتهاب

Abstract

This review examines the immunological and autoimmune adverse events associated with COVID-19 vaccines, highlighting their frequencies, reported cases, and associations with specific vaccine classes. The concept of vaccine-induced immune thrombotic thrombocytopenia is crucial in

addressing vaccine skepticism. Understanding this concept helps healthcare professionals identify and manage potential adverse events after vaccination. Despite their rarity, immunological and autoimmune adverse events cause concern and anxiety among the public. To maintain public trust in vaccination programs, healthcare professionals and public health agencies must actively monitor and address these adverse events, promptly disclose suspicious incidents, take measures to mitigate dangers, and inform the public with transparency and accurate information. Continuing research and surveillance are essential for understanding the underlying mechanisms of these adverse events and developing strategies to minimize their occurrence.

Keywords: COVID-19 vaccination; Myocarditis; Circulatory adverse effects; Immunization; Inflammation; Healthcare professionals

© 2023 The Authors. Published by Elsevier B.V. This is an open access article under the CC BY-NC-ND license (<http://creativecommons.org/licenses/by-nc-nd/4.0/>).

Introduction

The novel coronavirus SARS-CoV-2 was discovered in December 2019 and has since caused approximately 170 million cases and 3.5 million deaths. The disastrous effects of COVID-19 on human life, the economy, and other facets of society persist despite the implementation of protective measures. Symptoms include fever, cough, headache, exhaustion, difficulty breathing, and a decreased sense of smell and taste.¹ COVID-19 nucleic acid is detected in nasopharyngeal swab samples through reverse transcription-polymerase chain reaction (RT-PCR) testing, thrombotic microangiopathy (TMA), or reverse-transcription loop-mediated isothermal

* Corresponding address: Department of Pharmaceutical Chemistry, Saveetha Institute of Medical and Technical Sciences, Chennai, Tamilnadu, India.

E-mail: karthikeyanelumalai@hotmail.com (K. Elumalai)

Peer review under responsibility of Taibah University.



amplification. RT-PCR is frequently used in diagnostics and is the gold standard for testing COVID-19. In contrast, TMA detects COVID-19 analogously to RT-PCR by using a different set of enzymes and reagents to amplify the viral RNA. The TMA method may yield false negatives in cases with low viral load, and consequently may not be accessible in certain healthcare settings. Vaccines are the most important public health measure to protect people from COVID-19, because SARS-CoV-2 is highly contagious.^{2,3} Vaccine trials involve several stages, including preclinical testing on animals to assess safety and effectiveness, followed by clinical trials involving human participants.⁴ These trials are conducted in multiple phases, starting with a small group of volunteers and gradually increasing the number of participants to gather more data on safety and efficacy. Rare adverse effects of COVID-19 vaccines include anaphylaxis, blood clots, myocarditis, pericarditis, hearing changes, and tinnitus.⁵ The overall risk of anaphylaxis is quite low, and these reactions occur in a small percentage of people after vaccination. To ensure vaccine recipients' health and safety, medical personnel carefully track and treat any adverse reactions.⁶ The various types of vaccines approved or authorized for immunization are listed in Table 1.

Clinical trials evaluate the safety and effectiveness of COVID-19 vaccines in specific populations, including children, pregnant women, and people with underlying health conditions. Inactivated vaccines tend to cause either no or mild adverse effects. These vaccines minimize risk, because medical professionals are trained to identify and treat adverse reactions promptly.⁷ Extensive research and rigorous testing are conducted before vaccines are approved for public use, to ensure their safety and efficacy. The CDC monitors vaccine safety and provides guidelines for healthcare professionals to manage and report adverse events.⁸ By closely monitoring and addressing these rare adverse effects, the medical community can ensure the overall safety and effectiveness of vaccines in protecting individuals and communities against infectious diseases. For example, the CDC detected a rare adverse effect called myocarditis in a small number of cases. However, the risk of myocarditis from COVID-19 itself has been determined to be substantially greater than the danger from vaccination. Healthcare professionals have been able to educate patients regarding potential adverse effects and to provide reassurance about the overall safety and benefits of vaccination. Despite initial concerns regarding myocarditis associated with COVID-19 vaccines, data have indicated that

the risk of developing this condition is significantly lower than the risk associated with SARS-CoV-2 infection (Figure 1).⁹ Myocarditis is also uncommon and usually resolves without lingering effects. Importantly, although the risk of developing myocarditis from COVID-19 vaccines may be low, it remains a potential adverse effect that individuals should be aware of in making informed vaccination decisions. This article discusses the adverse effects of COVID-19 vaccines and provides advice regarding how medical practitioners might mitigate those effects.

Circulatory system

Vaccines have been developed to slow the spread of the SARS-CoV-2 virus, but they have led to substantial adverse reactions in various organ systems, such as migraines, fever, exhaustion, injection site reactions, and circulatory problems. Circulatory adverse effects include myocarditis, pericarditis, thrombotic events, arrhythmias, hypertension, acute coronary syndrome, cardiac arrest, and anemia. These adverse effects are rare and occur in a small percentage of individuals receiving COVID-19 vaccines (Figure 2). However, the benefits of vaccination in preventing severe illness and hospitalization far outweigh the potential risks associated with these adverse effects. Healthcare professionals vigilantly monitor and manage potential adverse reactions to ensure the safety and well-being of individuals receiving the vaccine.¹⁰

Heart

Myocarditis and pericarditis side effect

A 24-year-old man with no prior history of cardiac conditions experienced severe substernal chest pain after receiving his second Moderna COVID-19 vaccine. Within a day, his symptoms worsened, including substernal chest pain that was more severe when he was lying flat. After receiving the primary vaccine dose, he had experienced similar but less severe symptoms. Elevated troponin levels and negative viral serology were found in laboratory tests.¹¹ On cardiac magnetic resonance imaging (MRI), the left ventricle of the heart showed edema and delayed gadolinium enhancement in the mid-myocardium and on the heart surface. One study has reported that, at home, in the first 5 days after the primary dose of COVID-19 vaccine, 113 healthcare professionals

Table 1: Vaccines approved for immunization.

S. No.	Common name	Type	Country of origin	First authorization
1.	Oxford-AstraZeneca	Adenovirus vector	United Kingdom	December 2020
2.	Pfizer-BioNTech	RNA	Germany, United States	December 2020
3.	Janssen	Adenovirus vector	United States, the Netherlands	February 2021
4.	Moderna	RNA	United States	December 2020
5.	Sputnik V	Adenovirus vector	Russia	August 2020
6.	Novavax	Subunit/virus like particle	United States	December 2021
7.	Sanofi-GSK	Subunit	France	November 2022
8.	EpiVacCorona	Subunit	Russia	October 2020
9.	ZyCoV-D	DNA	India	August 2021
10.	COVAX-19	Subunit	Australia, Iran	October 2021
11.	Turkovac	Inactivated	Turkey	December 2021
12.	CoVLP	Virus like particle	Canada, United Kingdom	February 2022

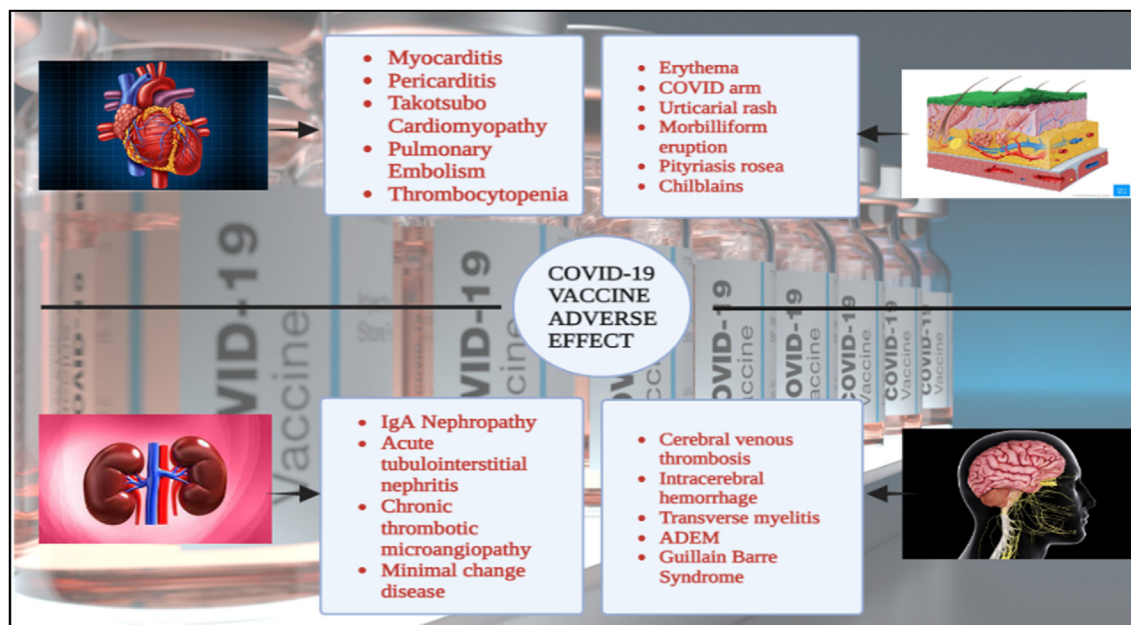


Figure 1: Adverse effects of COVID-19 vaccines.

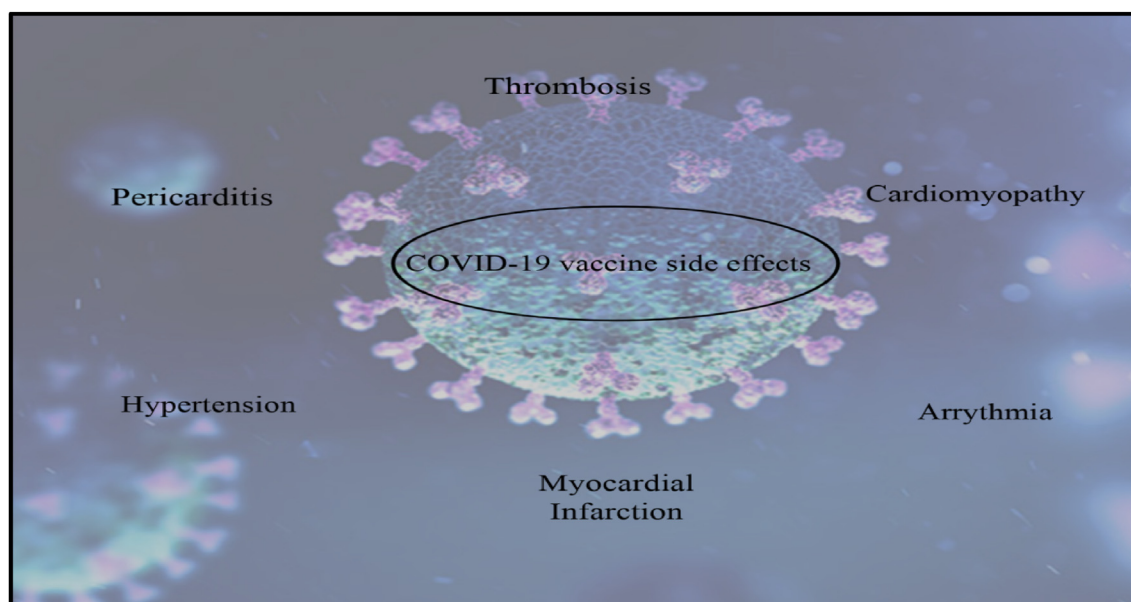


Figure 2: Various adverse effects associated with COVID-19 vaccines.

experienced a significant increase in systolic and diastolic blood pressure exceeding 10 mm Hg. Additional potential adverse effects of COVID-19 vaccines are myocarditis and pericarditis, which involve inflammation of the heart muscle or the lining around the heart. These conditions occur more frequently in males younger than 30 years, particularly after the second dose of an mRNA vaccine. However, the incidence of these conditions remains extremely rare, at only several cases per million doses administered. Symptoms are typically mild and resolve with appropriate treatment.¹²

A 25-year-old white man with a prior diagnosis of attention-deficit/hyperactivity disorder experienced symptoms

of fatigue, fever, chills, a runny nose, and progressive, sharp chest pain just behind or below the sternum. The symptoms began 72 h after the second COVID-19 mRNA vaccine dose, and no further adverse effects were observed. The patient was hemodynamically stable, with a temperature of 36.7 °C, a blood pressure of 144/97 mm Hg, a heart rate of 97 beats per minute, a breathing rate of 19 breaths per minute, and an oxygen saturation level of 97% in room air.¹³ Electrocardiography indicated diffuse ST elevation, a sign of pericarditis, as well as low to moderate pericardial effusion as high as 1.4. Figure 3 shows the reported patient data for myocarditis.

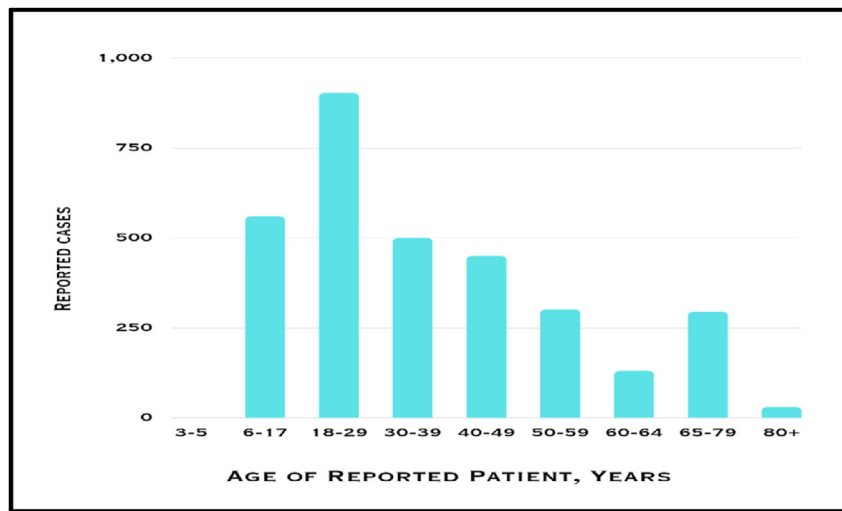


Figure 3: Graphical representation of patients with reported myocarditis, by age.

Spike protein effects of COVID-19 vaccines (angiotensin-II accumulation)

Recent evidence has suggested that the SARS-CoV-2 spike protein has a similar structure and ability to bind receptors to those of the spike protein synthesized by the body after immunization. Consequently, internalization and destruction of ACE2 may result from interactions between the spike proteins released by damaged cells and other cells' ACE2, thus leading to inflammation, thrombosis, and elevated blood pressure.¹² In addition, substantial evidence indicates that an increased deficit in angiotensin-converting enzyme has unfavorable effects on blood pressure, thrombosis, and inflammation. The patient's steady vital signs and diagnostic tests indicate that they are in good health, with an ECG demonstrating ST elevation associated with pericarditis and low troponin increase. However, the potential implications of further ACE deficiency on blood pressure, thrombosis, and inflammation must critically be considered.⁵ Such deficiency can exacerbate existing cardiovascular issues and potentially lead to complications such as hypertensive crises or an elevated risk of clot formation. Monitoring patients' cardiovascular health and managing potential risks are essential. Electrocardiography findings of ST elevation consistent with pericarditis and minimal troponin elevation may indicate myocardial injury. Additional tests, such as cardiac MRI or coronary angiography, can be used to assess the extent of damage and determine appropriate treatment strategies. Ensuring that patients are taking suitable medications can aid in management of their cardiovascular health and minimization of the risk of complications. Not all cases of pericarditis with minimal troponin elevation result in myocardial injury; thus, considering the patient's medical history and performing a thorough evaluation are crucial before the extent of cardiac damage is concluded.⁸

Thrombocytopenia

Because COVID-19 vaccines stimulates the immune system and causes inflammation, large platelets grow and facilitate blood clotting, and antibodies to platelet factor-4 are produced. Consequently, S protein is produced, and

subsequently triggers the production of thromboxane A2 and cyclooxygenase-2 in megakaryocytes. TxA2 stimulates platelets to synthesize COX-2, which causes platelets to become active, stick together, and cause thrombotic inflammation. Thrombocytopenia, a condition characterized by a low platelet count, has emerged as a potential complication of COVID-19 immunization. The exact pathogenesis of thrombocytopenia after COVID-19 immunization remains unclear, but several hypotheses have been proposed. One example of thrombocytopenia after COVID-19 immunization is immune thrombocytopenic purpura, in which the body attacks its platelets after vaccination, thereby leading to bleeding and bruising. Another possible mechanism is vaccine-induced prothrombotic immune thrombocytopenia (VIPIT), wherein abnormal blood clots occur alongside low platelet levels, thus potentially causing severe complications such as deep vein thrombosis or cerebral venous sinus thrombosis.¹⁴ The reported cardiovascular cases due to immunization are shown in Table 2.

The occurrence of VIPIT highlights the importance of recognizing and addressing this potential adverse effect in vaccinated individuals.¹⁰ Myocarditis is the most common cardiac event after COVID-19 vaccination. Cardiac events have been documented after administration of Moderna and Pfizer-BioNTech mRNA vaccines, whereas myocarditis and TTC are relatively less common after immunization with a vector-based or inactivated vaccine. The rare occurrence of

Table 2: Common cardiovascular adverse events reported in VAERS.

CVS complication	Number of cases	Case per million vaccines
Myocarditis	2984	4.94
Pericarditis	2081	3.45
Thrombosis	5052	8.36
Thrombocytopenia	1195	1.98
Hypertension	8276	13.70
Arrhythmia	1343	2.22
Tachycardia	7517	12.45

thrombocytopenia after COVID-19 immunization and its potentially serious consequences highlight the need for healthcare providers to be vigilant in recognizing and addressing this potential adverse effect. Prompt intervention can be crucial in preventing severe complications.⁶ The occurrence of VIPIT after immunization with the AstraZeneca COVID-19 vaccine is rare, and only a small number of cases have been reported among millions of vaccinated individuals. Further investigations by regulatory agencies have indicated that the advantages of vaccination exceed the risks, given that COVID-19 poses a hazard to public health.⁹

Blood

Anemia

A 33-year-old woman developed severe anemia symptoms after immunization with a COVID-19 booster shot. She appeared well up until 1 day after immunization with the vaccine, but she subsequently began to feel ill with flu-like symptoms and experienced discomfort at the site of the injection. The patient took paracetamol for this discomfort, and 2 days after the vaccine, she experienced pallor, generalized weakness, and dizziness. She had a hemoglobin count of 52 g/L, hematocrit of 0.15, white blood cells of 5.0 sets of 65, lymphocytes of 0.24, monocytes of 0.06, and platelets of 165,000/ μ l, indicating severe anemia. After consultation with a hematologist, treatment with the oral steroid prednisone (1 mg/kg/day) was started. [Figure 4](#) differentiates between a normal and anemic person. The patient was advised to be hospitalized after 3 days, because her symptoms had progressed.⁴ Vaccine monitoring systems play a crucial role in ensuring the safety and efficacy of vaccines. However, rare and serious adverse effects have gone undetected in some instances. For example, in 1976, after receiving the

swine flu vaccine, a small percentage of recipients developed Guillain-Barré syndrome, a severe neurological disorder, which was not anticipated or detected by the monitoring systems in place at that time.⁷ The patient showed pale, sallow skin, a mildly yellowish eye, unusual paleness of the skin, and no enlargement of the liver or spleen upon physical examination. Laboratory tests showed hyperferritinemia, IgG and C3 positivity, high LDH, severe anemia, immature red blood cells, and the direct Coombs test. The patient's medical history included a diagnosis of AIHA in 2012, along with seven episodes of hemolysis over a period of 10 years. The final incident, which occurred in 2020 during her pregnancy, and was minor, with hemoglobin of 90 g/L, was responsive to oral steroid treatment. Since then, she had been in remission.¹⁰

Continual improvement and vigilance are needed to detect and address potential adverse events. Inactivated viral vaccination for COVID-19 did not have negative effects on the patient's blood cell counts, because her CBC results were within the normal range. Thus, vaccination did not appear to cause significant abnormalities in her blood composition. Additionally, her platelet counts were acceptable.¹³ These results are promising, particularly considering the potential concerns surrounding the use of steroids, which have been associated with various adverse effects. However, these results are specific to this individual and may not necessarily apply to all people receiving the same vaccination. Additional research and monitoring are necessary to fully understand the long-term effects of COVID-19 vaccines on blood cell counts and overall health.² A study on individuals who received COVID-19 vaccines has indicated a temporary decrease in white blood cell counts within the normal range, and no adverse health effects. However, another study on a different group of individuals who received the same COVID-19 vaccine has demonstrated a significant and prolonged decrease in red blood cell counts, thus leading to severe anemia and requiring medical

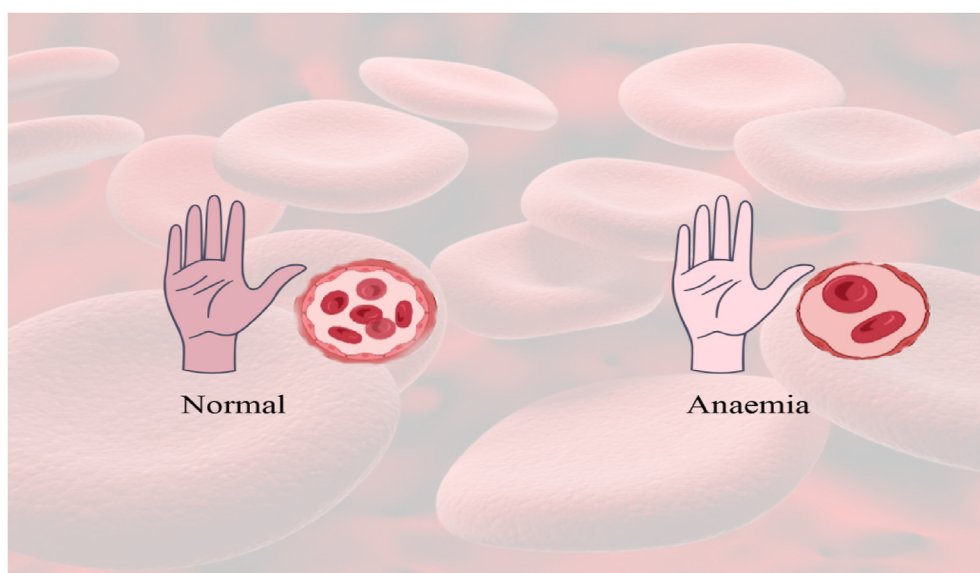


Figure 4: Difference between normal and anemic patients.

intervention. The affected individuals experienced persistent fatigue and weakness, thus indicating that the vaccine had detrimental effects on their overall health.¹⁵

Cerebral venous sinus thrombosis

A 54-year-old man with a history of phlebitis and issues with the saphenous vein was diagnosed with cerebral venous sinus thrombosis (CVST) after immunization with a single dose of the Johnson & Johnson COVID-19 vaccine. He experienced acute leg discomfort and was diagnosed with thrombosis of the large saphenous vein's anterolateral collateral, and was given an anticoagulant prescription. Blood examinations revealed thrombocytopenia, a platelet count of $36 \times 10^3/\text{mL}$, and an elevated D-dimer level at 63,830.⁸ The patient returned to the emergency department the following day because of lingering pain and a pricking sensation in the left upper limb and half of the face. His Glasgow Coma Scale (GCS) score was 15; his head CT and angiogram revealed thrombosis in the brain; and he had signs of CVST, such as chronic pain and a prickling feeling.¹² CVST is a rare condition characterized by the formation of blood clots in the veins that drain blood from the brain, thus leading to various symptoms, including headaches, visual disturbances, and neurological deficits that can be life-threatening and require immediate medical intervention. Diagnosis can improve the prognosis for individuals with CVST. In some rare cases, individuals with CVST experience delayed diagnosis and treatment because of vague and non-specific symptoms. The condition may progress undetected, thereby leading to irreversible neurological damage or death.¹⁶

Integumentary system

Vaccine-associated adverse effects, such as cutaneous reactions, are generally minor. The immune system creates systemic reactions, which are more frequent and severe and can cause symptoms. Well-tolerated reactions, such as inflammation and skin irritation at the injection site, are not specific and usually resolve. Common skin adverse effects after immunization with COVID-19 vaccines include local injection site reactions, urticaria, morbilliform reactions, erythromelalgia, herpes zoster lesions, chilblains, and burning foot sensations; moreover, rare cases of severe allergic reactions to COVID-19 vaccines, such as anaphylaxis, have been reported.¹⁰ These reactions can manifest symptoms beyond cutaneous effects, such as difficulty in breathing, swelling of the face and throat, and decreased blood pressure.¹⁷ Immediate medical attention is necessary to prevent further complications. Individuals must be aware of the potential risks and symptoms associated with severe allergic reactions to COVID-19 vaccines. Prompt recognition and treatment of these reactions can significantly decrease the risk of complications and ensure the safety of individuals receiving the vaccine.¹⁸ Healthcare providers should educate patients about these potential allergic reactions and emphasize the importance of seeking immediate medical attention if any concerning symptoms arise.¹⁹

Leukocytoclastic vasculitis

A 71-year-old woman experienced skin sores on her legs after immunization with the second dose of the Vaxzevria COVID-19 vaccine from AstraZeneca. Her skin lesions were identified as narrow small-vessel vasculitis.⁵ A dermatological examination revealed that the skin lesions vanished within one week of beginning oral prednisone at 20 mg/day. [Figure 5](#) provides information on the dermatologic examination in this patient. In addition to the potential risks and symptoms of severe allergic reactions to COVID-19 vaccines, individuals should be aware of the possibility of developing leukocytoclastic vasculitis, a condition involving inflammation of the blood vessels and causing symptoms such as rash, fever, and joint pain.⁷ Healthcare providers should educate patients about this potential complication and emphasize the importance of seeking immediate medical attention if any concerning symptoms arise after immunization with the vaccine. The benefits of vaccination in preventing severe illness and hospitalization far outweigh the potential risks. However, being aware of this complication and knowing what symptoms to watch for can help individuals seek prompt medical attention and receive appropriate treatment. For instance, people with symptoms such as a persistent rash, joint discomfort, and fever after COVID-19 vaccination should see a physician to receive a proper diagnosis and treatment.¹³ Delayed medical attention because of a lack of awareness or fear of adverse effects can lead to worsening conditions and poor recovery. Healthcare providers must educate patients about these potential complications and ensure that they receive appropriate treatment.¹⁶

Chilblain-like lesions

A 42-year-old man had erythematous to purple patches on his distal phalanges and nail beds, acrocyanosis, and sores that looked like chilblains. 12 days after receiving the first dose of Pfizer-BioNTech COVID-19, BNT162b2, the first dose, there were no signs of the lesion worsening or returning, a 46-year-old woman had a history of leukocytoclastic vasculitis, psoriatic arthritis, psoriasis, and irritable bowel syndrome, the second dose, the vasculitis lesions reappeared 2 days after, this time with worsening discomfort and anatomical distribution, starting topical and systemic corticosteroids, the patient became better without psoriasis; vaccine recipients who develop symptoms such as rash, joint pain, or fever should see a physician to rule out other causes and determine the best course of treatment.^{20,21} Delays in medical attention can lead to worsening conditions and longer recovery times. By educating patients about potential complications and ensuring that they receive the necessary care, healthcare providers can guide symptom management and recommend treatment options specific to each individual's condition. They can also track patients' responses to treatment and make course corrections as necessary. Patients with psoriasis can effectively manage their condition and improve their overall quality of life by working closely with healthcare professionals. For

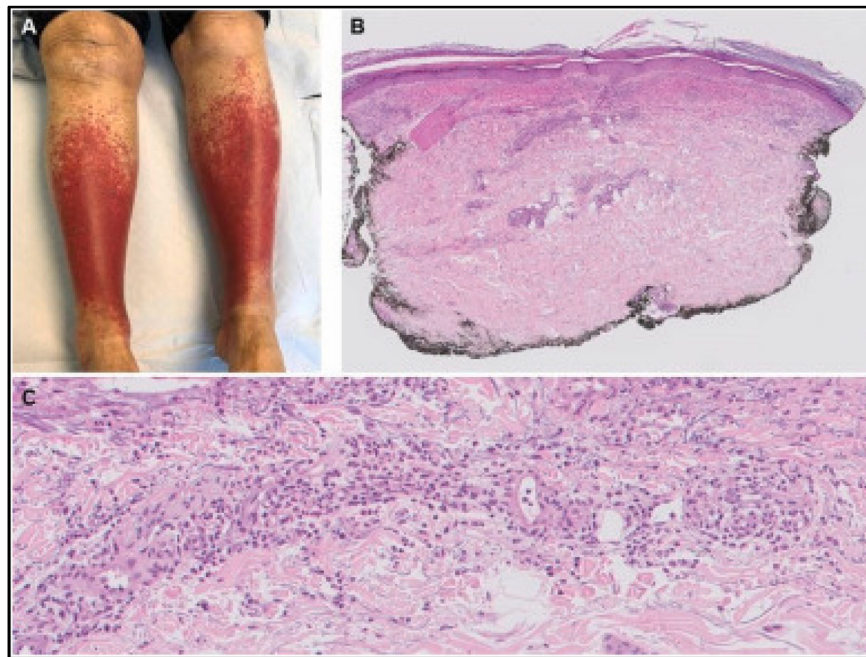


Figure 5: A. Dermatologic examination. B. Symmetrically distributed purpuric macules and papules on the lower legs. C. Histopathological examination (H&E stain) [19].

example, patients with psoriasis whose symptoms worsen during periods of high stress could develop stress-management techniques and adjust their treatment plans accordingly. However, not all individuals with psoriasis have access to healthcare professionals or can afford the necessary treatments. Policymakers and healthcare systems must address these barriers to ensure equal access to treatment and provide support for all individuals with psoriasis.²²

Herpes zoster

A 42-year-old healthcare worker experienced a unilateral dermatome papulovesicular herpes zoster lesion in the right hemithorax 2 days after immunization with the primary dose of the Pfizer-BioNTech vaccines. Within 7 days, full recovery with systemic acyclovir was observed, possibly because of vaccine-induced cell-mediated immune system dysregulation.¹⁴ Individuals with herpes zoster may experience worsened symptoms during high stress. Healthcare professionals and policymakers must recognize the effects of stress on herpes zoster, and provide support and treatment options for affected individuals. Removing financial and other obstacles to healthcare for all people is essential. Stress weakens the immune system, thus increasing susceptibility to outbreaks and lengthening the time required to recover from herpes zoster. Additionally, stress can exacerbate the pain and discomfort associated with herpes zoster, thus further diminishing quality of life in affected individuals.¹⁷ A pictorial representation of herpes zoster on the skin is shown in Figure 6.

Healthcare professionals and policymakers should take proactive measures to address the stress-associated implications of herpes zoster and provide comprehensive support to patients. Stress management techniques, such as cognitive

behavioral therapy or mindfulness meditation, can help patients cope with the emotional and psychological toll of herpes zoster. Policymakers should allocate resources to enhance access to mental health services and promote public awareness campaigns to decrease the stigma surrounding the condition.¹⁵ However, some patients may not respond well to these techniques, which may not address the underlying emotional trauma associated with herpes zoster. Allocating resources to mental health services may not be feasible in low-income communities or regions with limited healthcare infrastructure, thus leaving a substantial portion of affected individuals without the necessary support and care.²³

Pityriasis rosea

Four days after getting her primary COVID-19 vaccine, a 45-year-old female healthcare professional got histopathologically confirmed pityriasis rosea and lesions.²⁴ Lesions resolved within many weeks after her second dose of

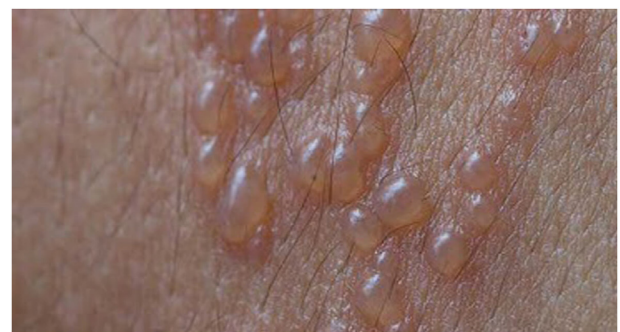

Figure 6: Herpes zoster on skin.

immunisation. A 64-year-old man experienced black erythematous to violaceous darkening of both large toes, which was present for 10 days with no other symptoms. Three days after immunization with the second Pfizer-BioNTech BNT162b2 vaccine dose lesions gradually appeared. Two weeks after immunization, with topical corticosteroid treatment, the discoloration remained the same, but improved after warming and restoration of nerve function in the legs.^{25,26–29} Various cutaneous reactions due to COVID-19 vaccines are listed in Table 3. Allocating resources to mental health services may not be feasible in low-income communities or regions with limited healthcare infrastructure; thus the burden of herpes zoster extends beyond the individual level and can also have substantial economic implications.²² The cost of treating complications and managing the long-term effects of the disease can be substantial, thus placing a strain on healthcare systems and potentially hindering healthcare access for people most in need of treatment. Therefore, a comprehensive approach that combines public awareness campaigns improved access to healthcare services, and targeted vaccination efforts is crucial to address the multifaceted challenges posed by herpes zoster.¹⁹ For example, in countries experiencing a rise in herpes zoster cases, healthcare systems may struggle to cope with the increased demand for treatments and the management of complications, thus prolonging waiting times for patients seeking medical attention, and potentially delaying necessary care and worsening outcomes.¹³ Public awareness campaigns can educate individuals regarding the importance of vaccination and early treatment, thereby decreasing the overall burden on healthcare systems and improving access to care for the people most in need.

Renal system

Mild adverse reactions to COVID-19 vaccines include discomfort and swelling at the injection site, urticaria rashes, fever, and headaches. More severe adverse reactions, such as neurological adverse effects, myocarditis, and autoimmune illnesses, have been documented after mass vaccination, and some patients require hospitalization.^{30,31} Additionally, children and adults have experienced newly diagnosed or

recurrent kidney diseases. Growing evidence linking COVID-19 vaccination to kidney disease has raised public concerns regarding potential adverse effects on the kidneys.^{32,33–35} The healthcare system is struggling to provide prompt care to all individuals suffering from immunoglobulin nephropathy, neutrophil cytoplasmic autoantibodies, vasculitis, and acute interstitial nephritis following COVID-19 vaccination. However, governmental support and funding for healthcare infrastructure and resources could help achieve better-equipped healthcare systems able to accommodate increased demand.³⁶ Investment in healthcare infrastructure and resources helps healthcare systems become better prepared to handle increased demand, thus ensuring sufficient healthcare professionals, medical supplies, and equipment, as well as efficient facilities. Additionally, government support and funding can help healthcare systems implement proactive measures, such as developing robust emergency response plans, and conducting regular training and simulations. These proactive steps can help healthcare systems mitigate the effects of crises or pandemics, and ensure that timely care is delivered to all patients, regardless of circumstances.³⁷ The various renal adverse effects of COVID-19 vaccines are described in Figure 7.

Minimal change disease

Minimal change disease (MCD) is the most common renal pathology reported after COVID-19 vaccination. MCD, or lipoid nephrosis, is a kidney disorder that can lead to nephrotic syndrome, with symptoms such as proteinuria, hypoalbuminemia, hypercholesterolemia, hypertriglyceridemia, and peripheral edema. MCD is most common in patients older than 40 years and shows a male predominance.³⁸ Most patients do not experience chronic illnesses, but some have experienced hypertension, diabetes, and dyslipidemia. Most patients report pain and swelling, and 97% respond positively to treatments. To effectively respond to crises or pandemics, such as MCD, healthcare systems require a combination of professionals, medical supplies, equipment, and efficient facilities. Governmental support and funding are crucial for implementing proactive measures, such as emergency response plans and regular training. Prioritization of research

Table 3: Cutaneous Adverse reaction of COVID 19 vaccine.

S.No	Author	Type of cutaneous reaction	Cause and recovery
1.	Busto-Leis et al. [²⁶].	2 patients were reported for Pityriasis Rosea.	It was developed 7 days after the second dose of the Pfizer-BioNTech vaccine.
2.	Jedlowski et al. [²⁷].	A 30yr old male healthcare professional reported for recurrent pruritic maculopapular rash	This developed 48 h after the 1st and 2nd doses of Pfizer-BioNTech vaccine. These rashes go away on its own after 24 h without any systemic treatment.
3.	Lopez-Valle et al. [²⁸].	A 27yr old female reported for COVID arm that was a poorly defined erythematous-oedematous plaque.	This occurred at the injection site due to mRNA vaccine with 1st and 2nd dose. This situation resolved up after two days followed by symptomatic treatment.
4.	Wei et al. [²⁹].	4 women were reported for COVID arm for several days.	This happened due to 1st dose of Moderna COVID-19 vaccine. The condition has been improved by treatment with topical steroids and oral antihistamines.

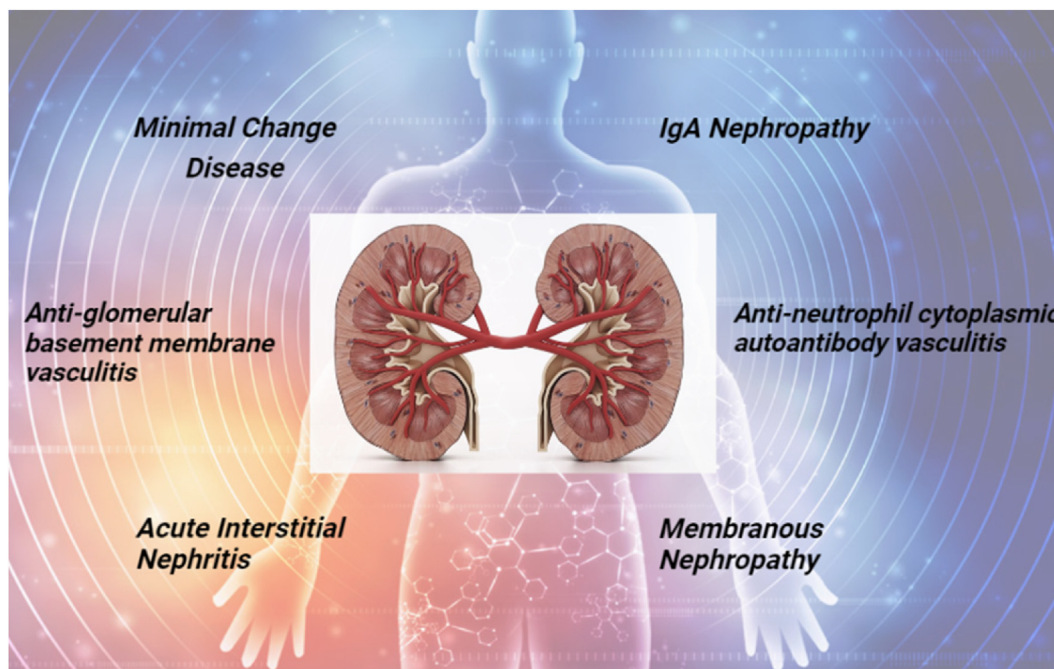


Figure 7: Renal effects of COVID-19 vaccines.

and development is essential for improving the understanding and treatment of diseases such as MCD, including investment in clinical trials and studies to identify new therapies and preventive measures. Collaboration among healthcare institutions, both nationally and internationally, can enhance resources and ultimately lead to better patient outcomes.²² During the COVID-19 pandemic, researchers collaborated in studying the virus and developing vaccines and treatments. International collaborations enabled countries to share resources, such as personal protective equipment, and medical expertise, with the goal of ensuring access to adequate healthcare for vulnerable populations. However, a stark disparity in global vaccination rates has occurred, with some countries fully vaccinating and others struggling to acquire sufficient doses.²⁷ Tensions arose among countries regarding the sharing of resources, and some countries prioritized their needs over international cooperation, thereby hindering efforts to provide adequate healthcare for all. Some countries argue that they must put the health and safety of their inhabitants first, and that expecting every country to distribute vaccines equally when their populations are at risk is unrealistic.

Immunoglobulin nephropathy

Renal complications are the second most frequent complication after mRNA vaccination for COVID-19. A 42-year-old woman in good health experienced visible blood (gross menorrhagia) and protein in her urine. Kidney problems were absent in her family.³⁹ After a 4-week break, she received her second dose of the mRNA vaccine, after which she experienced dark, reddish urine. Although the gross hemorrhage resolved after several days, the microscopic hemorrhage and proteinuria were still present in the follow-up urinalysis. The laboratory findings revealed a 24-h urine protein level of 1.7 g/day and a

serum creatinine level of 0.47 mg/dL. Mesangial hypercellularity,³² cellular glomerular crescents, segmental glomerulosclerosis, and end capillary proliferation were all observed under a light microscope. IgA nephropathy was confirmed by electron microscopy. After treatment with 50 mg of losartan, the patient's urine protein to creatinine content decreased to 0.7 mg/g. Moderna vaccines have been found to result in cases of gross hemorrhagic disease and the development of renal effects. Differences among countries regarding the sharing of resources, particularly in acquiring sufficient doses of vaccines, have hindered efforts to provide adequate healthcare to all.²⁶ Although some countries have argued that the health and well-being of their citizens should be prioritized, the global effects of unequal vaccine distribution must be considered. The issue of acquiring sufficient doses is only one example of the challenges faced in achieving equitable healthcare worldwide. Another challenge is the lack of infrastructure and resources in developing countries, which often results in inadequate healthcare systems. Without proper healthcare infrastructure, providing essential services such as vaccinations, maternal care, and disease prevention programs is difficult. Socioeconomic factors play a major role in determining access to healthcare, and marginalized communities are often those most affected.²⁴ These disparities not only perpetuate existing inequalities but also pose a threat to global health security. In many developing countries, limited funding and resources result in a lack of medical facilities and trained healthcare professionals, thus leading to long wait times, inadequate treatment options, and poor healthcare outcomes in the population. Marginalized communities, such as Indigenous groups or refugees, often face additional barriers, such as language barriers, cultural differences, and discrimination, which further limit their access to quality healthcare services. Addressing the substantial marginalization and disparities in healthcare access and

outcomes in the United States is a challenge. Policymakers and healthcare organizations must address these systemic issues and work toward creating a more equitable healthcare system for all individuals, regardless of their background or circumstances.³⁵ By implementing targeted interventions, increasing funding for community health centers, expanding health insurance coverage, and promoting diversity in the healthcare workforce, deficiencies can be addressed, thus ensuring that all people have access to high-quality care. Addressing the social determinants of health, such as poverty, education, and housing, is essential in creating a more equitable healthcare system.²⁷ Collaboration among healthcare providers, community organizations, and government agencies is crucial for achieving health equity.

Tubulointerstitial nephritis

A 44-year-old individual with type 2 diabetes mellitus and chronic hepatitis B was diagnosed with acute tubulointerstitial nephritis (ATIN) after immunization with the mRNA-1273 vaccine. His blood creatinine level increased to 4.94 mg/dL, and his azotemia and serum creatinine levels were elevated 1 week after vaccination.⁴⁰ A biopsy of the kidneys revealed extensive infiltration of inflammatory cells into the interstitium and tubular epithelium. Six weeks after the start of treatment for ATIN with high-dose prednisolone (60 mg/day), his urine protein to creatinine ratio was 0.3 g/g, and his serum creatinine level had decreased to 1.89 mg/dL.^{41,42} Figure 8 depicts the observations of tubulointerstitial nephritis. Adopting a more equitable healthcare system involves addressing social determinants of health and promoting diversity in the healthcare workforce. Expanding health insurance coverage and establishing community health centers can ensure that all individuals receive high-quality care. Collaboration among healthcare providers, community organizations, and government agencies is crucial for achieving health equity.⁴³ These partnerships can help identify and address the specific needs of underserved populations, such as those with limited access to healthcare resources or those who face discrimination and bias in the healthcare system. Promoting diversity in the healthcare workforce is essential for reducing healthcare disparities and improving patient outcomes.⁴⁴ By increasing the representation of marginalized communities in healthcare professions, cultural competency can be enhanced, and

healthcare providers can be better equipped to understand and meet the unique needs of diverse patient populations, thus enabling more effective communication, trust, and ultimately better health outcomes for all individuals. However, recruiting healthcare professionals solely on the basis of their cultural background may overlook other qualifications and skills necessary to providing quality care. In such cases, hospitals could compromise on the expertise and experience required for certain specialized medical treatments or procedures. Additionally, relying solely on healthcare providers from underrepresented communities may perpetuate stereotypes and reinforce the notion that individuals from these communities can provide only culturally sensitive care rather than excelling in all areas of healthcare.⁴⁵ ATIN can result from an allergic reaction to a vaccine or medication. T lymphocytes mediate an abnormal innate and subsequently acquired immune response resulting in the development of ATIN. Many components of the COVID-19 vaccines used to prevent infections are immunogenic agents that can evoke immune responses similar to hypersensitivity. In conclusion, having healthcare providers from diverse backgrounds who can provide culturally sensitive care is critical; however, relying solely on these individuals may compromise the expertise and experience required for specialized medical treatments. Diversifying the healthcare workforce can enhance medical research, innovation, and the overall quality of healthcare delivery. Creating opportunities and support systems to ensure equal access to education and training in healthcare fields can foster a truly inclusive and equitable healthcare system.⁴⁶

Nervous system

The COVID-19 pandemic has led to various adverse effects, including fever, tiredness, muscle aches, and neurological symptoms (e.g., cerebral venous sinus thrombosis, Guillain-Barré syndrome, and CNS demyelination problems). Diversifying the healthcare workforce to provide culturally sensitive care is essential, but hiring solely to achieve a diverse workforce may compromise the expertise needed for specialized medical treatments.³⁶ Diversifying the healthcare workforce can enhance medical research, innovation, and the overall quality of healthcare delivery. Creating opportunities and support systems to ensure equal access to education and training in

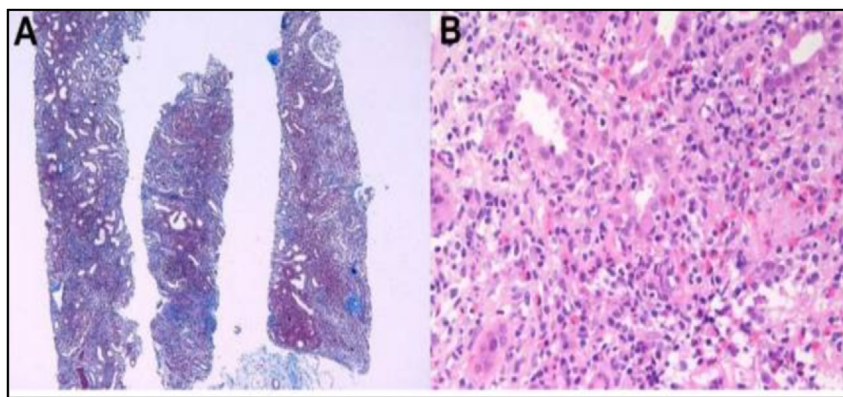


Figure 8: Pathologic findings of acute tubulointerstitial nephritis [⁴¹]. (A) Massive interstitial inflammatory infiltrates with fibrosis. (B) Mixed inflammatory cells infiltrating the tubular epithelium (tubulitis) and interstitium.

healthcare fields can contribute to a truly inclusive and equitable healthcare system. However, diversity alone cannot ensure expert knowledge of specific medical treatments. Prioritizing the acquisition and honing of specialized skills requires a balance between diversity and expertise, wherein individuals from diverse backgrounds have equal opportunities to receive the necessary education and training in their chosen healthcare fields.⁸ In hospital settings, a diverse team of healthcare professionals is crucial to cater to the specific needs of different patient populations; this team should include physicians and nurses who can effectively communicate with patients from diverse cultural backgrounds, and specialists with expertise in geriatrics or pediatrics. By combining diversity and expertise, healthcare organizations can provide comprehensive and inclusive care.³ However, healthcare facilities that lack staff diversity may struggle to communicate with patients speaking various languages and those with various cultural backgrounds, thus leading to miscommunication, misunderstanding, and inadequate care. Additionally, patients in need of specialized care may not receive appropriate treatment and attention, thus leading to subpar healthcare outcomes.

Acute disseminated encephalomyelitis

Acute disseminated encephalomyelitis (ADEM), a severe autoimmune disease affecting young individuals, results in rapid and unexpected degeneration of the protective covering around the nerve fibers in the brain and spinal cord,

known as the myelin sheath. ADEM tends to occur after immunization and subsequent infection with bacteria or viruses. Multiple studies have reported ADEM after SARS-CoV-2 infection.^{47,48} Numerous case reports and series have indicated a substantial link between ADEM and COVID-19 vaccination. People 44–60 years of age have been reported to have ADEM.^{47,48} There were 60 women and 40 men in total. Vaccines from AstraZeneca, Pfizer (BioNTech), Moderna, Sin Pharma, Sputnik, Sino Vac, Vero Cells, and Covaxin were used, including AstraZeneca, Pfizer (BioNTech), Moderna, Sin Pharma, Sputnik, Sino Vac, Vero Cells, and Covaxin. After the first vaccination, ADEM developed in 80% of patients, and after the second vaccination, it developed in 20%. The median period after immunization in which neurological clinical symptoms appear is 14 days but varies widely.^{49–51} Fifty-nine people complained of a variety of symptoms, including fatigue, unconsciousness, urinary complaints, vision problems, and seizures. Serological tests confirmed the diagnosis. Plasma-pheresis and glucocorticoid injections were part of the treatment plan. The clinical condition of 80% of these individuals improved.^{50,51} Adverse events associated with ADEM are shown in Figure 9 for men and women.

Hyponatremia

Hyponatremia can be caused by a variety of conditions, including chronic hypophysitis and the syndrome of inappropriate antidiuretic hormone, and can result in problems

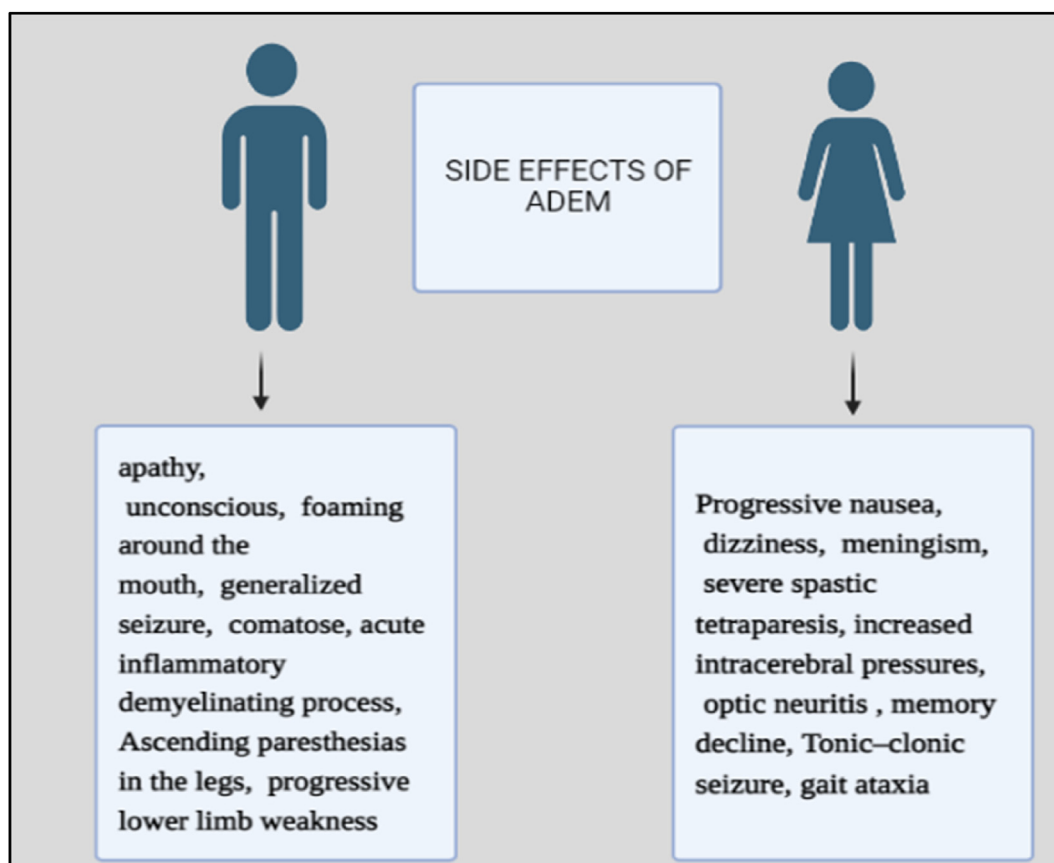


Figure 9: ADEM side effects among males and females.

such as coma, convulsions, and even death.⁵² A 48-year-old woman with severe headaches and depression experienced a low GCS score and acute right lateral gaze paralysis after immunization with the second dose of the Pfizer COVID-19 vaccine. ADEM can cause a wide range of neurological clinical symptoms, with a median onset of 14 days after vaccination. Treatment typically involves plasmapheresis and glucocorticoid administration, and 80% of patients show improvement after these treatments.⁵³ However, ADEM is a rare condition with an estimated incidence of 0.1–0.8 cases per 100,000 individuals. The exact cause of ADEM remains unclear, but it is believed to be an autoimmune response triggered by a viral or bacterial infection or, in some cases, by vaccination. Further research is necessary to better understand the risk factors and underlying mechanisms of ADEM. For example, a 10-year-old boy was diagnosed with ADEM after experiencing flu-like symptoms; after intravenous immunoglobulin therapy and high-dose corticosteroids, his neurological symptoms significantly improved within several weeks. However, a 30-year-old woman's neurological symptoms showed no improvement over several months, thus raising concerns regarding the effectiveness of these treatments in managing ADEM in older patients.⁵⁴

A 30-year-old woman was diagnosed with ADEM after experiencing flu-like symptoms and receiving extensive treatment for meningoencephalitis, including benzylpenicillin and acyclovir. In the intensive care unit, her GCS score decreased to 10, she developed polyuria, and her serum sodium was rapidly corrected to 127 mmol/L 4 h after her first presentation. Her IV fluid therapy was modified to include 5% dextrose in proportion to the previous hour's urine output plus 50 mL/h. Seven hours after presentation, her serum sodium continued to increase to 137 mmol/L. The lack of improvement in her symptoms might have been due to factors other than treatment effectiveness, such as underlying health conditions or her individual response to medication.⁴² Further research is needed to explore these possibilities and determine the most appropriate treatment approach for older patients with ADEM. Additionally, studies should aim to identify potential risk factors or triggers for the condition in older patients and any specific clinical features that may differentiate subtypes of ADEM. Understanding these factors could lead to more personalized and effective treatment strategies, thus ultimately improving outcomes for older individuals with ADEM.⁵⁵ In conclusion, further research and understanding of ADEM in older patients will be crucial in improving outcomes and tailoring treatment plans.⁵⁵ By considering factors such as comorbidities and individual differences in treatment response, healthcare professionals can tailor treatment plans for older individuals with ADEM.

Memory loss

The COVID-19 vaccine has been found to lead to cognitive deficits and memory loss in older individuals with Alzheimer's disease. A 65-year-old man who received his first

dose of Covishield experienced acute memory loss 6 days after immunization with the vaccine. He showed no neurological symptoms and had nonfluent speech.⁵⁶ Because a CT scan did not reveal hemorrhage, his vaccine-associated cognitive and memory issues were considered likely to have a cerebrovascular cause. After 24 h, the patient made a full recovery. Understanding the factors contributing to memory loss in older individuals with Alzheimer's disease is crucial for developing personalized and effective treatment strategies. Healthcare professionals must consider comorbidities and individual differences in treatment response to tailor treatment plans and improve outcomes. Because comorbidities can exacerbate memory loss and affect treatment outcomes, healthcare professionals must carefully evaluate and manage these comorbidities. Additionally, understanding individual differences in treatment response is crucial, because each patient may respond differently to various treatment approaches. Healthcare practitioners can work with dialectologists to successfully regulate blood sugar levels in order to better assist memory loss in older persons, as changes in glucose can influence cognitive performance.³⁹ Additionally, understanding that some medications commonly used to treat memory loss may have adverse effects on individuals with certain comorbidities can aid in preventing potential complications and improving treatment outcomes. However, not all older adults with memory loss will have diabetes or require collaboration with a dialectologist.²⁷ Many cases of memory loss in older adults are unrelated to diabetes or any other comorbidity and can be managed without such interventions. Further research and understanding in this area are crucial for optimizing care for older patients with Alzheimer's disease.

Idiopathic facial paralysis

Bell's palsy, also called idiopathic facial paralysis or acute peripheral facial palsy, is a temporary paralysis of the facial muscles caused by swelling of the facial nerve (the seventh cranial nerve). This nerve gives feeling to the front two-thirds of the tongue and parasympathetic innervation to the lacrimal and salivary glands.⁵⁷ This condition often results in rigid faces, difficulty in expressing emotions, difficulty in closing one eye, excess salivation, watery eyes, and a loss of taste sensation in the front two-thirds of the tongue (ageusia). Vaccination has been found to increase the risk of Bell's palsy, and COVID-19 immunization has been reported to cause 19,529 neurological adverse effects, including facial paralysis.⁵⁸ Patients have experienced facial paralysis after immunization with the Oxford-AstraZeneca, Pfizer, Moderna, Sputnik V, and Johnson & Johnson COVID-19 vaccines. Bell's palsy has been studied with CSF, MRI, and CT scans by physicians.⁵⁹ The data in Table 4 present the symptoms of facial paralysis. By exploring the underlying mechanisms and risk factors associated with memory loss, healthcare professionals can develop more targeted interventions and treatment plans. Studies are investigating potential pharmacological and non-pharmacological interventions that may slow the progression of memory loss and

Table 4: Symptoms of facial palsy with respect to different vaccines.

S.No	Author	COVID vaccine name	Symptoms of facial palsy
1.	Colella et al.	Pfizer-BioNTech	Left facial drooping, defective closure of eyelids, and moderate labial hypo mobility, together with skin that has flattened out on the forehead.
2.	Martin-Villares et al.	Moderna COVID-19 Vaccine	Right facial pain
3.	Maramattom et al.	Oxford-AstraZeneca	Facial and tongue numbness, Bilateral facial palsy, and dysphagia
4.	Allen et al.	Oxford-AstraZeneca	Bifacial weakness, dysarthria
5.	Burrows et al.	Pfizer-BioNTech	right facial weakness
6.	Rossetti et al.	J&J/Janssen COVID-19 vaccine	facial weakness, paraesthesia, tingling, Difficulty in drinking.
7.	Yu et al.	Sinovac	facial weakness, drooping, eye discomfort, Wrinkles.
8.	Ish et al.	Covaxin	Difficulty in closing Right eyelid along with redness and Watering in the eyes.
9.	Karimi et al.	Sputnik V	Bilateral facial numbness and weakness

improve cognitive function in older adults. These efforts will be crucial in providing better care and support for individuals experiencing memory loss, thus ultimately enhancing their overall quality of life.⁶⁰ A study conducted in older adults with mild cognitive impairment has found that engaging in regular physical exercise, such as walking or swimming, is associated with a slowed rate of memory decline over time. These findings highlight the importance of incorporating exercise interventions into treatment plans for memory loss. Other non-pharmacological interventions that can be explored for individuals with health conditions or physical limitations include cognitive training exercises and mindfulness practices.

Muscular system

The COVID-19 pandemic has caused millions of deaths worldwide, and more than 10 billion doses of vaccine have been administered. Pfizer-BioNTech and Moderna are two widely used mRNA vaccines whose safety and efficacy have been confirmed in clinical studies. However, underlying medical issues, genetic predisposition, and individual differences in responsiveness to exercise and nutritional changes may all have an impact on the success of these interventions.⁶¹ In some cases, individuals with chronic illnesses or physical limitations may not be able to engage in vigorous aerobic exercise and may need to explore alternative forms of physical activity. For example, people with celiac disease who cannot consume gluten may need to carefully plan their diets to ensure that they obtain all essential nutrients for brain function. They may also need to incorporate alternative sources of nutrients, such as fortified gluten-free products or supplements, to support their cognitive health. Genetic factors can also play a role in how individuals respond to lifestyle interventions.⁵ Some individuals may have genetic variations that affect their ability to absorb or use certain nutrients efficiently. However, in some instances, individuals with genetic

variations can maintain optimal brain function without carefully planning their diet or incorporating alternative sources. The human body's ability to adapt and compensate for deficiencies suggests that carefully planning diets or incorporating alternative sources may not always be necessary for optimal brain function.⁸ Importantly, genetic variations are only one among many factors that influence nutrient absorption and utilization. Other factors, such as overall health, lifestyle choices, and environmental factors, also significantly determine an individual's ability to maintain optimal brain function. Therefore, a holistic approach is necessary in addressing nutritional needs for optimal brain health.

Rhabdomyolysis

The Pfizer-COVID-19 BioNTech mRNA vaccine has been associated with rhabdomyolysis, a muscle injury disorder that causes myoglobinuria, electrolyte imbalances, and acute kidney injury. Rhabdomyolysis is a well-known clinical disorder involving muscle injury. In some cases, the severity and localization of rhabdomyolysis can be evaluated with MRI. Rhabdomyolysis is characterized by myoglobinuria, electrolyte abnormalities, and often acute kidney injury.⁶² A 76-year-old Japanese woman with hyperlipidemia was given her third dose of Pfizer-BioNTech COVID-19 vaccine in her left upper arm and reported to the hospital with myalgia 2 days later. One day after vaccination, she began to experience myalgia in both her upper limbs and her left leg, and her left leg was affected more severely. She was unable to walk without assistance.⁶³ A holistic approach is essential in addressing nutritional needs for optimal brain health. [Table 5](#) describes the laboratory findings of patients with rhabdomyolysis.

Genetic variations, age, sex, medical conditions, lifestyle choices, and environmental factors play major roles in influencing nutrient absorption and utilization. Lifestyle choices,

Table 5: Laboratory finding of patient with rhabdomyolysis.

Parameter	Normal range	Day 1	Day 2	Day 3	Day 4	Day 5	Day 8	Day 10
CK	<190 U/L	9816	5416	–	1630	–	164	101
Myoglobin	23–72 ng/mL	1802	559	–	106	–	52	44
IL-6	≤4.0 pg/mL	–	11.9	–	2.6	2.4	–	1.9
IL-1β	≤10 pg/mL	–	≤10	–	≤10	≤10	–	≤10
TNF-α	0.75–1.66 pg/mL	–	0.59	–	0.99	0.78	–	0.89

such as a poor diet or excessive alcohol consumption, can further exacerbate nutrient deficiencies and hinder optimal brain health. Environmental factors, such as pollution and exposure to toxins, can also contribute to cognitive decline and nutrient imbalances. For example, a person with celiac disease may experience cognitive decline because of other factors, such as underlying neurological conditions, e.g., multiple sclerosis or Alzheimer's disease.⁶⁴ Although maintaining a gluten-free diet can be beneficial for individuals with celiac disease, it may not be sufficient to fully preserve optimal cognitive function in certain cases. Further research is necessary to understand the complex relationships among diet, neurological conditions, and cognitive ability. A combination of dietary interventions, medication, and targeted therapies may be necessary to effectively manage cognitive decline. Healthcare professionals should closely monitor and assess the effects of dietary changes on overall health and cognitive function in individuals with underlying neurological conditions. The goals of treating rhabdomyolysis are to keep patients hydrated and prevent acute kidney injury. Patients with rhabdomyolysis should first have the underlying cause determined and treated. Continuous assessment of the airway, breathing, and circulation; frequent examinations; appropriate hydration to improve end-organ perfusion; close monitoring of urine output; correction of electrolyte abnormalities; identification of complications such as compartment syndrome; and disseminated intravascular coagulation should all be included in the management of rhabdomyolysis.⁶⁵ In severe cases of rhabdomyolysis, renal replacement therapy may be necessary to support kidney function and remove toxins from the bloodstream. Close collaboration with a multidisciplinary team including nephrologists, critical care specialists, and physical therapists can optimize patient outcomes and facilitate rehabilitation efforts.

Conclusion

The COVID-19 pandemic has led to a significant increase in vaccine reactogenicity, and most people experience adverse reactions after immunization. A survey has found that 65% of participants experience adverse reactions, whereas only several studies have reported severe effects, such as myocarditis, pericarditis, and anemia. Individuals with a history of SARS-CoV-2 infection have stronger vaccination reactogenicity than those without such history. More than 95% of individuals had moderate and self-limiting side effects, with only 5% requiring medical evaluation and hospitalisation. Most reported adverse effects were minor and required either no therapy or care at home. Younger people, women, and those with comorbid conditions are relatively more likely to experience negative, potentially systemic, adverse effects after

immunization with an inactivated vaccine. Most reported adverse effects are minor, and very few deaths have been reported. Despite the risks, vaccination remains the most efficient method for fighting the pandemic's broad effects. The benefits of vaccination extend beyond individual protection, because widespread immunization contributes to herd immunity and prevents the virus's spread. Healthcare professionals closely monitor and assess vaccine safety and efficacy to ensure continued vaccination in combating the COVID-19 pandemic.

Source of funding

This research did not receive any specific grant from funding agencies in the public, commercial, or not-for-profit sectors.

Conflicts of interest

The authors declare that there is no conflict of interest.

Ethical approval

This study does not require ethical approval.

Authors' contributions

HY wrote the manuscript. MD created all the figures. KE edited the manuscript. All authors have critically reviewed and approved the final draft and are responsible for the content and similarity index of the manuscript.

References

1. Nagy A, Alhatlani B. An overview of current COVID-19 vaccine platforms. *Comput Struct Biotechnol J* 2021; 19: 2508–2517.
2. Finsterer J. Neurological side effects of SARS-CoV-2 vaccinations. *Acta Neurol Scand* 2022; 145(1): 5–9.
3. Gorzalski AJ, Tian H, Laverdure C, Morzunov S, Verma SC, VanHooser S, et al. High-Throughput Transcription-mediated amplification on the Hologic Panther is a highly sensitive method of detection for SARS-CoV-2. *J Clin Virol* 2020; 129: 104501.
4. Amanat F, Krammer F. SARS-CoV-2 vaccines: status report. *Immunity* 2020; 52(4): 583–589.
5. Deb B, Shah H, Goel S. Current global vaccine and drug efforts against COVID-19: pros and cons of bypassing animal trials. *J Biosci* 2020; 45: 82.
6. Le TT, Andreadakis Z, Kumar A, Román RG, Tollefsen S, Saville M, et al. The COVID-19 vaccine development landscape. *Nat Rev Drug Discov* 2020; 19: 305–306.

7. Baden LR, Sahly HME, Essink B, Kotloff K, Frey S, Novak R, et al. Efficacy and safety of the mRNA-1273 SARS-CoV-2 vaccine. *N J Med* **2021**; 384: 403–416.
8. Ghiasi N, Valizadeh R, Arabsorkhi M, Hoseyni TS, Esfandiari K, Sadighpour T, Jahantigh HR. Efficacy and side effects of Sputnik V, Sinophar and AstraZeneca vaccines to stop COVID-19; a review and discussion. *Immunopathologia P* **2021**; 7(2): 31.
9. Huang Z, Su Y, Zhang T, Xia N. A review of the safety and efficacy of current COVID-19 vaccines. *Front Med* **2022**; 16(1): 39–55.
10. Li Yiran E, Wang Shuyi, Reiter Russel J, Ren Jun. Clinical cardiovascular emergencies and the cellular basis of COVID-19 vaccination: from dream to reality. *Int J Infect Dis* **2022**; 124: 1–10.
11. Azir M, Inman B, Webb J, Tannenbaum L. STEMI mimic: focal myocarditis in an adolescent patient after mRNA COVID-19 vaccine. *J Emerg Med* **2021**; 61(6): e129–e132.
12. Angeli Fabio, Reboldi Gianpaolo, Trapasso Monica, Zappa Martina, Spanevello Antonio, Verdecchia Paolo. COVID-19, vaccines and deficiency of ACE2 and other angiotensinases. Closing the loop on the "Spike effect. *Eur J Intern Med* **2022**; 103: 23–28.
13. Arman S, Yasmeen C, Mirsadra M, Dishang B. A rare case of COVID-19 vaccine-induced myopericarditis in a young adult. *Radio Case Rep* **2022**; 17(6): 1916–1920.
14. Yiran EL, Shuyi W, Russel JR, Jun R. Clinical cardiovascular emergencies and the cellular basis of COVID-19 vaccination: from dream to reality. *Int J Infect Dis* **2022**; 124: 1–10.
15. Flordeluna Z Mesina. Severe relapsed autoimmune hemolytic anemia after booster with mRNA-1273 COVID-19 vaccine. *Hematol Trans Cell Therapy* **2022**; 30: 1–4.
16. Mele Federica, Tafuri Silvio, Stefanizzi Pasquale, Amati Antonio D, Calvano Mariagrazia, Leonardelli Mirko, Macorano Enrica, Duma Stefano, De Gabriele Giovanni, Introna Francesco, De Donno Antonio. Cerebral venous sinus thrombosis after COVID-19 vaccination and congenital deficiency of coagulation factors: is there a correlation. *Hum Vaccines & Immunotherapeutic* **2022**; 18:e2095166.
17. Rosenblatt AE, Stein SL. Cutaneous reactions to vaccinations. *Clin Dermatol* **2015**; 33: 327–332.
18. McMahon DE, Kovarik CL, Damsky W, Rosenbach M, Lipoff JB, Tyagi A, Chamberlin G, Fathy R, Nazarian RM, Desai SR, Lim HW, Thiers BH, Hruza GJ, French LE, Blumenthal K, Fox LP, Freeman EE. Clinical and pathologic correlation of cutaneous COVID-19 vaccine reactions including V-REPP: a registry based study. *J Am Acad Dermatol* **2022**; 86(1): 113–121.
19. Fiorillo a b G, Pancetti b c S, Cortese a b A, Toso a b F, Manara c S, Costanzo a d A, Borroni RG. Leukocytoclastic vasculitis (cutaneous small-vessel vasculitis) after COVID-19 vaccination. *J Autoimmun* **2022**; 127:102783.
20. Pileri A, Guglielmo A, Raone B, Patrizi A. Chilblain lesions after COVID-19 mRNA vaccine. *Br J Del* **2021**; 185(1): e3.
21. Lopez S, Vakharia P, Vandergriff T, Freeman EE, Vasquez R. Pernio after COVID-19 vaccination. *Br J De* **2021**; 185(2): 445–447.
22. Russo R, Cozzani E, Micalizzi C, Parodi A. Chilblain-like Lesions after COVID-19 Vaccination: A Case Series. *Acta Derma Venereologica* **2022**; 102: 00711.
23. Cohen SR, Prussick L, Kahn JS, Gao DX, Radfar A, Rosmarin D. Leukocytoclastic vasculitis flare following the COVID-19 vaccine. *Int J* **2021**; 60(8): 1032–1033.
24. Burlando M, Russo R, Cozzani E, Parodi A. COVID-19 "second wave" and vaccines: the dermatologists' perspective. *Int J* **2021**; 60: 889–890.
25. Akdaş E, İter N, Öğüt B, Erdem Ö. Pityriasis rosea following CoronaVac COVID-19 vaccination: a case report. *J Eur Acad Dermatol Venereol* **2021**; 35(8): e491–e493.
26. Busto-Leis JM, Servera-Negre G, Mayor-Ibarguren A, E Sendagorta C, Feito RM, González AN, et al. Pityriasis rosea, COVID-19 and vaccination: new keys to understand an old acquaintance. *J Eur A Der Ve* **2021**; 35(8): e489–e491.
27. Jedlowski PM, Jedlowski MF. Morbilliform rash after administration of Pfizer-BioNTech COVID-19 mRNA vaccine. *Dermatol Online J* **2021**; 27(1): 1–3.
28. López-Valle A, Falkenhain-López D, Arranz CR. Cutaneous reaction to BNT162b2 mRNA COVID-19 vaccine. *Int J* **2021**; 60(7): 891–892.
29. Wei N, Fishman M, Wattenberg D, Gordon M, Lebwohl M. "COVID arm": a reaction to the Moderna vaccine. *JAAD Case Rep* **2021**; 10: 92–95.
30. Liu Y, Ye Q. Safety and efficacy of the common vaccines against COVID-19. *Vaccines* **2022**; 10: 513.
31. McMahon DE, Amerson E, Rosenbach M, Lipoff JB, Moustafa D, Tyagi A, Desai SR, French LE, Lim HW, Thiers BH, et al. Cutaneous reactions reported after Moderna and Pfizer COVID-19 vaccination: a registry-based study of 414 cases. *J Amino Acids* **2021**; 85: 46–55.
32. Finsterer J, Scorza FA. Neurological Side Effects of SARS-CoV-2 Vaccinations are Not Uncommon but Frequently Ignored. *Neuropsychiatric Dis and Treat* **2022**; 18: 1273–1275.
33. Salah HM, Mehta JL. COVID-19 vaccine and myocarditis. *Am J Cardiol* **2021**; 157: 146–148.
34. Chen Y, Xu Z, Wang P, Li XM, Shuai ZW, Ye DQ, Pan HF. New-onset autoimmune phenomena post-COVID-19 vaccination. *Immunology* **2022**; 165: 386–401.
35. Wu HHL, Kalra PA, Chinnadurai R. New-onset and relapsed kidney histopathology following COVID-19 vaccination: a systematic review. *Vaccine* **2021**; 9: 1252.
36. Li Y, Rao M, Xu G. New-onset acute kidney disease post COVID-19 vaccination. *Vaccine* **2022**; 10: 742.
37. Ma Y, Xu G. New-onset IgA nephropathy following COVID-19 vaccination. *Int J Med* **2023**; 116: 26–39.
38. Agati VDD, Kudose S, Bomback AS, Adamidis A, Tartini A. Minimal change disease and acute kidney injury following the Pfizer-BioNTech COVID-19 vaccine. *Kidney Int* **2021**; 100: 461–463.
39. Pilishvili T, Gierke R, Fleming DKE, Farrar JL, Mohr NM, Talan DA, Krishnadasan A, Harland KK, Smithline HA, Hou PC, et al. Effectiveness of mRNA Covid-19 vaccine among U.S. Health care personnel. *N Engl J Med* **2021**; 385: e90.
40. Klomjit N, Alexander MP, Fervenza FC, Zoghby Z, Garg A, Hogan MC, Nasr SH, Minshar MA, Zand L. COVID-19 vaccination and glomerulonephritis. *Kid Int Rep* **2021**; 6: 2969–2978.
41. Jeong HL, Kim MS, Yong JK, Han MH, Jung HY, Choi JY, Cho JH, Kim CD, Kim YH, Park SH. New-onset kidney diseases after COVID-19 vaccination: a case series. *Vaccine* **2022**; 10(2): 302.
42. Mira FS, Costa CJ, Almeida PA, Pimenta AC, Alen CI, Figueiredo C, Rodrigues L, Sousa V, Ferreira E, Pinto H, et al. A case of acute interstitial nephritis after two doses of the BNT162b2 SARS-CoV-2 vaccine. *Int J Nephrol Renovascular Dis* **2021**; 14: 421–426.
43. Koda R, Watanabe H, Tsuchida M, Iino N, Suzuki K, Hasegawa G, Imai N, Narita I. Immune checkpoint inhibitor (nivolumab)-associated kidney injury and the importance of recognizing concomitant medications known to cause acute tubulointerstitial nephritis: a case report. *BMC Nephrol* **2018**; 19: 48.
44. Kawamata M, Akimoto T, Sugase T, Otani TN, Miki T, Masuda T, Kobayashi T, Takeda S, Muto S, Nagata D. Tubulointerstitial nephritis and uveitis syndrome: are drugs offenders or bystanders? *Clin Med Insights Case Rep* **2016**; 9: 21–24.

45. Segal Y, Shoenfeld Y. Vaccine-induced autoimmunity: the role of molecular mimicry and immune crossreaction. **Cell Mol Immunol** 2018; 15: 586–594.
46. Caso F, Costa L, Ruscitti P, Navarini L, Del Puente A, Giacomelli R, Scarpa R. Could Sars-coronavirus-2 trigger autoimmunity and/or autoinflammatory mechanisms in genetically predisposed subjects. **Autoimmun Rev** 2020; 19:102524.
47. Maramattom BV, Lotlikar RS, Sukumaran S. Central nervous system adverse events after ChAdOx1 vaccination. **New Sci** 2022; 43(6): 3503–3507.
48. Pohl D, Alper G, Van HK, Kornberg AJ, Lucchinetti CF, Tenenbaum S, et al. Acute disseminated encephalomyelitis: updates on an inflammatory CNS syndrome. **Neurology** 2016; 87: S38–S45.
49. Tenenbaum S, Chitnis T, Ness J, Hahn JS. Acute disseminated encephalomyelitis. **Neurology** 2007; 68: S23–S36.
50. Wang Y, Wang Y, Huo L, Li Q, Chen J, Wang H. SARS-CoV-2-associated acute disseminated encephalomyelitis: a systematic review of the literature. **J Ne** 2022; 269: 1071–1092.
51. Yazdanpanah F, Iranpour P, Haseli S, Poursadeghfard M, Yarmahmoodi F. Acute disseminated encephalomyelitis (ADEM) after SARS-CoV-2 vaccination: a case report. **Radio Case Rep** 2022; 17: 1789–1793.
52. DeCarvalho H, Letellier T, Karakachoff M, Desvaux G, Caillon H, Papuchon E, et al. Hyponatremia is associated with poor outcome in COVID-19. **J Nephrol** 2021; 34: 991–998.
53. Gankam KF, Decaux G. Hyponatremia and the brain. **Kidney Int Rep** 2018; 3: 24–35.
54. Lindner G, Ryser B. The syndrome of inappropriate anti-diuresis after vaccination against COVID-19: case report. **BMC Infect Dis** 2021; 21: 1000.
55. Blauenfeldt RA, Kristensen SR, Ernstsens SL, Kristensen CCH, Simonsen CZ, Hvas AM. Thrombocytopenia with acute ischemic stroke and bleeding in a patient newly vaccinated with an adenoviral vector-based COVID-19 vaccine. **J Thromb Haemostasis** 2021; 19(7): 1771–1775.
56. Chaurasia Bipin, Chavda Vishal, Lu Bingwei, Garg Kanwaljeet, Montemurro Nicola. Cognitive deficits and memory impairments after COVID-19 (Covishield) vaccination. **Brain Be Immunity Health** 2022; 22:100463.
57. Mehta PR, Apap MS, Bengner M, Stanton BR, Czuprynska J, Arya R, Sztrihai LK. Cerebral venous sinus thrombosis and thrombocytopenia after COVID-19 vaccination - a report of two UK cases. **Brain Behav Immun** 2021; 95: 514–517.
58. Malik B, Kalantary A, Rikabi K, Kunadi A. Pulmonary embolism, transient ischaemic attack and thrombocytopenia after the Johnson & Johnson COVID-19 vaccine. **BMJ Case Rep** 2021; 14(7):e243975.
59. Wan EYF, Chui CSL, Lai FTT, Chan EWY, Li X, Yan VKC, et al. Bell's palsy following vaccination with mRNA (BNT162b2) and inactivated (CoronaVac) SARS-CoV-2 vaccines: a case series and nested case-control study. **Lancet Infect Dis** 2021; 22: 64–72.
60. Dutta S, Kaur R, Charan J, Bhardwaj P, Ambwani SR, Babu S, et al. Analysis of neurological adverse events reported in Vigibase from COVID-19 vaccines. **Cure** 2022; 14:e21376.
61. Polack FP, Thomas SJ, Kitchin N, Absalon J, Gurtman A, Lockhart S, Perez JL, Marc GP, Moreira ED, Zerbini C, et al. Safety and efficacy of the BNT162b2 mRNA COVID-19 vaccine. **N Engl J Med** 2020; 383: 2603–2615.
62. Elias C, Cardoso P, Gonçalves D, Vaz I, Cardoso L. Rhabdomyolysis following administration of comirnaty. **Eur J Case Rep Intern Med** 2021; 8:002796.
63. Hakroush S, Tampe B. Case report: ANCA-associated vasculitis presenting with rhabdomyolysis and pauci-immune crescentic glomerulonephritis after pfizer-BioNTech COVID-19 mRNA vaccination. **Front Immunol** 2021; 12:762006.
64. Nassar M, Chung H, Dhayaparan Y, Nyein A, Acevedo BJ, Chicos C, Zheng D, Barras M, Mohamed M, Alfishawy M, et al. COVID-19 vaccine induced rhabdomyolysis: case report with literature review. **Diabetes Metabol Syndr** 2021; 15: 102170.
65. Ozonoff A, Nanishi E, Levy O. Bell's palsy and SARS-CoV-2 vaccines. **Lancet Infect Dis** 2021; 21: 450–452.

How to cite this article: Yaamika H, Muralidas D, Elumalai K. Review of adverse events associated with COVID-19 vaccines, highlighting their frequencies and reported cases. *J Taibah Univ Med Sc* 2023;18(6):1646–1661.