



## Case Report

## Orthodontic correction of Class II skeletal malocclusion complicated by deep bite using clear aligners: A case report

Rawah T. Eshky, Diplomate of ABO

Department of Pediatric Dentistry and Orthodontics, College of Dentistry, Taibah University, Almadinah Almunawwarah, KSA

Received 21 February 2022; revised 13 April 2022; accepted 16 April 2022; Available online 28 April 2022

### المخلص

تتناول هذه الحالة طريقة علاج مريض يعاني من سوء إطباق من الصنف الثاني المترافق مع عضة عميقة باستخدام التقويم الشفاف. المريض يبلغ من العمر 16 عامًا ويعاني من سوء الإطباق الهيكلي من الدرجة الثانية، وتراجع للفك السفلي، وعضة عميقة 7 مم، وقوس سبي عميق، وقواطع مائلة، وفراغات بين الأسنان، وتباين في تحليل بولتون في الفك السفلي، وإنحراف خط الوسط السفلي 2 مم، كما أن الثنايا طويلة. المريض جاء راعبا فقط بتقويم الأسنان الشفاف ولا يريد أجهزة تقويم الأسنان الثابتة التقليدية.

تم في نهاية المعالجة تحقيق الاهداف المرسومة بخطة العلاج في فترة زمنية امتدت لسنتين وشهرين، وكان المريض مسرورا بالنتائج الجمالية والعلاجية. يعد استخدام التقويم الشفاف جنبًا إلى جنب مع الملحقات والتوابع المضافة اليه طريقة فعالة لمعالجة صعوبات تقويم الأسنان مثل سوء إطباق من الصنف الثاني في وقت قياسي. علاوة على ذلك، فإن التقويم الشفاف يمتاز بأن الألم فيه أقل، والعناية بنظافة الفم تكون أسهل، كما أنه مقبول جماليا مقارنة بأجهزة تقويم الأسنان الثابتة التقليدية.

**الكلمات المفتاحية:** سوء الإطباق من الصنف الثاني؛ التقويم الشفاف؛ انفيزا لاين؛ تقديم الفك السفلي

### Abstract

This case report describes an orthodontic treatment using clear aligners in a patient with Class II malocclusion associated with a deep bite. A 16-year-old patient with skeletal Class II malocclusion presented with a retrognathic profile, a deep bite of 7 mm, deep curve of Spee, proclined incisors, spacing, an excess Bolton discrepancy in the mandible, lower midline shift 2 mm to the right,

and long clinical crowns. The patient preferred aligners over traditional fixed orthodontic appliances.

The treatment objectives were achieved in 2.2 years, and the patient was pleased with the aesthetic and treatment outcomes. Using aligners along with proper auxiliaries and attachments is an effective method of addressing orthodontic difficulties, such as Class II complicated with deep bites in a reasonable time. Further, clear aligners offer less pain, better oral hygiene, and more aesthetics comparable to that of conventional fixed orthodontic appliances.

**Keywords:** Class II Malocclusion; Clear aligners; Deep bite; Invisalign; Mandibular advancement

© 2022 The Authors. Published by Elsevier B.V. This is an open access article under the CC BY-NC-ND license (<http://creativecommons.org/licenses/by-nc-nd/4.0/>).

### Introduction

With the massive amount of information available on the internet and the advent of social media, the public's awareness of the value of having a beautiful smile has increased significantly.<sup>1–3</sup>

As a result, the number of patients seeking orthodontic treatment has increased. Information sharing information, conversations, and debates on social media concerning orthodontic treatment modalities and their benefits and drawbacks have provided the general public with a wealth of information about the benefits and pitfalls of each treatment modality.<sup>2,3</sup> The intense competition between companies and orthodontists has made the topic more exciting, and the competition in delivering the service has become increasingly profound.

Fixed orthodontic appliances have been known to achieve better tooth movement and control and can be used to treat

E-mail: raweshky@gmail.com

Peer review under responsibility of Taibah University.



Production and hosting by Elsevier

the majority of challenging cases; nevertheless, they have several pitfalls, including pain, discomfort, gingivitis, root absorption, conspicuous appearance, and tooth decay.

Clear aligner therapy, however, has emerged as one of the most interesting new techniques in orthodontics since its introduction in the late 1990s by Align Technology in the United States. Clear aligners are particularly suitable in cases where moderate anterior crowding should be treated without the need for tooth extractions,<sup>4</sup> although some reports have suggested that clear aligners can be used for even more complicated cases.<sup>5,6</sup> Current advances in technology and the introduction of CAD/CAM systems and a variety of auxiliaries are being integrated with clear aligners, making it possible for orthodontists to treat more complex cases without the need for fixed orthodontic appliances.

This case report describes a possible approach to treating Class II orthodontic cases with deep bites using only Invisalign.

### Clinical report

This case report presents an overview of how a clear aligner treatment approach can be used to correct Class II malocclusion complicated with a deep bite. A 16-year-old Saudi male patient was referred to the specialty clinic at the College of Dentistry, Taibah University, for orthodontic treatment. The patient's chief complaint was that he looked

ugly, and his main concern was that he did not want metal braces. However, his mother's main concern was that she did not like his smile and that they had visited many orthodontists who advised the use of metal braces. His initial orthodontic records showed that he had skeletal Class II relations with a full step Class II molar and canine on the right and Class I molar and canine on the left, retrognathic profile, a deep bite of 7 mm, deep curve of Spee, retroclined incisors, spacing, a Bolton discrepancy with excess of 0.73 mm in the mandible, lower midline shift 2 mm to the right, long clinical crowns, and increased overbite and overjet (Figure 1). His oral condition and oral hygiene were good, no Temporomandibular joint dysfunction was observed on inspection. Panoramic radiography revealed full dentition, no infection, and normal temporomandibular joint (Figure 2). Cephalometric readings showed skeletal Class II due to maxillary protrusion, and a hypodivergent facial type; maxillary incisors were proclined, and lower incisors had normal inclinations (Figure 3, Table 1).

### Treatment objectives

The following treatment objectives were set and discussed with the patient and his parent: correct the deep bite, improve the skeletal pattern, obtain a class I molar and canine on both sides, flatten the curve of Spee, correct the midline, and create functional occlusion.

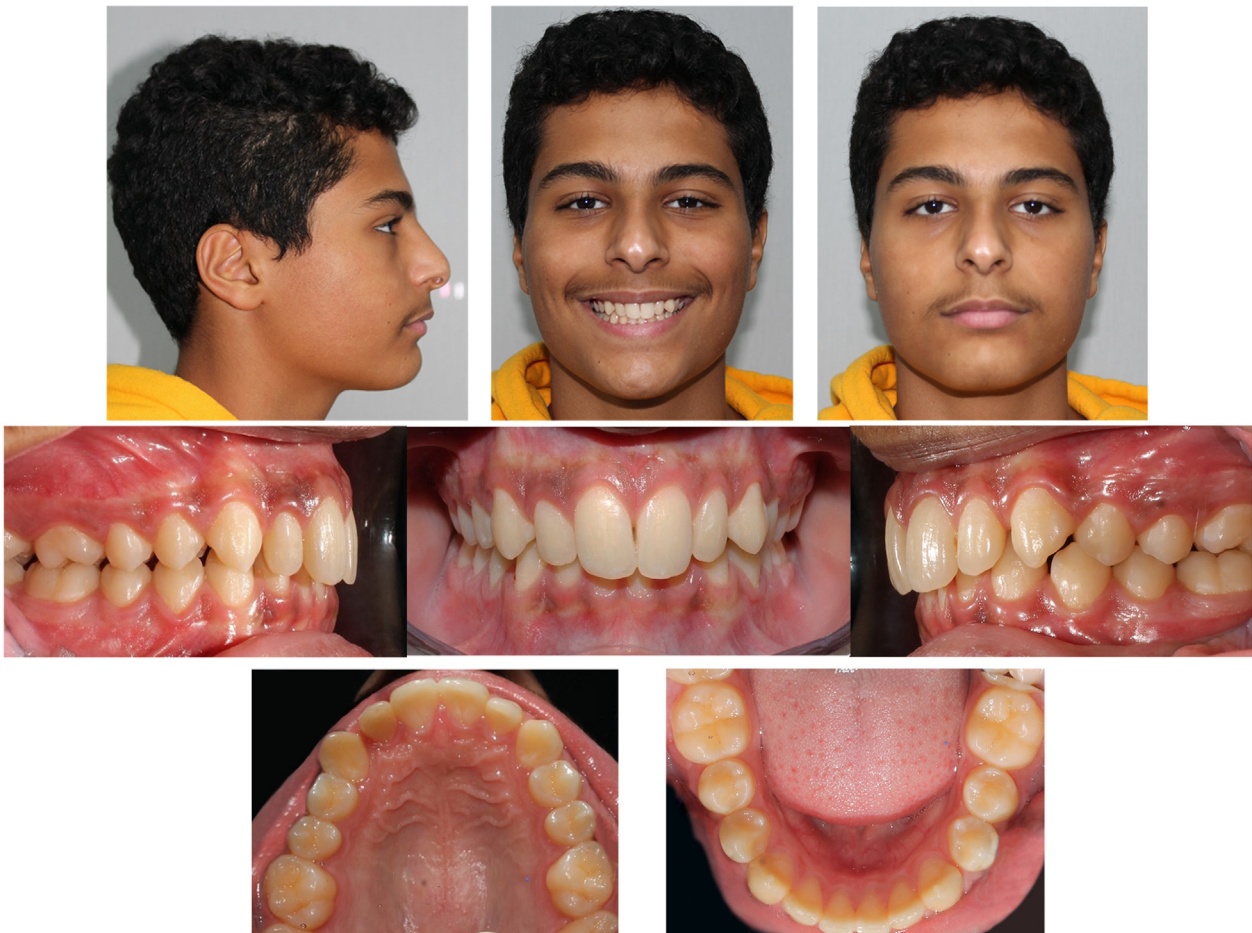

Figure 1: Pre-treatment photographs.

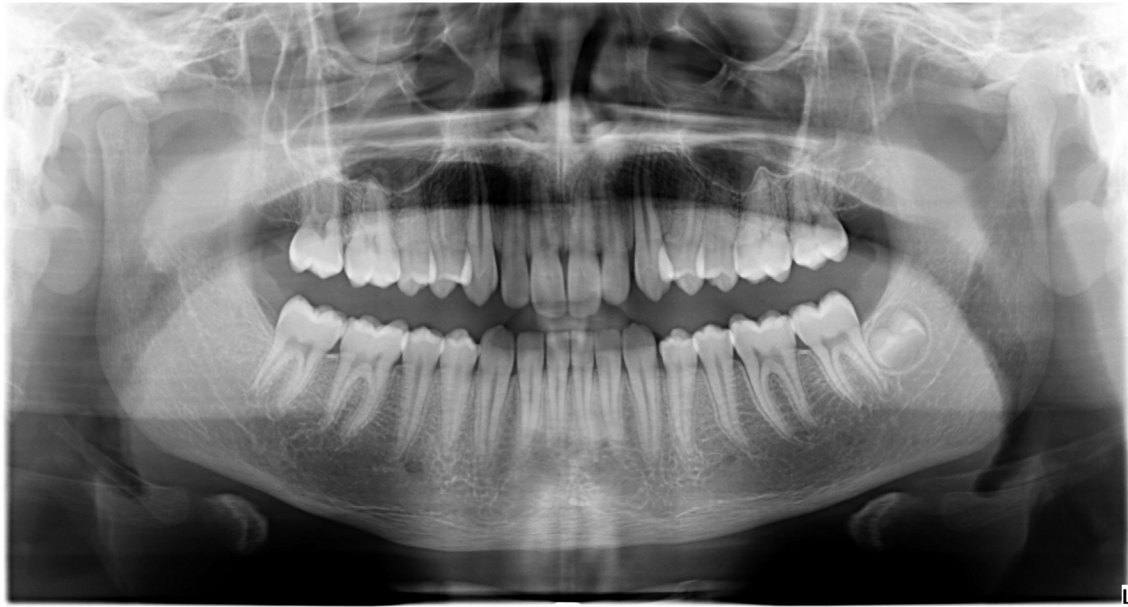

Figure 2: Pre-treatment panoramic radiograph.

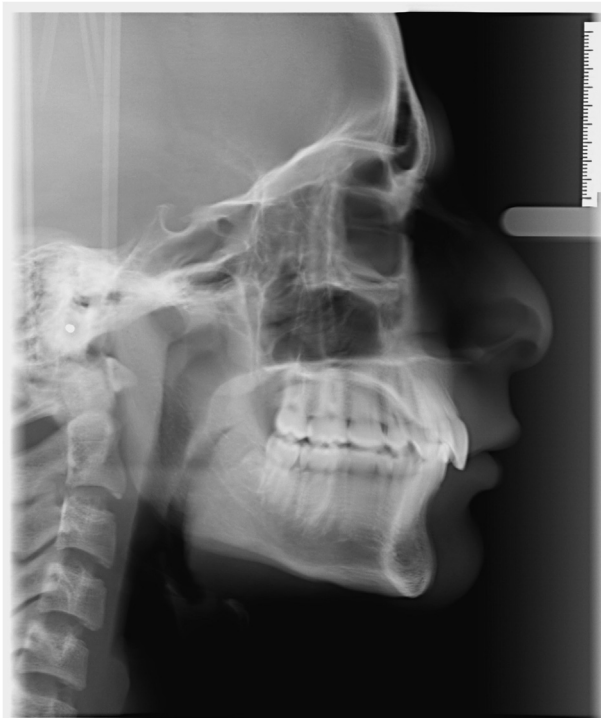

Figure 3: Pre-treatment cephalometric radiograph.

#### Treatment alternatives

1. Lingual braces with a Class II corrector
2. Clear aligners with Class II elastics
3. Clear aligners with built-in mandibular advancement (MA) features

#### Treatment plan and progress

The patient selected option 3, and his final consent was obtained. After acceptance of the treatment, all his records were uploaded to Invisalign doctor's site (Align Technology,

Table 1: Pre- and post-treatment cephalometric values.

Variable	Pre-treatment	Post-treatment	Norms
SNA (°)	87.8	85.1	82
SNB (°)	80.9	80.9	80
ANB (°)	6.9	4.6	2
FMA (°)	20.7	20.9	25
U1 – NA (mm)	0.4	–0.6	4
U1 – SN (°)	98.6	101.8	102
L1 – NB (mm)	10.7	3.6	4
L1 – MP (°)	101.1	96	90
Nasolabial Angle	98	115	102
Lower Lip to E-Plane (mm)	–3.9	–1.7	4
Upper Lip to E-Plane (mm)	–1.3	–4.3	2

San Jose, CA, USA), and the desired tooth movements were planned with the help of Clincheck Software. Using Clincheck, the final teeth and jaw positions were predicted, and simulated results were shown to the patient (Figure 4).

In this case, treatment began with the placement of the attachments, each set of aligners was worn for one week. The first phase of orthodontic treatment was accomplished with 36 aligners with MA in place from the lower second premolar to the upper first molars, and this lasted for 9 months. After first phase of treatment, the crowding resolved, the arches became well-aligned, and the incisor angulation and molar relation was improved but ended up with bilateral posterior open bite due to the MA feature (Figure 5). Consequently, the first refinement was initiated and continued for about 10 months using 19 aligners, along with slight interproximal enamel reduction from the lower 4-4. This stage aimed to close the open bite. After that, the second refinement was started with 9 aligners associated with anterior bite turbos and lasted for 3 months. The third refinement was done with 8 aligners, and this stage lasted for 5 months. The objective of the third refinement was to

increase the interdigitation between the posterior teeth. The treatment was completed, and the patient was given Vivera retainers with anterior bite turbos. The result was that class 1 molar and canine relation was successfully achieved, the midlines were on with no incisor proclination, the deep bite was corrected, skeletal relations were improved, and all the treatment objectives were achieved (Figure 6). Post-treatment panoramic and cephalometric radiographs are shown in Figures 7 and 8.

Pre-and post-treatment cephalometric superimposition is shown in Figure 9. However, there was a black triangle between the upper centrals due to the shape of the upper right central. The spaces between the upper centrals and laterals were intentionally left due to the size of the laterals that require build-up. Overall, the active treatment lasted 2.2 years and involved 72 maxillary and mandibular aligners.

## Discussion

With improvements in aligner materials, attachment design, and 3D software, aligners have become a comfortable and esthetic choice for many patients,<sup>7</sup> and the number of patients asking for treatment with clear aligners has dramatically increased. It is now possible to define goals, predict final tooth movements, and compare them to the original tooth positions. All of this is done in one spot with the Clincheck program.<sup>8</sup>

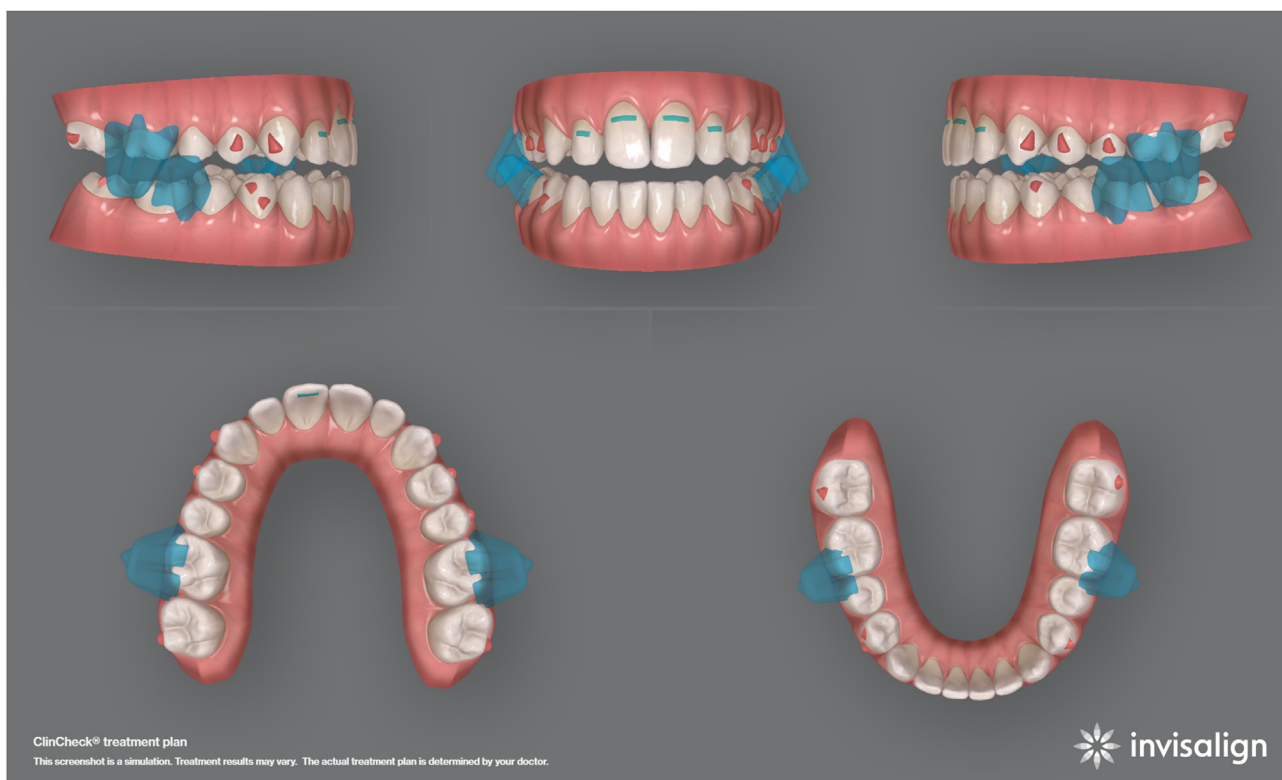
Patterson et al.<sup>9</sup> investigated the possibility of correcting Class II malocclusion using Invisalign with elastics. They reported that no improvements were noticed in the anteroposterior plane after 7 months of treatment, and that

only 6.8% of the predicted anteroposterior movement was achieved. They attributed this poor outcome to a possible lack of patient compliance or inadequate time allocated to achieve the desired tooth movement. Contrary to Patterson et al.<sup>9</sup> our patient was very cooperative and enthusiastic to wear the aligners, which therefore reflected on his treatment outcomes. Thus, Class II molar and canine relations were successfully rectified to Class I relations at the end of the treatment, indicating that MA seems to give better results than Class II elastics. However, one of the pitfalls of MA is the creation of a posterior open bite. In their evaluation of improvement in the overbite, Patterson et al.<sup>9</sup> reported that only 28.8% of overbite corrections were achieved. In the present case report, an optimal overbite was achieved at the end of treatment, and the improvement rate reached 100%, even though the clinical crown was very long.

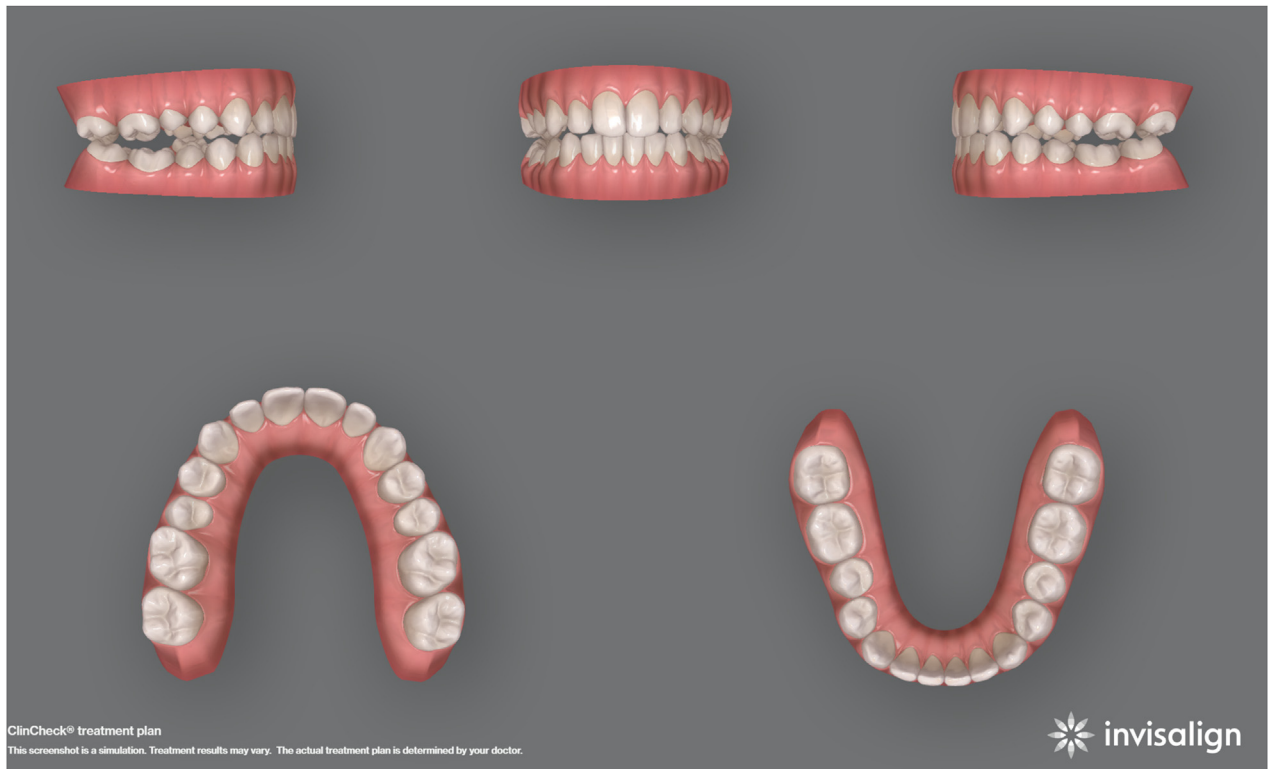
The patient and his parent were happy with the outcome. This successful outcome would not be achieved without the patient's motivation and involvement in each step of the treatment.

Due to the removable nature of aligners, oral health maintenance during aligner treatment is superior to that of conventional orthodontics, and therefore, the periodontal risk is minimized.<sup>10</sup>

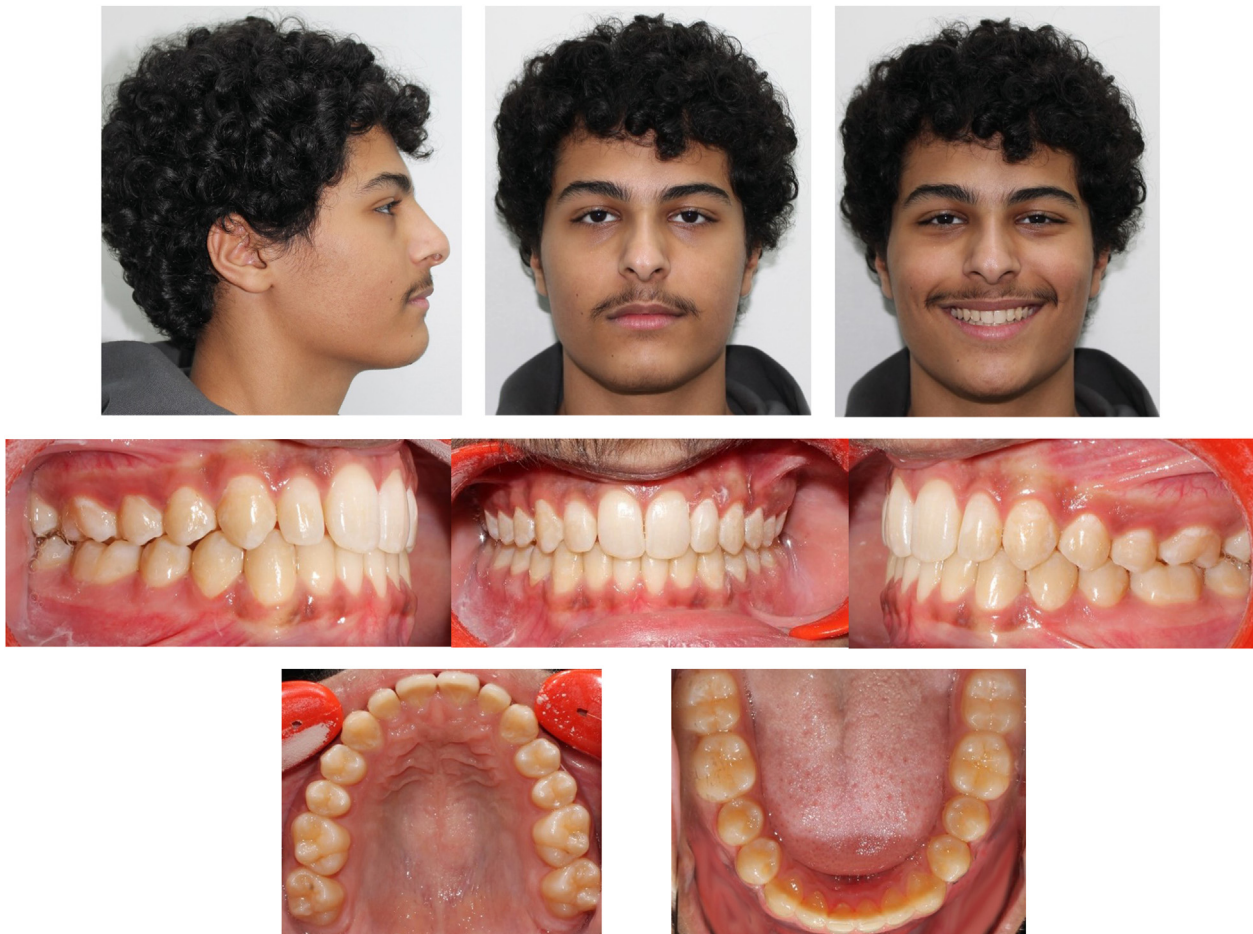
Finally, it is well known that the treatment duration with clear aligners is shorter than with traditional treatments; however, the treatment duration for this case lasted for 2.2 years. The reason behind this long treatment period was the COVID-19 pandemic, and the patients had to travel to study abroad for about 5 months before the debonding appointment.



**Figure 4:** Predicted teeth and jaw positions using Clincheck software.



**Figure 5:** Bilateral posterior open bite due to the MA feature.



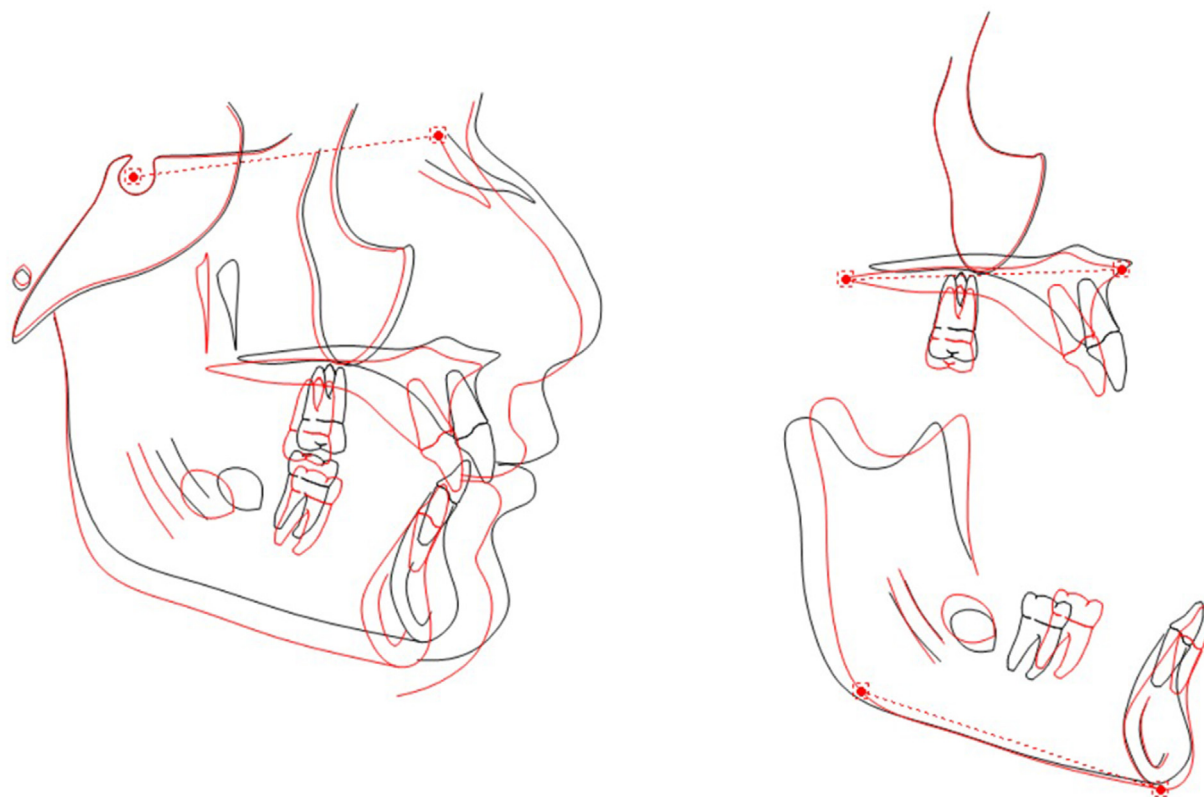
**Figure 6:** Post- treatment photographs.

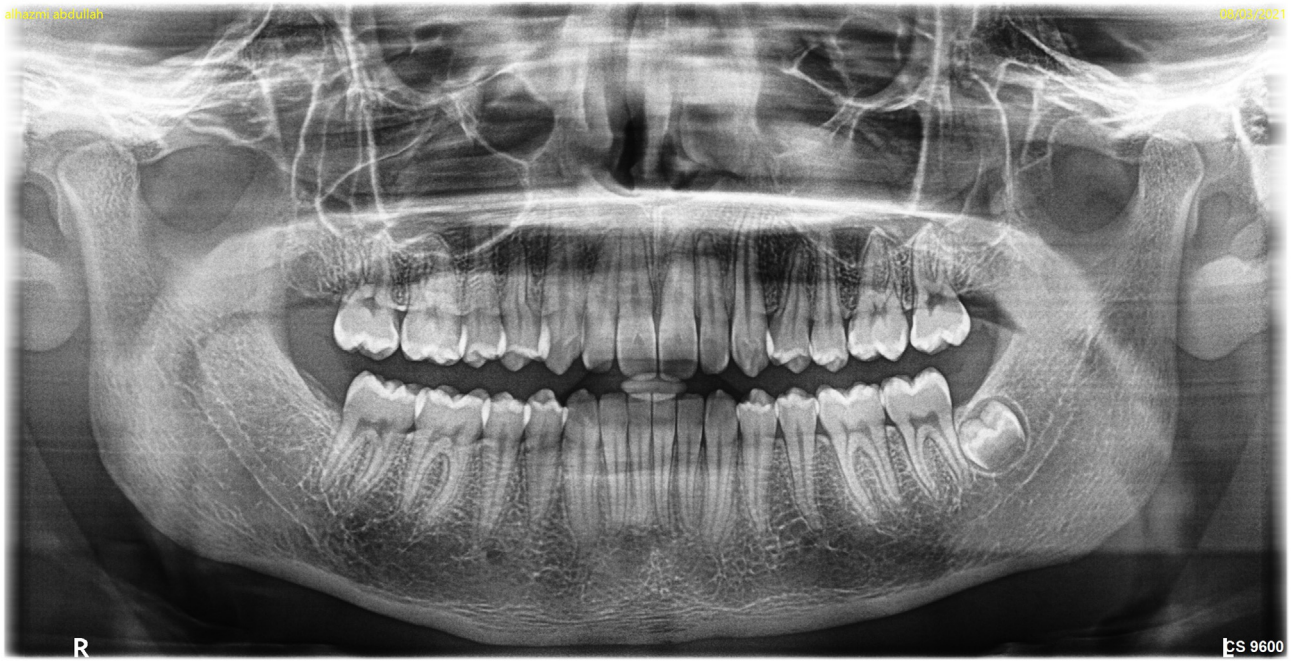

Figure 7: Post-treatment panoramic radiograph.

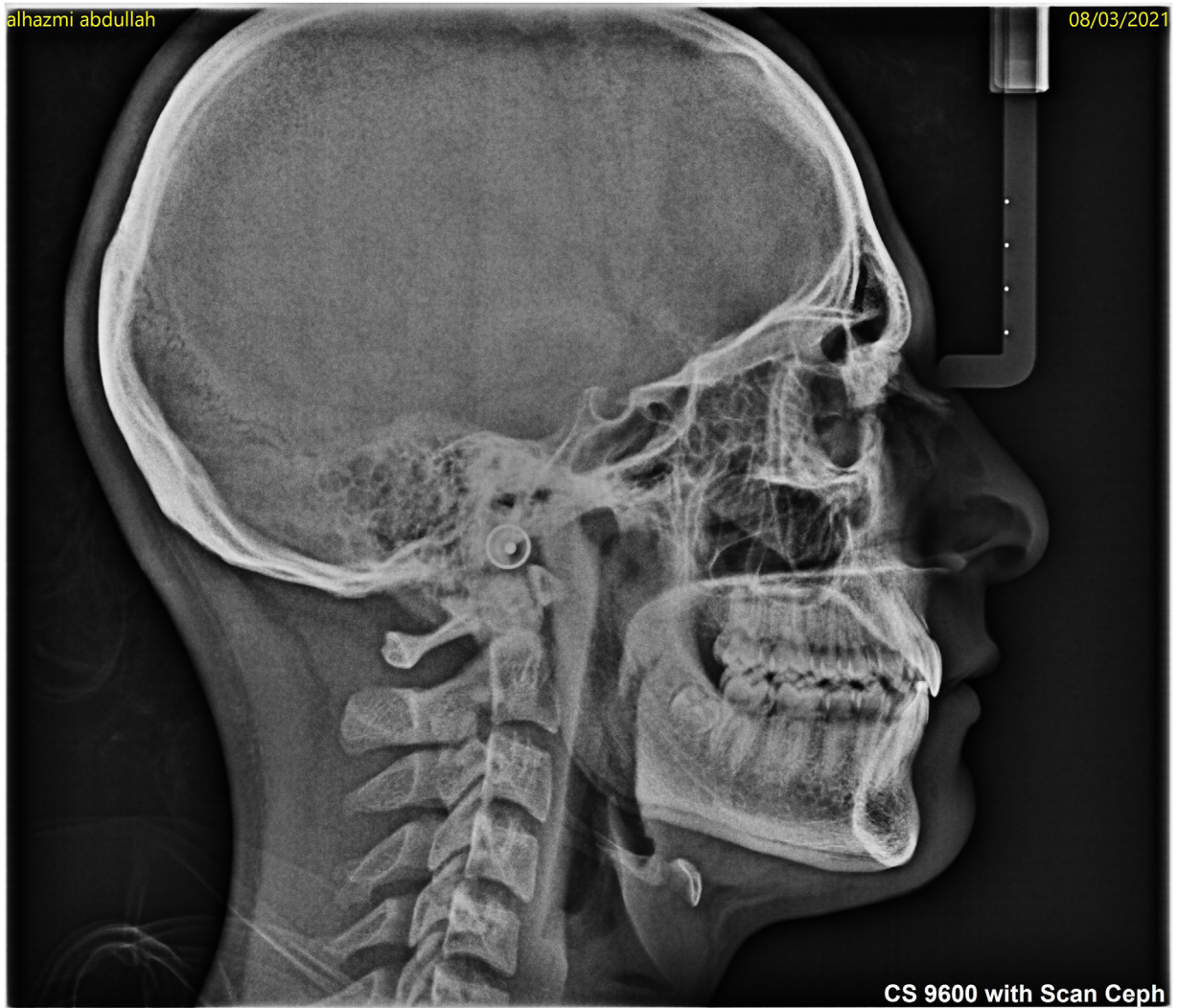

Figure 8: Post-treatment cephalometric radiograph.



**Figure 9:** Pre-and post-treatment cephalometric superimposition.

### Conclusion

According to the findings of this case report, using clear aligners can result in the successful treatment of Class II malocclusion associated with a deep bite. Case reports, however, cannot provide firm conclusions on any treatment modality, suggesting the need for more randomized control trials of clear aligners.

### Source of funding

This case report did not receive any specific grant from funding agencies in the public, commercial, or not-for-profit sectors.

### Conflict of interest

The authors have no conflict of interest to declare.

### Ethical approval

Informed consent was obtained and signed by the patient to publish his photos.

### References

1. Lombardo L, Colonna A, Carlucci A, Oliverio T, Siciliani G. Class II subdivision correction with clear aligners using inter-maxillary elastics. *Prog Orthod* 2018; 19(1): 32.
2. Al-Gunaid T, Ibrahim A, Alhazmi K, Aljohani A, Eshky R, Althagafi N. Impact of social media on patient's decision-making toward orthodontic treatment. *Saudi J Heal Sci* 2021; 10: 132–137.
3. Al-Gunaid TH, Aljohani AA, Alhazmi KM, Ibrahim AM. Determining the impact of orthodontic patients' characteristics on their usage and preferences of social media. *J Taibah Univ Med Sci* 2020; 16(1): 16–21.
4. Joffe L. Invisalign: early experiences. *J Orthod* 2003; 30: 348–352.
5. Vlaskalic V, Boyd RL. Clinical evolution of the Invisalign appliance. *J Calif Dent Assoc* 2002; 30(10): 769–776.
6. McKenna S. Invisalign: technology or mythology? *J Mass Dent Soc* 2001; 50(2): 8–9.
7. Boyd RL. Esthetic orthodontic treatment using the Invisalign appliance for moderate to complex malocclusions. *J Dent Educ* 2008; 72(8): 948–967.
8. Hönn M, Göz G. A premolar extraction case using the Invisalign system. *J Orofac Orthop* 2006; 67(5): 385–394.
9. Patterson BD, Foley PF, Ueno H, Mason SA, Schneider PP, Kim KB. Class II malocclusion correction with Invisalign: is it possible? *Am J Orthod Dentofacial Orthop* 2021; 159(1): e41–e48.
10. Miethke RR, Brauner K. A comparison of the periodontal health of patients during treatment with the Invisalign system and with fixed lingual appliances. *J Orofac Orthop* 2007; 68(3): 223–231.

**How to cite this article:** Eshky RT. Orthodontic correction of Class II skeletal malocclusion complicated by deep bite using clear aligners: A case report. *J Taibah Univ Med Sc* 2022;17(6):962–968.