

Case Report

Transnasal sphenopalatine ganglion block for postdural puncture headache in obstetric patients: A Malaysian experience report



Zawiah Kassim, Dr. Anaest & Critical Care (UKM)*, Rusnaini Mustapha Kamar, MANaes (UM), Mohd Fahmi Zakariah, MANaes (UM) and Ivy Sim Chui Geok, MANaes (UM)

Department of Anaesthesiology and Critical Care, Faculty of Medicine, Universiti Teknologi MARA, Selangor, Malaysia

Received 11 December 2021; revised 26 January 2022; accepted 10 February 2022; Available online 25 February 2022

المخلص

يعتبر "الصداع التالي لبزل الجافية" بين مرضى التوليد من المضاعفات الشائعة بعد التخدير العصبي المحوري. قد يكون للعلاج التحفظي إشكالات في الامتثال، بينما المعيار الذهبي للعلاج، البقعة الدموية فوق الجافية، هو تدخل باضع ويمكن أن يؤدي إلى مضاعفات خطيرة. ظهرت مؤخرا طريقة "إحصار العقدة الودية الحنكية عبر الأنف" كطريقة علاج غير باضعة للصداع التالي لبزل الجافية. نصف هنا تجربتنا لإحصار العقدة الودية الحنكية عبر الأنف باستخدام تقنية معدلة وأنظمة دوائية مختلفة في مركزنا. تم استخدام الديكساميثازون كعامل مساعد في "إحصار العقدة الودية الحنكية عبر الأنف" لعلاج "الصداع التالي لبزل الجافية" ولم يتم نشرها في دراسة أخرى. أسفرت حالتنا الأولى عن شفاء تام للصداع التالي لبزل الجافية، والمریضة الأخرى تم علاج الصداع جزئيا، وبعد ذلك احتاجت إلى البقعة الدموية فوق الجافية.

الكلمات المفتاحية: إحصار العقدة الودية الحنكية عبر الأنف؛ صداع تال لبزل الجافية؛ التوليد؛ البقعة الدموية فوق الجافية؛ التخدير العصبي المحوري

Abstract

Postdural puncture headache (PDPH) is a common complication among obstetric patients after neuraxial anaesthesia. Conservative management may be associated with compliance issues, whereas the gold standard treatment, the epidural blood patch, is invasive and can

result in serious complications. Transnasal sphenopalatine ganglion (SPG) block has recently emerged as a non-invasive treatment modality for PDPH. We describe our experience in performing transnasal SPG block by using modified techniques and different drug regimens at our centre. Dexamethasone was used as an adjuvant in transnasal SPG block for PDPH and has not been reported in other studies. Our first patient showed complete resolution of PDPH, and our second patient had a partially resolved headache subsequently requiring an epidural blood patch.

Keywords: Epidural blood patch; Neuraxial anaesthesia; Obstetric; Postdural puncture headache; Transnasal sphenopalatine ganglion block

© 2022 The Authors. Published by Elsevier B.V. This is an open access article under the CC BY-NC-ND license (<http://creativecommons.org/licenses/by-nc-nd/4.0/>).

Introduction

Postdural puncture headache (PDPH) is a debilitating complication following neuraxial anaesthesia. The risk of inadvertent dural puncture increases during labour analgesia, because the insertion becomes technically more challenging. Conservative management of PDPH, such as through hydration, bed rest and caffeine, have not been demonstrated to be effective.¹ Among Malaysian mothers, noncompliance with hydration therapy, owing to cultural postpartum practices, may compound the PDPH symptoms.² The epidural blood patch (EBP), the gold standard for management of PDPH, has an efficacy of only 75% and is potentially associated with severe complications.^{1,3}

* Corresponding address: Department of Anaesthesiology and Critical Care, Hospital UiTM, 42300, Bandar Puncak Alam, Selangor, Malaysia.

E-mail: zawiah81@uitm.edu.my (Z. Kassim)

Peer review under responsibility of Taibah University.



Recent studies of transnasal sphenopalatine ganglion (SPG) block in PDPH have shown promising results with the advantages of simplicity, less invasiveness and a high safety profile.⁴⁻⁶ Here, we present our experience in performing transnasal SPG block in obstetric patients with PDPH. Our first patient experienced full recovery after a single transnasal SPG block, whereas our second patient experienced only transient resolution of headache and required EBP.

Case report

Case 1

Patient A, a 28-year-old primigravida, received intervertebral L3/L4 spinal anaesthesia for an emergency lower segment Caesarean section. Intrathecal medication was eventually successful after multiple subarachnoid block attempts with a 27G and subsequently a 25G Pencan needle. However, she developed severe positional occipital headaches with no other associated neurological symptoms on the following day. She was diagnosed with PDPH and was started on a conservative management consisting of hydration, analgesia and bed rest. Her headache resolved after 12 h, and she was discharged home. Unfortunately, she had a recurrence of symptoms that warranted hospital readmission on the following day. She consented to a transnasal SPG block. If the SPG block failed, an EBP would have been the next management course. Concurrently, conservative management was started. Preparation for the SPG block was conducted in a sterile manner. Two cotton-tipped applicators were soaked in a cocktail of lignocaine 2% (5 ml, 1.5 mg/kg) and dexamethasone 8 mg

(Figure 1:i). The patient was instructed to lie supine with her neck extended. The cotton tip applicators were inserted in each nostril, aimed to the middle turbinates and advanced until resistance was felt. The applicators were left in the nostrils for 8 min (Figure 1:ii). The headache severity was assessed with a 10-point numeric rating scale (NRS) while the patient was in sitting position (Table 1). Her vital signs were monitored every 10 min during the procedure for the next hour. After several hours, her headache fully resolved.⁷

Case 2

Patient B, a 24-year-old woman, had epidural labour analgesia with a complication of severe PDPH on day 1 of delivery. An epidural was performed at another centre with a confirmed inadvertent dural puncture. She experienced ambulatory frontal headaches associated with nausea, neck stiffness and blurring of vision. Similarly, she was offered a transnasal SPG block after failure of conservative management. We refined the technique of infusing the local anaesthetic (LA) to ensure better coverage of the SPG area by attaching a 22 G plastic intravenous cannula connected to a syringe into one pre-cut end of the hollow stem of the cotton-tipped applicators. The LA in the syringe, when injected, passed down the stem, then reached and saturated the cotton bud end (Figure 2:i). As in the previous case, lignocaine 2% (5 ml, 1.5 mg/kg) and dexamethasone 8 mg were used. The cotton-tipped applicators were inserted into the nostrils and aimed at the SPG area. Subsequently, 0.5 mL (ml) of LA mixture was injected. The NRS significantly improved from severe to mild pain immediately after the procedure (Table 1). Unfortunately, after 4 h, the patient had a severe

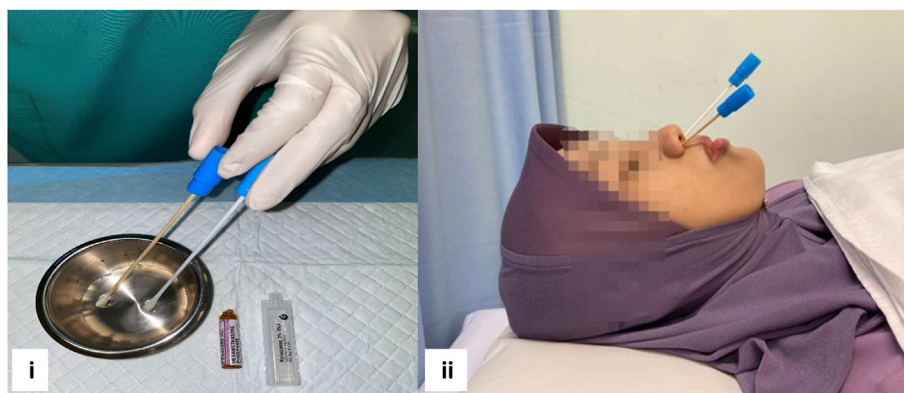


Figure 1: SPG block technique for patient A. i: Cotton-tipped applicator soaked in lignocaine dexamethasone mixture. ii: Bilateral topical SPG block.⁷

Table 1: Pain scores on an NRS at various times.

Patient	Procedure	Time							
		Prior procedure	Immediate	5 min	60 min	4 h	12 h	24 h	48 h
A	First SPG	8	7	5	3	0	0	0	0
B	First SPG	7	3	1	0	7	7	—	—
	Second SPG	7	3	3	7	7	—	—	—
	EBP	7	1	1	0	0	0	0	0

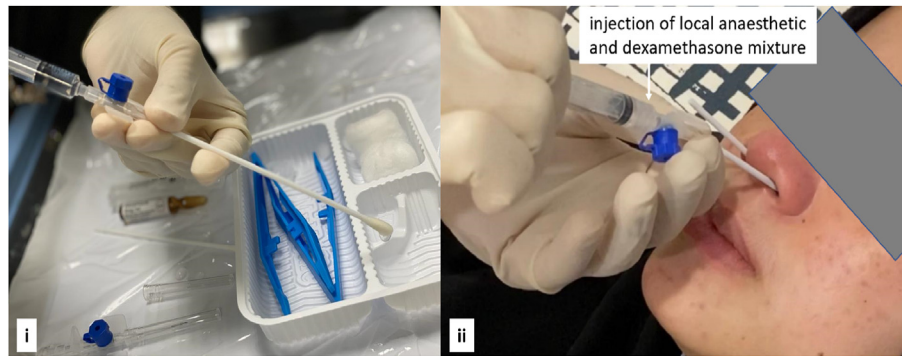

Figure 2: SPG block technique for patient B. i: Attachment of 22G plastic branula to the cotton-tipped applicator. ii: Infusion of LA with a 22G plastic catheter branula attached to a cotton-tipped applicator.

recurrent headache associated with neck pain and stiffness and requested a second SPG block. The findings of a complete neurological examination were unremarkable. The second SPG block was performed on the following day with a longer-acting LA, ropivacaine 0.75% mixture with dexamethasone 8 mg. The headache improved from severe to mild immediately after the procedure, but the relief lasted for only 1 h. Unsustained relief of her headache warranted an EBP. The EBP performed on the same day was uneventful, and she had complete resolution of PDPH 1 h later.

Discussion

PDPH is defined as a headache occurring within 5 days of a lumbar puncture, caused by cerebrospinal fluid leakage through the dura.⁸ The prevalence of PDPH in the obstetric population after neuraxial blocks is approximately 1%.^{9,10} The exact mechanism underlying PDPH remains unclear. Meningeal traction secondary to cerebrospinal fluid leak and compensatory cerebral vasodilation are believed to be the possible causes of debilitating headaches after dural puncture.¹¹ The first line of treatment includes conservative management, such as adequate hydration. An epidural blood patch is the gold standard management after failure of conservative therapy. Given that a Cochrane review by Arevalo-Rodriguez has found no clear benefit of traditional measures in even the prevention of PDPH, the SPG block provides a promising and less invasive treatment option.¹² The SPG is a group of parasympathetic ganglia located in the pterygopalatine fossa. Although SPG block has recently gained popularity as a less invasive treatment for PDPH, it has previously been performed to manage migraine, cluster headache and trigeminal neuralgia.^{13,14} The hypothesized mechanism of SPG block is the inhibition of parasympathetically mediated cerebral vasodilation.¹⁴ SPG block can be performed through transnasal, transcutaneous or intraoral approaches. Transnasally, the ganglion lies in the region posterior to the middle nasal turbinate, covered by a thin layer of connective tissue and mucous membrane.¹⁵ The transnasal topical approach is commonly used in PDPH, because it is technically simple, minimally invasive and relatively safe.

The evidence of SPG block efficacy in managing PDPH is currently limited to one randomized control trial (RCT) and

several retrospective studies and case series. The retrospective studies and case series have reported good outcomes in patients with PDPH who received an SPG block.^{4–6} However, the RCT performed by Jespersen et al. has reported no significant differences in pain relief between the SPG group and placebo, and 50% of patients in both groups received EBP.¹⁶ In our case report, the first patient experienced sustained relief of PDPH after a single SPG block. The second patient also had good pain relief initially, but the relief was not sustained despite a second SPG block, and the patient eventually received EBP. We were unable to achieve sustained relief despite using ropivacaine, a longer-acting LA. The efficacy of ropivacaine for SPG block has been described in the literature.^{16–18} However, no study has compared the duration of SPG block between lignocaine and ropivacaine. Because SPG block provides only symptomatic relief and has a limited duration of action, repeat procedures may be needed until the dural tear heals spontaneously. Although no protocol has been established for repeat SPG block, some studies have reported repeated SPG block procedures up to two or three times daily.^{16,19,20} The PDPH induced by a Tuohy needle is highly likely to be less amenable to symptomatic management with SPG blocks, owing to the greater degree of dural damage.

To our knowledge, these are the first two cases of the use of transnasal SPG block with a steroid and LA mixture for PDPH. We added dexamethasone as an adjuvant to lignocaine 2% and ropivacaine 0.75% to prolong the duration of analgesia. The addition of steroids to LA in an SPG block has been reported to decrease the severity and frequency of cluster headaches.^{21,22}

Transnasal SPG block is technically easy to perform and is minimally invasive. This procedure could be performed at the first presentation of PDPH, such as in the emergency department. Patients could also be educated to self-perform the block at home. Lopez and Dubey suggest that mothers could then apply the treatment on demand, thus enabling autonomy and supporting a discharge home.^{4,23} Because transnasal SPG block carries a minimal risk of complications, performing SPG block for management of PDPH seems reasonable before the more invasive EBP. In fact, some authors have suggested that SPG block should be the first-line treatment for PDPH, because it is less invasive and has reasonable success.²⁴ Because most transnasal

SPG blocks are performed as a blind technique with some proprietary atomizer devices available, such as Sphenocath® and Tx360®, we also postulate that the block could be enhanced under direct nasoendoscopy guidance. This visualization would ensure that LA is more accurately deposited at the SPG area and potentially could increase efficacy.

Conclusion

Transnasal SPG block is a safe and straightforward procedure that may be considered as an early treatment modality for PDPH before performing an EBP. More RCTs are needed to study the efficacy and the ideal medication mixture and dose for SPG block.

Source of funding

This research did not receive any specific grant from funding agencies in the public, commercial or not-for-profit sectors.

Conflict of interest

The authors have no conflict of interest to declare.

Ethical approval

Not applicable.

Consent

Written informed consent for publication of clinical images was obtained from the patients.

Authors contributions

ZK, RMK and MFZ were involved in the conception and drafting of the case report. ISCG was involved in the drafting of the case report. All authors have critically reviewed and approved the final draft and are responsible for the content and similarity index of the manuscript.

References

1. Sudlow CL, Warlow CC. Epidural blood patching for preventing and treating post-dural puncture headache. *Cochrane Database Syst Rev* 2002; (2):CD001791.
2. Fadzil F, Shamsuddin K, Wan Puteh SE. Traditional postpartum practices among Malaysian mothers: a review. *J Alternative Compl Med* 2016; 22(7): 503–508.
3. Gaiser RR. Postdural puncture headache: an evidence-based approach. *Anesthesiol Clin* 2017; 35(1): 157–167.
4. López T, Sastre JA, Gómez-Ríos MA. Sphenopalatine block with lidocaine spray for treatment of obstetric postdural puncture headache. *J Clin Anesth* 2021; 68: 110069.
5. Cohen S, Levin D, Mellender S, Zhao R, Patel P, Grubb W, et al. Topical sphenopalatine ganglion block compared with epidural blood patch for postdural puncture headache management in postpartum patients: a retrospective review. *Reg Anesth Pain Med* 2018 Nov 1; 43(8): 880–884.
6. Kent S, Mehaffey G. Transnasal sphenopalatine ganglion block for the treatment of postdural puncture headache in obstetric patients. *J Clin Anesth* 2016 Nov 1; 34: 194–196.
7. Karim SA, Mustapha Kamar R, Kassim Z, Zakariah MF. Transnasal sphenopalatine ganglion block for postdural puncture headache – a successful avoidance of epidural blood patch. *J Clin Health Sci*. In press.
8. Arnold M. Headache classification committee of the international headache society (IHS) the international classification of headache disorders. *Cephalalgia* 2018; 38(1): 1–211.
9. Van de Velde M, Schepers R, Berends N, Vandermeersch E, De Buck F. Ten years of experience with accidental dural puncture and post-dural puncture headache in a tertiary obstetric anaesthesia department. *Int J Obstet Anesth* 2008; 17: 329–335.
10. Tien JC, Lim MJ, Leong WL, Lew E. Nine-year audit of post-dural puncture headache in a tertiary obstetric hospital in Singapore. *Int J Obstet Anesth* 2016; 28: 34–38.
11. Turnbull DK, Shepherd DB. Post-dural puncture headache: pathogenesis, prevention and treatment. *Br J Anaesth* 2003; 91(5): 718–729.
12. Arevalo-Rodriguez I, Ciapponi A, Figuls MR, Munoz L, Cosp XB. Posture and fluids for preventing post-dural puncture headache. *Cochrane Database Syst Rev* 2016; 3(3):CD009199.
13. Ho KW, Przkora R, Kumar S. Sphenopalatine ganglion: block, radiofrequency ablation and neurostimulation—a systematic review. *J Headache Pain* 2017 Dec; 18(1): 1–27.
14. Robbins MS, Robertson CE, Kaplan E, Ailani J, Charleston IVL, Kuruvilla D, Blumenfeld A, Berliner R, Rosen NL, Duarte R, Vidwan J. The sphenopalatine ganglion: anatomy, pathophysiology, and therapeutic targeting in headache. *Headache J Head Face Pain* 2016 Feb; 56(2): 240–258.
15. Nair AS. Bilateral transnasal sphenopalatine block for treating postdural puncture headache. *Korean J Anesthesiol* 2018 Feb; 71(1): 73.
16. Jespersen MS, Jaeger P, Ægidius KL, Fabritius ML, Duch P, Rye I, et al. Sphenopalatine ganglion block for the treatment of postdural puncture headache: a randomised, blinded, clinical trial. *Br J Anaesth* 2020; 124(6): 739–747.
17. Furtado I, Lima IF, Pedro S. Ropivacaine use in transnasal sphenopalatine ganglion block for post dural puncture headache in obstetric patients—case series. *Rev Bras Anesthesiol* 2018 Jul; 68: 421–424.
18. Santos NS, Nunes JM, Font ML, Carmona C, Castro MM. Early versus late sphenopalatine ganglion block with ropivacaine in postdural puncture headache: an observational study. *Braz J Anesthesiol* 2021 Mar 21 (English Edition), <https://www.sciencedirect.com/science/article/pii/S0104001421000919>. [Accessed 5 December 2021]. In press.
19. Sanghavi PR, Shah BC, Joshi GM. Sphenopalatine ganglion block for head and neck cancer pain: self administered blocks are key to improving the quality of life. *Indian J Palliat Care* 2017; 23(3): 282–286.
20. Peterson JN, Schames J, Schames M, King E. Sphenopalatine ganglion block: a safe and easy method for the management of orofacial pain. *Cranio* 1995; 13(3): 177–181.
21. Rocha-Romero A, Roychoudhury P, Benavides Cordero R, Lopez Mendoza M. Self-applied sphenopalatine ganglion block for postdural puncture headache: four case reports. *Rev Bras Anesthesiol* 2020; 70(5): 561–564.

22. Felisati G, Arnone F, Lozza P, Leone M, Curone M, Bussone G. Sphenopalatine endoscopic ganglion block: a revision of a traditional technique for cluster headache. *Laryngoscope* 2006; 116(8): 1447–1450.
23. Dubey P, Dubey PK. Intranasal lignocaine spray for sphenopalatine ganglion block for postdural puncture headache. *Saudi J Anaesth* 2018 Apr; 12(2): 364.
24. Gaiser RR. Postdural puncture headache. An evidence based approach. *Anesthesiol Clin* 2017 Mar; 1: 157–167.

How to cite this article: Kassim Z, Kamar RM, Zakariah MF, Chui Geok IS. Transnasal sphenopalatine ganglion block for postdural puncture headache in obstetric patients: A Malaysian experience report. *J Taibah Univ Med Sc* 2022;17(5):805–809.