




Taibah University

Journal of Taibah University Medical Sciences

www.sciencedirect.com



Case Report

## Volvulus of the transverse colon after resection of the sigmoid volvulus: A case report



Fatemeh Chinisaz<sup>a</sup>, Hoda Asefi, M.D.<sup>b</sup> and Seyed Amir Miratashi Yazdi, M.D.<sup>c,d,\*</sup>

<sup>a</sup> Students' Scientific Research Center, Department of Surgery, Tehran University of Medical Sciences, Tehran, Iran

<sup>b</sup> Department of Radiology, Sina Hospital, Tehran University of Medical Sciences, Tehran, Iran

<sup>c</sup> Department of Surgery, Sina Hospital, Tehran University of Medical Sciences, Tehran, Iran

Received 23 July 2021; revised 14 August 2021; accepted 28 August 2021; Available online 24 September 2021

### المخلص

الانفتال السيني هو سبب شائع لانسداد القولون، بينما نادراً ما يتسبب انفتال القولون المستعرض في انسداد الأمعاء. ومن النادر للغاية حدوث انفتال القولون المستعرض بعد استئصال القولون السيني. يقدم هذا التقرير رجلاً يبلغ من العمر ٧٣ عاماً يعاني من آلام البطن والتهاب الصفاق. خضع المريض لبضع البطن الاستكشافي وتم التأكيد من التواء القولون السيني وانتقاب الأعور. وتم إجراء استئصال النصف الأيمن للقولون، ومفارقة القولون اللفانفي العرضي من طرف إلى جانب الانتقاب الأعور، واستئصال السيني مع فغر نهاية القولون (إجراء هارتمان) للانفتال السيني. بعد شهر، عاد المريض إلى الطوارئ يشكو من انتفاخ في البطن وانسداد في فغر القولون. وكشف التصوير المقطعي المحوسب للبطن عن انفتال القولون المستعرض. تم استئصال القولون المستعرض والنازل ومفارقة اللفانفي المستقيم. وخرج المريض من المستشفى في حالة مستقرة. يجب أن تشمل إدارة انفتال القولون متغير الزمن التدخل الجراحي. إذا لم يتم تشخيص المرضى على الفور، فقد تدهور حالتهم بشكل كبير بسبب احتشاء الأمعاء أو التهاب الصفاق. ومن الضروري تسليط الضوء على هذه الحالة لأن الكثير من الجراحين ربما لم يعالجوا انفتال القولون المستعرض بعد الانفتال السيني، مما قد يؤدي إلى ارتفاع معدلات المراضة أو الوفاة. بشكل عام، يجب مراعاة الانفتال القولوني المتغير الزمن في التشخيص التفريقي لانسداد الأمعاء، خاصة في المرضى الذين يعانون من عوامل خطر كبيرة.

**الكلمات المفتاحية:** الانفتال السيني؛ الانفتال القولوني المستعرض؛ انسداد الأمعاء؛ التهاب الصفاق؛ إجراء هارتمان.

### Abstract

Sigmoid volvulus is a common cause of colon obstruction, while volvulus of the transverse colon rarely causes bowel obstruction. The occurrence of transverse colon volvulus after resection of the sigmoid colon volvulus is extremely rare. This report presents a 73-year-old man who presented with abdominal pain and peritonitis. The patient underwent exploratory laparotomy, and sigmoid volvulus and cecum perforation were confirmed. A right hemicolectomy, end-to-side ileotransverse colon anastomosis for the cecal perforation, and sigmoidectomy with end-colostomy (Hartmann's procedure) for the sigmoid volvulus were performed. A month later, the patient returned to the emergency room with abdominal distention and the blockage of colostomy. Abdominal CT revealed a transverse colon volvulus. A transverse and descending colon resection and ileorectal anastomosis were performed. The patient's condition was stable at the time of discharge from the hospital. The management of metachronous colon volvulus should include surgical intervention. If patients are not diagnosed immediately, their condition may deteriorate dramatically because of bowel infarction or peritonitis. It is essential to highlight this case, as many surgeons may not have attended a transverse colon volvulus after sigmoid volvulus, which might lead to high morbidity or mortality. Overall, metachronous colonic volvulus must be considered in the differential diagnosis of bowel obstruction, particularly in patients with significant risk factors.

**Keywords:** Bowel obstruction; Hartmann's procedure; Peritonitis; Sigmoid volvulus; Transverse colonic volvulus

\* Corresponding address: Sina Hospital, Department of Surgery, School of Medicine, Tehran University of Medical Sciences, Tehran, Iran.

E-mail: [amiratashi@sina.tums.ac.ir](mailto:amiratashi@sina.tums.ac.ir) (S.A. Miratashi Yazdi)

Peer review under responsibility of Taibah University.



Production and hosting by Elsevier

<sup>d</sup> Postal address: Sina Hospital, Hassan Abad Square, Imam Khomeini Avenue, Tehran, Iran, Post BOX: 1136746911.

© 2021 The Authors. Published by Elsevier B.V. This is an open access article under the CC BY-NC-ND license (<http://creativecommons.org/licenses/by-nc-nd/4.0/>).

## Introduction

Volvulus of the large bowel is twisting of the colon around itself, leading to bowel obstruction, which may cause ischemia of the bowel and necrosis; if not diagnosed immediately, this may cause bowel perforation. Patients with colonic volvulus may complain about symptoms like abdominal pain and cramps, abdominal bloating, constipation, nausea and vomiting, and inability to pass gas.<sup>1</sup>

Sigmoid volvulus (SV) is the most common cause of colon obstruction (60–80%). The high prevalence of volvulus in this area seems to be due to its anatomical condition, and one-third of all colon obstructions occur in this area of large bowel. Transverse colon volvulus (TCV) is less common than other types of bowel volvulus; however, volvulus in the transverse colon is the cause of almost 5% of all cases of colon volvulus.<sup>2</sup> Accordingly, synchronous or metachronous sigmoid and transverse colon volvulus is an even rarer medical condition.<sup>3</sup>

The article describes a case of volvulus of the transverse colon in a patient with a past surgical history of sigmoidectomy and hemicolectomy due to sigmoid volvulus and right colon perforation.

## Case presentation

A 73-year-old man presented to the emergency department with a 3-day history of abdominal pain, distension, and obstipation. The patient did not have any past surgical or drug history, and did not mention any relevant familial and habitual history. The patient looked ill and dehydrated. His blood pressure was 103/77 mmHg, and his pulse rate was 112 per minute. No abnormality was detected in the respiratory, cardiovascular, and nervous systems.

Abdominal examination revealed severe generalized tenderness, rebound tenderness, and guarding. No masses or hernias were palpable. No bowel sound was detected, and digital rectal examination (DRE) was normal and revealed an empty rectum. The patient was resuscitated with intravenous

fluid (normal saline), antibiotics, and nasogastric decompression. Due to signs of peritonitis, the patient was taken for emergency laparotomy, and gangrenous sigmoid volvulus and perforation of the cecum was reported. The patient underwent right hemicolectomy, end-to-side anastomosis of the ileum to the transverse colon, sigmoidectomy, and end colostomy (Hartmann procedure). The patient did well postoperatively and was discharged from the hospital after he became stable.

One month later, the patient returned to the ER of the hospital with complaints of abdomen distension and blockage of the colostomy for almost 24 h. Abdominal examination confirmed general distention, mild general tenderness, no guarding or rebound tenderness, and no bowel sounds. The patient's stoma bag was noticed, but the colostomy seemed not to have worked properly for hours. Blood pressure was 132/83 mmHg, and pulse rate was 105 per minute. Investigation revealed the following: white blood cell count, 14810 cells/mm<sup>3</sup>; haemoglobin level, 13.1 gm/dL; platelet count, 169000 cells/mm<sup>3</sup>; BS, 201 mg/dL; LDH, 485 u/l; PTT, 65.4s; INR, 2.65; and PT, 31.7s.

In the performed abdominal CT scan, end colostomy was evident on the left side at the level of the umbilicus. Previous right hemicolectomy and ileo-transverse anastomosis were also noted. Ileal loops and transverse colon were dilated. A transition point was present in the distal part of the transverse colon associated with a whirl sign in transverse colon mesentery and closed-loop obstruction, which was suggestive of transverse colon volvulus (Figure 1).

The patient underwent transverse and descending colon resection surgery and ileorectal anastomosis (Figure 2). He was successfully managed and discharged home in good condition. He is planned for regular clinical follow-ups.

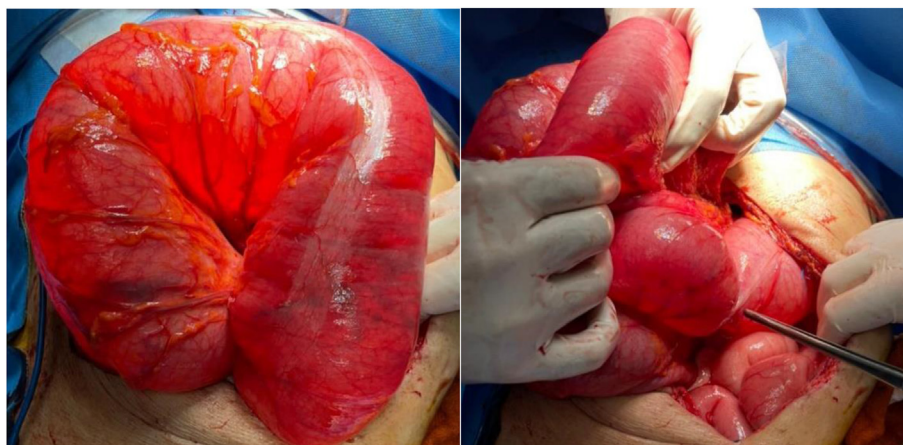
## Discussion

The occurrence of transverse colon volvulus and sigmoid volvulus can be simultaneous or at separate times (metachronous colonic volvulus). Metachronous transverse and sigmoid volvulus is extremely rare and can be easily missed.<sup>4</sup> We report metachronous transverse and sigmoid volvulus in an old man who showed transverse colon volvulus a month after his sigmoid volvulus was treated.

One of the significant risk factors of colonic volvulus is aging, which is strongly associated with chronic constipation.

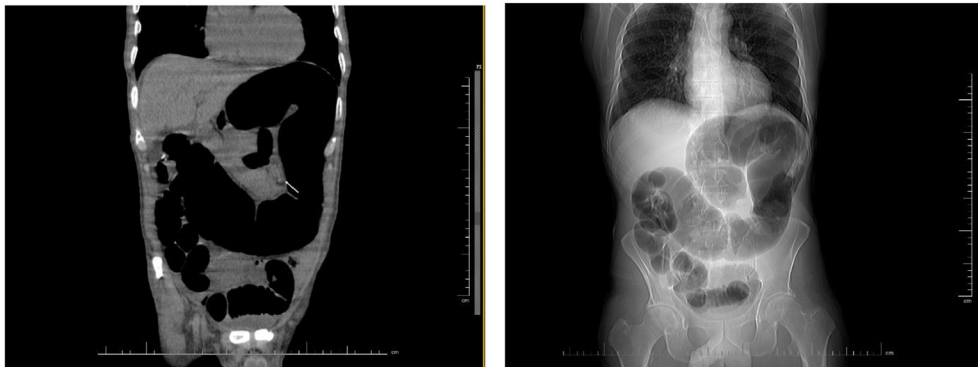

Figure 1: Appearance of CT scan.



**Figure 2:** Transverse colonic volvulus appearance at laparotomy.

This factor was observed in our patient, who was suffering from sigmoid volvulus when he was 73 years old.

Other predisposing factors are long mesentery of the transverse colon, a surgical intervention that may translocate the bowel, cancers, pregnancies, and congenital bowel defects.<sup>5–7</sup> Moreover, chronic constipation distends the large bowel, so it is the major risk factor of transverse colon volvulus.<sup>8</sup> Also, a case report with the same scenario mentioned hypoactivity of the right colon, inflammatory diseases like Crohn disorder, strictures, cancers, and psychiatric and neurologic diseases as predisposing factors.<sup>9</sup> Furthermore, in another case report in which simultaneous colonic volvulus was discussed, ulcerative colitis was mentioned as a predisposing factor.<sup>10</sup> These different risk factors are related to each other and have a synergistic effect in causing large bowel volvulus.

Surgical treatment of colonic volvulus is dependent on its presentation and location in the large bowel. Colonoscopic desufflation in cases of sigmoid volvulus is a simple procedure that stabilizes patients for elective sigmoid resection surgery. However, because our case showed ischemia, necrosis of the bowel, and poor condition, emergency sigmoidectomy was a preferred intervention over colonoscopic desufflation and elective sigmoidectomy surgery. A randomized controlled trial that discussed different surgical interventions of colonic volvulus reported that primary resection of volvulus (90%) was more successful than mesosigmoidopexy for patients with sigmoid volvulus (71.5%).

Nevertheless, if patients show signs of ischemia, resection with colostomy is the preferred surgical intervention, rather than resection with primary anastomosis (87.5% versus 50%), is associated with a two times lower mortality rate.

Colopexy has also been mentioned as a treatment intervention for volvulus of the transverse colon. However, resection surgery seems to be the treatment of choice in these patients as well.<sup>11</sup>

## Conclusion

Metachronous volvulus of the colon is a scarce condition and has a high mortality rate. Its diagnosis can be difficult, so surgeons must be very careful not to miss these cases

requiring urgent surgical intervention. Otherwise, patients may die due to a high risk of bowel gangrene and septic shock.

## Source of funding

This research did not receive any specific grant from funding agencies in the public, commercial, or not-for-profit sectors.

## Conflict of interest

The authors have no conflict of interest to declare.

## Ethical approval

The authors confirm that this report has been prepared in accordance with COPE roles and regulations.

## Consent

Informed consent was taken from the patient for this case report publication and any accompanying images.

## Authors contributions

SAMY conceived and designed the analysis and collected the data. FCS and HA contributed to the data and wrote the initial paper. All authors have critically reviewed and approved the final draft and are responsible for the content and similarity index of the manuscript.

## References

1. Baiu I, Shelton A. Sigmoid volvulus. *Jama* 2019; 321(24): 2478.
2. Cameron JL, Cameron AM. *Current surgical therapy*. Elsevier Saunders; 2011.
3. Motsumi MJ, Tlhomelang O. Synchronous volvulus of the sigmoid and transverse colon in a 26-year-old male. *J Surg Case Rep* 2018; 2018(11): rjy295.

4. Fishman EK, Goldman SM, Patt PG, Berlanstein B, Bohlman ME. Transverse colon volvulus: diagnosis and treatment. *South Med J* 1983; 76(2): 185–189.
5. Ciraldo A, Thomas D, Schmidt S. A case report: transverse colon volvulus associated with chilaiditis syndrome. *Internet J Radiol* 2000; 1(1).
6. Tobinaga S, Morinaga A, Sajima S, Kanazawa N, Yoshida T. Transverse to descending colon volvulus and megacolon with mesenterium commune: report of a case. *Surg Today* 2004; 34(10): 875–877.
7. Deshmukh SN, Maske AN, Deshpande AP, Shende SP. Transverse colon volvulus with chilaiditis syndrome. *Indian J Surg* 2010; 72(4): 347–349.
8. Franco MC, Solanas JG, Marco CA, Rodrigo MB, Diez MM. Intestinal occlusion secondary to transverse colon volvulus. *Rev Esp Enferm Dig* 2005; 97(12): 914.
9. Eldirdiri S, Musa IH, Adam HY, Suliman AG, Elmanan MMA, Eldirdiri S, et al. Transverse colonic volvulus after resection of sigmoid volvulus: presentation of a case report. *Int J Surg Case Rep* 2019; 60: 257–260.
10. Katsanos K, Ignatiadou E, Markouizos G, Doukas M, Siafakas M, Fatouros M, et al. Non-toxic megacolon due to transverse and sigmoid colon volvulus in a patient with ulcerative colitis. *J Crohns Colitis* 2009; 3(1): 38–41.
11. Booij K, Tanis P, Van Gulik T, Gouma D. Recurrent volvulus of the transverse colon after sigmoid resection. *Int J Colorectal Dis* 2009; 24(4): 471–472.

**How to cite this article:** Chinisaz F, Asefi H, Miratashi Yazdi SA. Volvulus of the transverse colon after resection of the sigmoid volvulus: A case report. *J Taibah Univ Med Sc* 2022;17(4):626–629.