

## Case Report

## Cervical leiomyosarcoma in a teenage girl: A rare form of uterine leiomyosarcoma<sup>☆</sup>



Adebayo A. Adewole, FWACS<sup>a,\*</sup>, Temitope G. Onile, FWACS<sup>a</sup>,  
Austin O. Ugiagbe, FWACS<sup>a</sup>, Oluwaseyi O. Fadahunsi, FMCPATH<sup>b</sup>,  
Daniel I. Awelimobor, FMCPATH<sup>b</sup> and Omotayo Akinro, FWACS<sup>a</sup>

<sup>a</sup> Department of Obstetrics and Gynecology, Federal Medical Center, Lokoja, Nigeria

<sup>b</sup> Department of Histopathology and Morbid Anatomy, Federal Medical Center, Lokoja, Nigeria

Received 29 June 2021; revised 1 October 2021; accepted 10 October 2021; Available online 14 November 2021

### المخلص

الساركوما التي تنشأ من عنق الرحم نادرة وتتراوح نسبة انتشارها ما بين 0.20% و0.55%. طالبة في مدرسة ثانوية تبلغ من العمر 15 عاماً، لم يسبق لها الحمل، تعرضت لصدمة مع تاريخ مرضي مدته عام واحد من نتوء مهبلي غير مؤلم، ونزيف مهبلي، وإفرازات مهبلية كريهة الرائحة، وتكتلات دموية في بعض الأحيان، وتعب، ونوبات إغماء، وفقدان الوزن. تم إنعاشها بالسوائل الوريدية ونقل الدم. كشف الفحص العام عن وجود كتلة في البطن بحجم 16 أسبوعاً. كشف الفحص المهبلي عن وجود كتلة لحمية كبيرة متحركة بحجم 14 سم × 10 سم مع إفرازات ورائحة كريهة. كانت قابلة للتفتيت من الخارج وتنزف بشكل نشط عند التلامس، ومناطق نخر أنسجة، مع وذمة. كان من الصعب فحص ملحقات الرحم بسبب الألم. أظهر الفحص تحت التخدير أن الكتلة كانت متصلة بعنق الرحم ولم تكن ملتصقة بالمهبل أو الفرج. أظهر تقرير علم الأنسجة لعينات الخزعة ميزات تتفق مع الساركومة العضلية الملساء لعنق الرحم. تم تأكيد الساركومة العضلية الملساء العنقية عن طريق اختبار الكيمياء النسيجية المناعية وتم استئصال الرحم الكلي واستئصال البوق والمبيض الثنائي كعلاج نهائي. بدأت المريضة في العلاج بالهرمونات البديلة بعد الجراحة. كانت حالة ما بعد الجراحة مستقرة ولم يكن هناك تكرار للورم لأكثر من عامين من المتابعة. بعد تشخيص ووضع علاجات جراحية لمرضى الساركومة العضلية الملساء من التحديات الصعبة في بيئة منخفضة الموارد، بسبب عدم توفر تغطية صحية شاملة. يعطي النهج متعدد

التخصصات مع التشخيص المبكر والاستئصال الجراحي الكامل للورم فرصة أكبر للبقاء على قيد الحياة والحفاظ على جودة الحياة.

**الكلمات المفتاحية:** ساركومة العضلية الملساء؛ الفحص المهبلي؛ استئصال الرحم؛ اختبار الكيمياء النسيجية المناعية؛ استئصال البوق والمبيض الثنائي

### Abstract

Sarcomas arising from the cervix are rare, and the reported prevalence is 0.20–0.55%. A 15-year-old Para 0<sup>+0</sup> secondary school student presented to the emergency department in shock with a 1-year history of painless vaginal protrusion, vaginal bleeding, foul-smelling vaginal discharge, occasional passage of blood clots, fatigue, fainting episodes, and weight loss. She was resuscitated with intravenous fluids and blood transfusions. General examination revealed a young girl with a 16-week sized abdominal mass. Vaginal examination revealed a large mobile fleshy mass 14 cm by 10 cm with an offensive discharge and odour. It was externally friable, bled actively on contact, had areas of tissue necrosis, and was oedematous. It was difficult to determine the adnexa structures because of tenderness. Examination under anaesthesia showed that the mass was continuous with the cervix and was not attached to the vagina or vulva. The histology report of the biopsied specimens showed features consistent with cervical leiomyosarcoma (LMS). Cervical LMS was confirmed by immunohistochemistry and a total abdominal hysterectomy and bilateral salpingo-oophorectomy were performed as definitive treatment. Postoperative hormone replacement therapy was initiated. The patient's postoperative condition was stable and there was no tumour recurrence for >2 years on follow-up. Making a diagnosis and

<sup>☆</sup> **Institution's Present/Permanent Address and where the work was done:** Federal Medical Centre Lokoja, No. 1, Saliu Ibrahim Way, PMB 1001, Lokoja, Kogi State, Nigeria.

\* Corresponding address: Fertility and Minimal Access Surgery Unit, Department of Obstetrics and Gynecology, Federal Medical Centre, No. 1, Saliu Ibrahim Way, PMB 1001, Lokoja, Kogi State, Nigeria.

E-mail: [adewoleobs gyn@hotmail.com](mailto:adewoleobs gyn@hotmail.com) (A.A. Adewole)

Peer review under responsibility of Taibah University.



Production and hosting by Elsevier

instituting surgical and adjuvant treatments for LMS in a low-resource setting are challenging. This is due to lack of access to universal healthcare coverage. A multidisciplinary approach with early diagnosis and complete surgical resection of the tumour provides the most favourable possibility of an improved survival and quality of life.

**Keywords:** Cervical leiomyosarcoma; Gynaecological malignancy; Hysterectomy; Immunohistochemistry; Salpingo-oophorectomy

© 2021 The Authors. Published by Elsevier B.V. This is an open access article under the CC BY-NC-ND license (<http://creativecommons.org/licenses/by-nc-nd/4.0/>).

## Introduction

Uterine sarcomas account for less than 3% of all uterine malignancies and less than 1% of all malignancies from the female genital tract.<sup>1,2</sup> In one Nigerian study, uterine sarcoma accounted for 0.5% and 4% of total malignancies and gynaecological malignancies, respectively.<sup>3</sup> These malignancies are classified according to various histological types. With the exclusion of carcinosarcoma, uterine leiomyosarcoma (uLMS) is the most common sub-type. It arises from myometrial smooth muscle cells and accounts for 1–2% of uterine malignancies.<sup>4–6</sup> include endometrial stromal sarcomas, which arise from the endometrial stroma, and undifferentiated sarcomas.

Uterine leiomyosarcoma (uLMS) is a rare, aggressive tumour of the female genital tract with a poor clinical outcome, high recurrence rate, and poor prognosis.<sup>1,6–9</sup> This tumour can either present as malignancy of the corpus uteri or cervix uteri. Approximately 5% are located in the cervix.<sup>10</sup> Sarcomas arising from the cervix are rare, and the reported prevalence is 0.2–0.55%.<sup>7,11</sup>

The clinical presentation includes vaginal protrusion, abnormal vaginal bleeding, a lower abdominal mass, and abdominal pain. The gold standard treatment for uLMS is surgery, total abdominal hysterectomy with bilateral salpingo-oophorectomy (TAH + BSO). This surgery must ensure a total resection of the uterus and tumour and avoid rupture or spillage of the tumour into the peritoneal cavity.<sup>2,6,8,12</sup> Pelvic and para-aortic dissection are not routinely recommended. Controversy remains regarding oophorectomy, adjuvant radiotherapy, and chemotherapy in young women.<sup>2,6,8,12</sup> We report a case of cervical LMS encountered in our centre.

## Case description

A 15-year-old Para 0<sup>+0</sup> secondary school student presented to our gynaecological emergency unit. She was in shock, severely pale with a pulse rate of 116 beats per minute, blood pressure of 80/50 mmHg, and SPO<sub>2</sub> 95%. This patient was resuscitated promptly with intravenous fluids. Three units of blood were transfused (PCV was 21% pre- and PCV

32% post-transfusion) and a thorough clinical evaluation was performed when her condition stabilised.

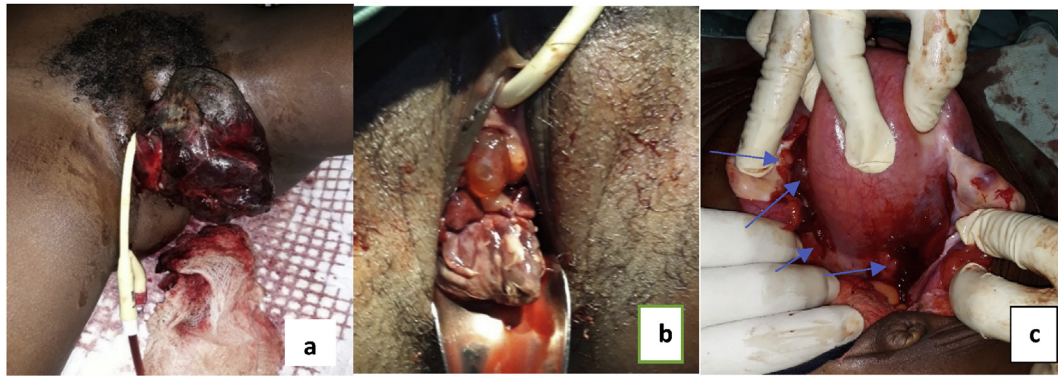
There was a 1-year history of painless vaginal protrusion, associated dysuria, urinary frequency, nocturia, intermittency, urgency, straining, and a feeling of incomplete bladder emptying. There was no previous history of haematuria. She manually pushed the protrusion to urinate with an attendant mild bleeding episode. There was associated lower abdominal pain and low back pain. The mass was excised in a private hospital, but specimens were not submitted for histology due to financial constraints.

A month after the first excision, she noticed a recurrence of the vaginal protrusion. It was larger in size and associated with more severe lower abdominal pain, low back pain, lower abdominal swelling, worsening urinary symptoms, and weight loss. There was associated significant vaginal bleeding with the passage of blood clots, fatigue, and fainting episodes, but no seizures. There was no bleeding from any other orifices. She passed watery, foul-smelling vaginal discharge. There was no cough, dyspnoea, orthopnoea, or paroxysmal nocturnal dyspnoea. There was no history of ingestion of local medicinal herbs, anorexia, vomiting, easy satiety, or jaundice. There was no leg or facial swelling. There was no previous history of sexual intercourse and no anal protrusion.

She experienced menarche at the age of 12 years. There was a history of primary dysmenorrhoea and menometrorrhagia. She had not used contraceptives in the past and had not had a Pap smear. Her last menstrual period was four weeks before presentation. There was no history of a chronic medical disorder and no known drug allergies. She was single, no history of cigarette smoking or alcohol use. There was no family history of a similar illness among first-degree relatives.

General examination revealed a young girl; afebrile (Temperature 36.5 °C), clinically pale, anicteric, acyanosed with no pedal oedema or peripheral lymphadenopathy. Cardiovascular and respiratory parameters were stable after initial resuscitation. The abdomen was full and moved with respiration with mild tenderness in both iliac fossa and suprapubic region. A 16-week sized tender; firm; mobile; abdominopelvic mass was palpable. There was no ascites or bruits over the mass. Bowel sounds were present and normoactive. A pelvic examination revealed a large mobile fleshy mass 14 cm by 10 cm with an offensive discharge and odour protruding from the vagina (Figure 1a and b). It was externally friable, bled actively on contact, had areas of tissue necrosis, and was oedematous. It was difficult to appreciate the adnexa structures due to tenderness.

A diagnosis of hypovolaemic shock with a degenerated leiomyoma/cervical polyp was made to rule out cervical carcinoma. Other differential diagnosis entertained included uterine and cervical sarcoma. A multidisciplinary team (MDT) intervention was initiated that included a gynaecologist, haematologist, gynaecological, medical oncologist, urologist, behavioural scientist, and a medical/social worker. The patient was admitted to the gynaecological emergency unit. Intranasal oxygen was administered at 6 L/min and an indwelling urethral catheter was inserted to empty the urinary bladder and monitor urine output. The urine was



**Figure 1:** Tumour appearance at presentation (a) before and (b) after EUA biopsy, (c) intraoperative findings, tumour seedlings marked with blue arrows.

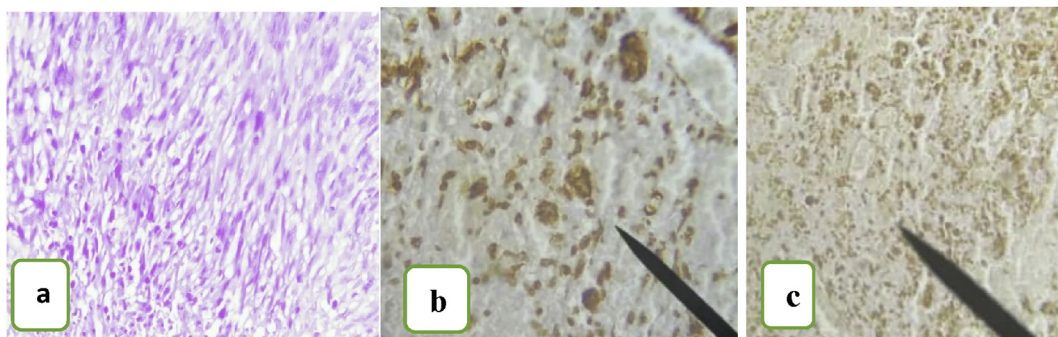
blood-stained but was clear after resuscitation. Broad-spectrum antibiotics were prescribed, and she experienced pain relief with administered analgesics. The report of abdominopelvic USS was not remarkable apart from the bulky uterus. Colour flow Doppler noted high vascularity. Computed tomography (CT) was recommended; however, the patient could not afford the cost (\$225).

Examination under anaesthesia (EUA) was performed in the operating theatre. In addition to the findings on vaginal examination, the mass was continuous with the cervix. It was not attached to the vagina or vulva. The bulky mass made it difficult to palpate the adnexa and POD. A tissue biopsy was obtained and sent for histopathology. The urethral catheter was removed after 24 h when the urine was clear. Oral antibiotics, analgesics, and hematinics were initiated.

Histology results showed features consistent with *cervical leiomyosarcoma*; tumour grade (Grade 2 = *Cytologic atypia with more nuclear irregularity*) (Figure 2) and tumour-free margins were also noted by the pathologist. Immunohistochemistry further confirmed the diagnosis (Figure 2). Counselling sessions for the patient and her parents took place with the MDT. They were informed regarding the clinical findings, histology, and the immunohistochemistry report (Cervical Leiomyosarcoma). The definitive management option (TAH with or without bilateral salpingo-oophorectomy) was outlined. The implications of the surgery on her reproductive potential, psyche, long-term hypo-oestrogenic complications of bilateral oophorectomy,

and the possibility of long-term hormone replacement therapy (HRT) were discussed. Other possible reproductive options before and after the definitive surgery (oocyte, embryo and ovarian cryo-banking, surrogacy, and adoption) including cost implications were also discussed. However, there was a financial constraint and the family could not afford the fertility-preserving measures. Social healthcare workers were involved to assist the parents with the financial challenges. The management team ensured that the patient and her parents understood every step of the counselling process. Preoperative preparation was completed and consent was obtained for surgery. Preoperative investigations FBC, E&U/Cr, FBS, LFT, clotting profile, Viral screening, and CX-Ray were normal.

A staging laparotomy (FIGO Stage IIA), and TAH + BSO was performed. All tumours were completely resected. Operative findings included a 16-week sized bulky uterus. Seedlings were seen breaking through the uterovesical peritoneum anteriorly, ovarian ligaments laterally, uterosacral ligaments, and the rectovaginal peritoneum posteriorly (Figure 1c). The fallopian tubes, ovaries, and urinary bladder were normal. The pelvic and para-aortic lymph nodes were not enlarged. The intestines, liver, spleen, paracolic gutters, subphrenic angles, and Pouch of Douglas were normal and free of tumour. Estimated blood loss was 600 mL. There were no intraoperative complications.



**Figure 2:** Photomicrographs showing: (a) cytologic atypia with more nuclear irregularity, spindle-shaped pleomorphic cells with blunted ends disposing of in fascicles, H&E  $\times 10$  magnification (b) positivity for caldesmon on immunohistochemistry,  $\times 40$  magnification (c) smooth muscle actin (SMA) on immunohistochemistry,  $\times 40$  magnification.



The patient remained stable postoperatively, received prophylactic antibiotics, and analgesics. The urethral catheter was removed 24 h post-surgery and she was ambulated. The postoperative PCV was 35%. She developed a superficial wound infection on the fifth postoperative day and was managed with wound dressings and antibiotics. The counselling and communication process continued postoperatively by informing the patient and her parents regarding the extent of the surgery and the importance of adjuvant chemotherapy/radiotherapy. Adjuvant therapies were declined for financial reasons. HRT was initiated to mitigate the hypo-oestrogenic effects of the bilateral oophorectomy. She was discharged home on the 10th-day post-operation for follow-up at the clinic. Follow-up was scheduled every 3 months with a clinical history, clinical examination, and pelvic ultrasonography for 2 years. Chest and abdominal X-Rays were completed every 6 months. There was no recurrence for more than 2 years. Baseline liver and renal function tests, and coagulation profiles were performed and monitored for latent effects of treatment and there were no serious abnormalities.

## Discussion

Uterine leiomyosarcoma is characterised as a rapidly growing tumour with a poor prognosis. The median age at presentation is 47–56 years. However, the age range has been reported to vary widely between 22 and 89 years.<sup>2,3,6</sup> This case was therefore unique as it occurred in a teenage girl. Although there is a lack of consensus regarding the risk factors. Several factors have been reported to increase the risk of developing leiomyosarcoma.<sup>2,12</sup> They include a history of pelvic radiation, tamoxifen exposure, nulliparity, increasing age, and obesity.<sup>2,12</sup> In this case, nulliparity was the only recognised factor.

Our patient presented with a vaginal protrusion, vaginal bleeding, lower abdominal and back pain, abdominal swelling, urinary symptoms, and weight loss. These findings are like reports from other authors.<sup>1–8,12</sup> Apart from a history and physical examination, imaging techniques play an important role in confirming the diagnosis. Preoperative CT, positron emission tomography, contrast-enhanced MRI, diffusion-weighted MRI have been reported to be useful in differentiating between ordinary leiomyomas, leiomyoma variants, and LMS. However, no conclusion has been reached regarding their diagnostic accuracy.<sup>2</sup>

In this patient, pelvic ultrasonography with coloured Doppler interrogation suggested a cervico-uterine malignancy. These techniques are adequate to rule out leiomyoma. However, they are not specific for uterine leiomyosarcoma (uLMS) and other potential differential diagnoses. A further evaluation with a CT scan would have been helpful for diagnosis and treatment planning. However, it could not be performed due to financial reasons. Unfortunately, most individuals in this environment access healthcare through out-of-pocket expenses. They often resigned to traditional/unorthodox care when the cost of conventional healthcare becomes too high. Therefore, EUA and biopsy, more accessible and inexpensive diagnostic tools, were performed to establish the diagnosis. Histopathologic examination of the excised cervical mass showed a high mitotic count, presence of coagulative tumour cell necrosis, and cytological

atypia, which differentiates leiomyosarcoma from leiomyoma (Figure 2a). To further confirm the diagnosis, immunohistochemistry was performed (Figure 2b and c). This is essential considering the implications of the surgical treatment on this teenager.

It is universally accepted that surgery is the primary treatment option for uterine leiomyosarcoma.<sup>2,6,8,12</sup> In this young woman with early-stage disease, the authors are mindful of the fact that the best chance of obtaining a cure is with the primary treatment. For these reasons she underwent staging laparotomy (FIGO Stage IIA), peritoneal washing, and a total abdominal hysterectomy with bilateral salpingo-oophorectomy.<sup>1,2,12</sup> There was complete tumour resection in one specimen bloc and tumour-free margins on histopathology. This is expected to improve her survival.<sup>1,2,12</sup> Current evidence showed that ovarian conservation (OC) could be considered for FIGO Stage I disease.<sup>2,13</sup> However, in this case, an OC was not performed. This was due to the high risk of residual disease with micro-metastasis to distant organs from Stage 2 disease and the possibility of a poor prognosis. Oocyte and ovarian tissue cryopreservation were also an option. However, this possibility was beyond the financial reach of the patient and her parents.<sup>2,14</sup> In some developed countries, oocyte and ovarian tissue cryopreservation are free for medical reasons through direct state funding.<sup>14</sup> In Nigeria, oocyte cryopreservation can only be assessed through out-of-pocket expenses and it is expensive. The authors are also not aware of any centre in Nigeria where ovarian tissue cryopreservation and retransplantation are performed. In contrast, recurrence of LMS is a concern should oocyte and ovarian tissue cryopreservation be considered. Third-party reproduction with donor eggs remains the primary reproductive option for this patient in the future.<sup>14</sup> Adoption is the last option for her should she desire to have children.

Although this treatment remains controversial, the patient was counselled regarding the role of adjuvant radiotherapy/chemotherapy for patients who have had a complete resection of their disease. However, the family could not afford this treatment.<sup>2</sup> Despite the delay in diagnosis and the initiation of proper treatment protocols, this young woman has a fair chance of survival considering the stage of the disease, tumour grade, prognostic factors, radical treatment offered, and achieving follow-up for 2 years without recurrence. Follow-up will continue twice a year for the next 5 years and yearly for 10 years and beyond. Pelmus and colleagues reported a 5-year overall survival of 57% and 50% for stages I and II disease, respectively.<sup>15</sup> Tumour stage is considered the greatest prognostic factor followed by tumour grade.<sup>2,12</sup> In this case, findings at staging laparotomy revealed a FIGO Stage IIA (tumour extending beyond the uterus but limited to the pelvic cavity with adnexal involvement only). The grade of the tumour (Grade 2) was determined by the pathologist using Broder's system that incorporates tumour differentiation, mitotic count, and tumour necrosis.<sup>2</sup> It is one of the frequently used grading systems for uLMS.<sup>2</sup> The other grading system, Federation Nationale des Centres de Lutte Contre le Cancer divides soft tissue sarcoma into three groups based on tumour cell necrosis, mitoses, and degree of differentiation.<sup>10</sup> Other prognostic factors include tumour size, age, vascular space involvement, mitotic

count, residual disease at surgery, and adjuvant chemotherapy.<sup>2,6–10,12</sup> A tumour size of 5 cm or more, infiltration, high-grade cytologic features, mitotic rate of 1/50 or more high-power fields, necrosis, or lymphovascular invasion predicts an adverse outcome.

## Conclusion

Arriving at a diagnosis and instituting surgical and adjuvant treatments for LMS in a low-resource setting are challenging. This is due to a lack of access to universal healthcare coverage. Although findings from a case report cannot be extrapolated to the general population, a multidisciplinary approach with early diagnosis and complete surgical resection of LMS provides the most favourable possibility of improved survival and quality of life.

**Abbreviations:** BSO, Bilateral salpingo-oophorectomy; CT, Computed Tomography; CX-Ray, Chest X-Ray; EUA, Examination Under Anaesthesia; E&U/Cr, Electrolyte and Urea/Creatinine; FBC, Full Blood Count; FIGO, International Federation of Gynaecology and Obstetrics; FBS, Fasting Blood Sugar; HRT, Hormone Replacement Therapy; LFT, Liver Function Test; LMS, Leiomyosarcoma; MDT, Multidisciplinary Team; MRI, Magnetic Resonance Imaging; OC, Ovarian Conservation; PCV, Packed Cell Volume; POD, Pouch of Douglas; SPO<sub>2</sub>, Partial Pressure of Oxygen; TAH, Total Abdominal Hysterectomy; uLMS, Uterine Leiomyosarcoma; USS, Ultrasound Scan.

## Source of funding

This research did not receive any specific grant from funding agencies in the public, commercial, or not-for-profit sectors.

## Conflict of interest

The authors have no conflict of interest to declare.

## Ethical approval

The study was approved by the ethical review board of the hospital on 22<sup>nd</sup> April 2021 (FMCL/HREC/VOL1/2021/130), complied with the Declaration of Helsinki. Informed consent was obtained from the patient's parents prior to surgery as she was a minor at that time. Consent included permission to collect surgical information and use the patients' specimens, photographs, photomicrographs, and videos for any study (17<sup>th</sup> September 2018).

## Authors contributions

AAA, OA, OOF conceived and designed the study. AAA, TGO, AOU, OA performed surgery and delivered clinical care to the patient. OOF and DIA performed histological and immunochemistry investigations and provided the report and microphotographs used for the article. AAA and OA provided other research materials, collected, and organised the materials used in writing the article. AAA wrote the initial draft of the article and provided logistic

support. All authors have critically reviewed and approved the final draft and are responsible for the content and similarity index of the manuscript.

## Acknowledgment

The authors acknowledge the contributions of the resident doctors, nursing staff, and the social/welfare officers who contributed to the management of this patient.

## References

1. Fadare O. Heterologous and rare homologous sarcomas of the uterine corpus: a clinicopathologic review. *Adv Anat Pathol* **2011**; 18(1): 60–74. <https://doi.org/10.1097/PAP.0b013e3182026be7>.
2. Wen KC, Horng HC, Wang PH, Chen YJ, Yen MS, Ng HT, Taiwan Association of Gynecology Systematic Review Group. Uterine sarcoma Part 1 – uterine leiomyosarcoma: the topic advisory group systematic review. *TJOG* **2016**; 55: 463–471. <https://doi.org/10.1016/j.tjog.2016.04.033>.
3. Seleye-Fubara D, Uzoigwe SA. Uterine sarcomas in Port Harcourt, Nigeria A 12-year clinic-pathologic study. *Afr Health Sci* **2007**; 7(1): 10–13. <https://doi.org/10.5555/afhs.2007.7.1.10>.
4. Wright JD, Rosenblum K, Huettner PC, Mutch DG, Rader JS, Powell MA, et al. Cervical sarcomas: an analysis of incidence and outcome. *Gynecol Oncol* **2005**; 99(2): 348–351.
5. Buttram Jr VC, Reiter RC. Uterine leiomyomata: etiology, symptomatology, and management. *Fertil Steril* **1981**; 36(4): 433–445. [https://doi.org/10.1016/s0015-0282\(16\)45789-4](https://doi.org/10.1016/s0015-0282(16)45789-4).
6. D'Angelo E, Prat J. Uterine sarcomas: a review. *Gynecol Oncol* **2010**; 116: 131–139. <https://doi.org/10.1016/j.ygyno.2009.09.023>.
7. Wang WL, Soslow R, Hensley M, Asad H, Zannoni GF, de Nictolis M, et al. Histopathologic prognostic factors in stage I leiomyosarcoma of the uterus: a detailed analysis of 27 cases. *Am J Surg Pathol* **2011**; 35: 522–529. <https://doi.org/10.1097/PAS0b013e31820ca624>.
8. Giuntoli 2nd RL, Metzinger DS, DiMarco CS, Cha SS, Sloan JA, Keeney GL, et al. Retrospective review of 208 patients with leiomyosarcoma of the uterus: prognostic indicators, surgical management, and adjuvant therapy. *Gynecol Oncol* **2003**; 89(3): 460–469. [https://doi.org/10.1016/s0090-8258\(03\)00137-9](https://doi.org/10.1016/s0090-8258(03)00137-9).
9. Abeler MV, Royne O, Thoresen S, Danielsen HE, Nesland JM, Kristensen GB. Uterine sarcomas in Norway. A histopathological and prognostic survey of a total population from 1970 to 2000 including 419 patients. *Histopathol* **2009**; 54(3): 355–364. <https://doi.org/10.1111/j.1365-2559.2009.03231.x>.
10. Denschlag D, Thiel FC, Ackermann S, Harter P, Juhasz-Boess I, Mallmann P, et al. Sarcoma of the uterus. Guideline of the DGGG (S2k-Level, AWMF Registry No. 015/074, August 2015). *Geburtshilfe Frauenheilkd* **2015**; 75: 1028–1042. <https://doi.org/10.1055/s-0035-1558120>.
11. McCluggage W. Malignant biphasic uterine tumors: carcinosarcomas or metaplastic carcinomas. *J Clin Pathol* **2002**; 55: 321–325. <https://doi.org/10.1136/jcp.55.5.321>.
12. Harry VN, Narayansingh GV, Parkin DE. Uterine leiomyosarcomas: a review of the diagnostic and therapeutic pitfalls. *Obstet Gynecol* **2007**; 9: 88–94. <https://doi.org/10.1576/toag.9.2.088.27309>.
13. Nasioudis D, Chapman-Davis E, Frey M, Holcomb K. Safety of ovarian preservation in premenopausal women with stage I uterine sarcoma. *J Gynecol Oncol* **2017**; 28(4): e46. <https://doi.org/10.3802/jgo.2017.28.e46>.
14. The ESHRE Working Group on Oocyte Cryopreservation in Europe, Shenfield F, de Mouzon J, Scaravelli G, Kupka M,

- Ferraretti AP, Prados FJ, et al. Oocyte and ovarian tissue cryopreservation in European countries: statutory background, practice, storage, and use. **Hum Reprod Open** 2017: 1–9. <https://doi.org/10.1093/hropen/hox003>.
15. Pelmus M, Penault-Llorca F, Guillou L, Collin F, Bertrand G, Trassard M, et al. Prognostic factors in early-stage leiomyosarcoma of the uterus. **JIGCS** 2009; 19: 385–390. <https://doi.org/10.1111/IGC.0b013e3181a1bfbfbc>.

**How to cite this article:** Adewole AA, Onile TG, Ugiagbe AO, Fadahunsi OO, Awelimobor DI, Akinro O. Cervical leiomyosarcoma in a teenage girl: A rare form of uterine leiomyosarcoma. *J Taibah Univ Med Sc* 2022;17(3):523–528.