

Hepatoprotective Activity of *Cordia lutea* Lam Flower Extracts Against Paracetamol-Induced Hepatotoxicity in Rats

Ruiz-Reyes SG, Villarreal-La Torre Víctor E*, Silva-Correa Carmen R, Sagástegui Guarniz William Antonio, Cruzado-Razco José L, Gamarra-Sánchez César D, Venegas Casanova Edmundo A, Miranda-Leyva Manuel, Valdiviezo Campos Juan Ernesto, Cuellar-Cuellar Armando

Ruiz-Reyes SG, Villarreal-La Torre Víctor E*, Silva-Correa Carmen R, Sagástegui Guarniz William Antonio, Cruzado-Razco José L, Gamarra-Sánchez César D, Venegas Casanova Edmundo A, Miranda-Leyva Manuel, Valdiviezo Campos Juan Ernesto, Cuellar-Cuellar Armando

Universidad Nacional de Trujillo, PERÚ.

Correspondence

Villarreal-La Torre Víctor E

Facultad de Farmacia y Bioquímica,
Universidad Nacional de Trujillo, PERÚ.

E-mail: vvillarreal@unitru.edu.pe

History

- Submission Date: 30-10-2020;
- Review completed: 02-12-2020;
- Accepted Date: 08-12-2020.

DOI : 10.5530/pj.2021.13.40

Article Available online

<http://www.phcogj.com/v13/i2>

Copyright

© 2021 Phcogj.Com. This is an open-access article distributed under the terms of the Creative Commons Attribution 4.0 International license.

ABSTRACT

Background: Paracetamol or acetaminophen overdose leads to hepatotoxicity. This study evaluates the effect of *Cordia lutea* extract on paracetamol-induced hepatotoxicity in rats. **Methods:** Three different doses of dry fluid extract of *C. lutea* (200, 400 and 600 mg / Kg) were evaluated and compared with Silymarin 200 mg / Kg. Biochemical parameters such as alanine aminotransferase (ALT), aspartate aminotransferase (AST), alkaline phosphatase (ALP), direct bilirubin, indirect bilirubin, total bilirubin, albumin, globulin and total proteins were evaluated, and histopathological changes in the liver were studied and evaluated. **Results:** *C. lutea* reduced the levels of ALT, AST, ALP and increases proteins significantly, although the reduction of bilirubin was not significant, the extract at 400 mg / Kg reduced the levels better than the extract at 600 mg / Kg. The histopathological evaluation suggested that *C. lutea* extract reduced paracetamol-induced liver necrosis. **Conclusions:** The extract of *C. lutea* has a marked hepatoprotective effect, significantly reducing the levels of ALT, AST and ALP, in addition to increasing the levels of albumin, globulin and total proteins, in *Rattus norvegicus* var. *albinus*. *C. lutea* extract is an excellent candidate for use in paracetamol-induced liver diseases.

Key words: *Cordia lutea*, Paracetamol, Acetaminophen, Hepatoprotection, Biochemical parameters, Histopathology.

INTRODUCTION

Although the World Health Organization ranks paracetamol or acetaminophen as one of the essential drugs, the overdose of this drug can cause acute liver failure and even death.^{1,2}

The metabolic functions of the liver are important for the elimination of waste, the accumulation of which causes complications to the body.³ The absence of reliable hepatoprotective drugs makes it necessary to search for medicinal plants with this pharmacological property.⁴⁻⁶

In the northern region of Peru, more than 500 plants are traditionally used for medicinal purposes^{7,8} and, *Cordia lutea* L. "overo" is an indigenous plant used to treat liver diseases on the northern Peruvian coast.⁹ Traditionally this plant species is part of an effective and safe treatment to enhance liver function.¹⁰ It has also protective activity on the gastric mucosa¹¹, anti-infective activity¹² and anticancer¹³, as well as antiallergic activity.¹⁴ Some other species of the genus *Cordia* L. have demonstrated antibacterial and antioxidant activities.^{15,16}

Although the hepatoprotective efficacy of *Cordia lutea* (*C. lutea*) has been studied, it has only been demonstrated in a mixture of a Peruvian Botanical Remedy, with *Curcuma longa* rhizome and *Annona muricata* leaf, so the activity corresponds to the mixture and not to *C. lutea* alone¹¹, likewise, the

determination has not been made of the biochemical and histopathological values of the test species.

Preclinical trials of *C. lutea* are limited⁹ and molecularly there are only reports of norcycloartan and rutin glycosides^{12,17}, so studies that support this traditional activity is of great importance, a scientific void that this article tries to cover.

METHODS

Vegetable material

The flowers of *Cordia lutea* Lam. were collected in the province of Cajamarca, Peru. The deposit of the plant was registered with the *Herbarium Truxillense* (HUT) of the Universidad Nacional de Trujillo, Peru with the code N° 33425.

Preparation of the extract

The flowers were washed and dried in the environment, they were homogenized to a fine powder and then stored in an amber glass container. Two hundred grams of fine powder and ethyl alcohol 70 °GL were used for the preparation of fluid extract using leaching equipment, macerating for 72 hours. After the maceration period, 75% of the fluid extract was percolated at a constant rate of XX drops/min, storing the extract in an amber colored bottle. Percolation continued until the ferric trichloride test on an aliquot of the extract was negative. The extract

Cite this article: Ruiz-Reyes SG, Villarreal-La Torre VE, Silva-Correa CR, Sagástegui Guarniz WA, Cruzado-Razco JL, Gamarra-Sánchez CD, et al. Hepatoprotective Activity of *Cordia lutea* Lam Flower Extracts Against Paracetamol-Induced Hepatotoxicity in Rats. *Pharmacogn J.* 2021;13(2): 309-16.

was concentrated by rotary evaporation, obtaining 100 mL of fluid extract. Finally, it was filtered through a vacuum pump and dried in a stove at 40 °C. It was stored in an amber colored bottle.¹⁸

Chemicals

Sodium chloride and Silymarin were obtained from commercial pharmaceutical products, being Silymarin obtained from Genfar® and sodium chloride from Medifarma®. On the other hand, 37% reactive grade formaldehyde was from Merck® and chemically pure Paracetamol was from Sigma-Aldrich.

Animals

Rattus norvegicus var. albinus of both sexes (220 - 250 g) of two and a half months of age were obtained from the Instituto Nacional de Salud (INS) - Sanitary Certificate N° 029-2019. All specimens were kept in standard plastic cages in the animal facility of the Facultad de Farmacia y Bioquímica, Universidad Nacional de Trujillo. The animals were conditioned in a standard environment of photoperiod (12:12 h dark: light cycle) and temperature [(25 ± 2) °C]. They were provided with water ad libitum and food purchased from the INS (6). This study was approved by the ethics committee of the Facultad de Farmacia y Bioquímica of the Universidad Nacional de Trujillo under opinion N° PR003-018 / CEIFYB.

Hepatoprotective evaluation

The rats were divided into six groups of six rats in each group. Group I (normal rat) received only the vehicle (sterile water 10 mL / Kg of body weight p.o.) for 5 days. Group II (Paracetamol) received paracetamol (1000 mg/kg, oral, positive control) for 5 days. Group III (Paracetamol + Silymarin) rats with paracetamol-induced hepatotoxicity treated with silymarin (200 mg/Kg, oral). Group IV (*C. lutea* 200) rats with paracetamol-induced hepatotoxicity treated with *C. lutea* 200 mg/Kg. Group V (*C. lutea* 400) rats with paracetamol-induced hepatotoxicity treated with *C. lutea* 400 mg/Kg. Group VI (*C. lutea* 600) rats with paracetamol-induced hepatotoxicity treated with *C. lutea* 600 mg/Kg. The animals were sacrificed 48 h after the last administration of paracetamol under mild anesthesia with Ketamine 10%. Blood and liver were collected from each animal.^{6,19}

Estimation of biochemical parameters

The biochemical parameters were determined with the separated serum. Levels of alanine aminotransferase (ALT), aspartate aminotransferase (AST), alkaline phosphatase (ALP), direct bilirubin, indirect bilirubin, total bilirubin, globulin and total proteins were determined. The absorbance of all parameters was measured in a Persee T7 UV-VIS spectrophotometer.

Histopathological study

The livers were treated as described in Sagástegui-Guarniz WA, et al (2020) (6).

Statistical analysis

The data obtained from the animal experiment are expressed as mean ± SD. The graphs were prepared using Microsoft Excel® and the data were subjected to an analysis of variance (ANOVA) followed by the post-Hoc Tukey test. To evaluate individual variations between the control and treatment groups, p<0.05 was considered statistically significant.

RESULTS

Serum biochemical analysis

The comparison of the biochemical parameters is shown in Figure 1. The levels of ALT, AST, ALP, albumin and total protein in Group II show significant alteration compared to Group I.

The groups that received treatment with *C. lutea* significantly decreased ALT and AST levels, only Groups V and VI (400 and 600 mg of extract / Kg, respectively) significantly decreased ALP, this difference was also significant with Group III (Silymarin). There was no significant difference with Group I (normal rat).

Although there is a difference in bilirubin levels, they are not statistically significant (p> 0.05). The groups that received *C. lutea* extract significantly increased the levels of albumin and total proteins compared to Group II (rat paracetamol-induced hepatotoxicity), besides, they did not show significant difference with Group I (normal rat) or Group III (Silymarin).

Histopathological changes

Liver lesions decreased with the administration of *C. lutea* extract (Figure 2) compared to the other groups. Group I (Normal rat - Section A) shows that, radially to the central vein (VC), flow cords or hepatocyte plates (inset), including the dilated sinusoids (*) indicative of the activity; the contour and shape of hepatocytes with stained nuclei and cytoplasm (arrows) characteristic of normal tissue are maintained. Group II (Negative control - Section B) shows the presence of several hepatocytes in a degenerative state and cell death or necrosis, some of a powdery and swollen appearance (arrows), the presence of Kupffer cells (ck) and some pyknotic nuclei; change attributed to paracetamol-induced hepatotoxicity. Group III (Treatment with Silymarin - Section C) shows that most hepatocytes show normal architecture (arrows), some swollen (*) some necrotic hepatocytes (n+); the image describes slight regeneration attributable to the hepatoprotective effect of silymarin. In Group IV (Treatment with *C. lutea* 200 mg/Kg - Section D) many hepatocytes show a normal nucleus, nucleolus and cytoplasm, some in necrosis (arrows) and others with fat droplets that displace the nucleus towards the periphery (*) effects attributable to paracetamol; by the recovery of hepatocytes, it is deduced that *C. lutea* in low dose has a slight effect in the treatment of toxic conditions. Group V (Treatment with *C. lutea* 400 mg/Kg - Section E) shows most of the normal-appearing hepatocytes arranged in a radial arrangement (inset) to the central vein (VC), few hepatocytes in necrosis (arrows) and some in pyknosis (*), it is generally appreciated that *C. lutea* at a dose of 400mg/kg has a hepatoprotective effect. Group VI (Treatment with *C. lutea* 600 mg/Kg - Section F) shows regeneration of hepatocytes arranged around the central vein (CV), minimal residual hepatotoxic effect by paracetamol (arrows) and dilation of sinusoids (*).

DISCUSSION

C. lutea extract shows hepatoprotective activity against paracetamol. Paracetamol is an antipyretic agent that is safe at therapeutic doses but can produce hepatotoxicity in humans and rats if the dose is increased^{20,21}; therefore, multiple investigations have used paracetamol to search for new agents with hepatoprotective activity.^{3,22-24}

Paracetamol administered to rats increases the levels of AST, ALT, ALP and all bilirubin (direct, indirect and total), as well as decreases the levels of albumin, globulin and total proteins.^{22,25} Analysis of these values, as well as histopathological analysis, are indicative of hepatic

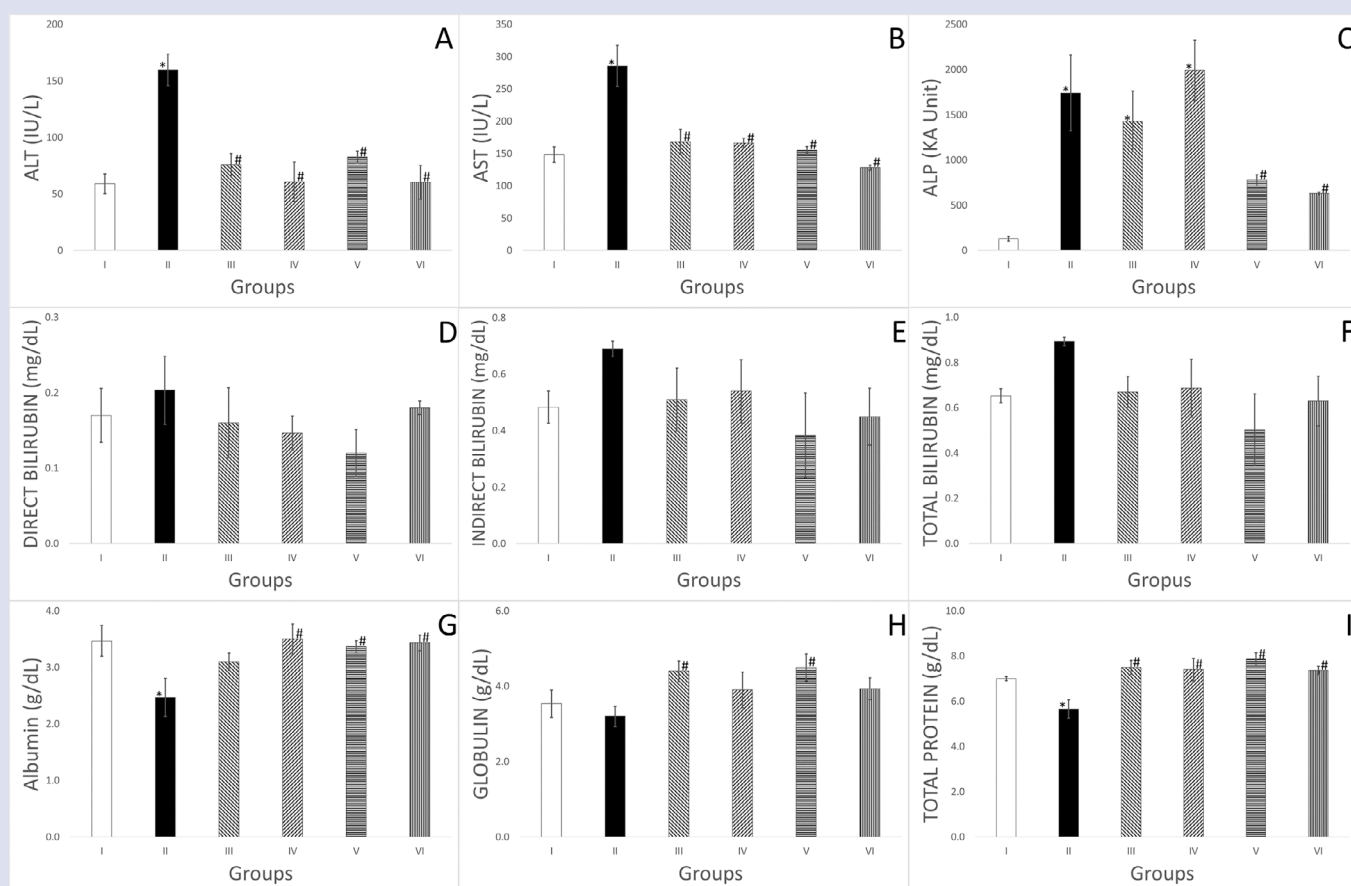
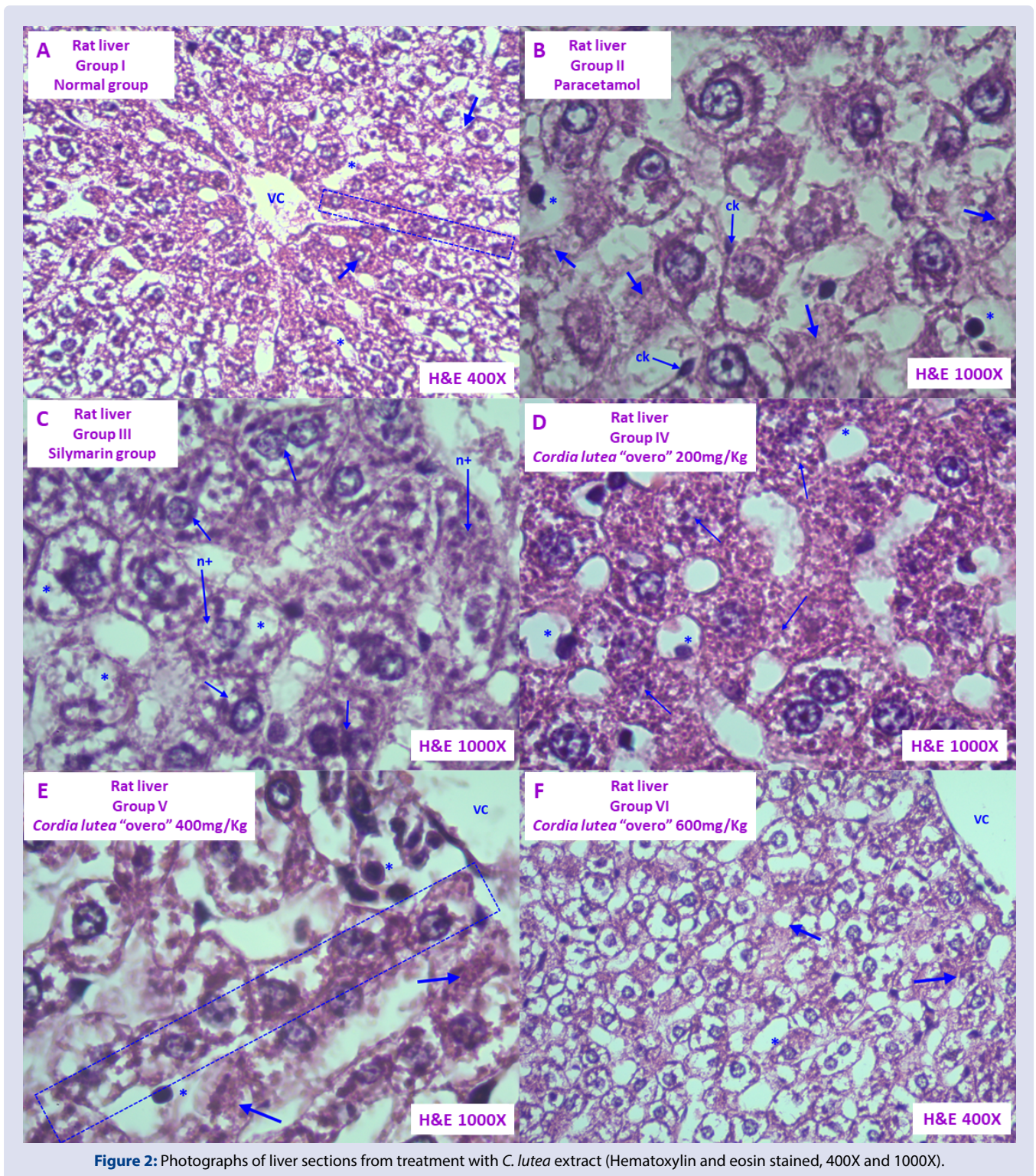


Figure 1: (A) Effect of *C. lutea* extract on the liver marker enzyme alanine amino transferase (ALT) in paracetamol-induced hepatotoxicity rat. (B) Effect of *C. lutea* extract on the liver marker enzyme aspartate amino transferase (AST) in paracetamol-induced hepatotoxicity rat. (C) Effect of *C. lutea* extract on the liver marker enzyme alkaline phosphatase (ALP) in paracetamol-induced hepatotoxicity rat. (D) Effect of *C. lutea* extract on the direct bilirubin in paracetamol-induced hepatotoxicity rat. (E) Effect of *C. lutea* extract on the indirect bilirubin in paracetamol-induced hepatotoxicity rat. (F) Effect of *C. lutea* extract on the total bilirubin in paracetamol-induced hepatotoxicity rat. (G) Effect of *C. lutea* extract on the serum albumin in paracetamol-induced hepatotoxicity rat. (H) Effect of *C. lutea* extract on the serum globulin in paracetamol-induced hepatotoxicity rat. (I) Effect of *C. lutea* extract on the total protein in paracetamol-induced hepatotoxicity rat. Group I: normal rat + normal saline, Group II: paracetamol-induced hepatotoxicity rat + normal saline, Group III: paracetamol-induced hepatotoxicity rat + Silymarin (200 mg/Kg), Group IV: paracetamol-induced hepatotoxicity rat + *C. lutea* (200 mg/Kg), Group V: paracetamol-induced hepatotoxicity rat + *C. lutea* (400 mg/Kg), Group VI: paracetamol-induced hepatotoxicity rat + *C. lutea* (600 mg/Kg). * $p < 0.05$ versus Group I and # $p < 0.05$ versus Group II.

necrosis caused by paracetamol.^{20,23} The alteration of these values, as well as the damage in the liver tissue, decreased with the pretreatment of the *C. lutea* extract, being the lowest concentration dose used (200 mg/Kg) comparable in effect to silymarin, a substance that has already shown hepatoprotective activity.²³ The 600 mg/Kg dose shows a better recovery in liver tissue, however, it does not show a significant decrease in ALT, AST and ALP values compared to the 400 mg/Kg dose ($p < 0.05$), likewise, the increase in total proteins was greater in the 400 mg/Kg dose and, unlike the 600 mg/Kg dose, the globulin increase was significant compared to the negative control ($p < 0.05$). Besides, although there are no statistically significant differences, the decrease in bilirubin was greater at the dose of 400 mg/Kg. Although *C. lutea* is a safe plant, the lower protective effect of 600 mg/kg might be due to pro-oxidant activity of the extract in the higher dose. That is because the hepatoprotective effect of this plant, at least in part, is due to its antioxidant activity, and antioxidants in some conditions, especially in high doses, might act as pro-oxidants.^{10,26}

C. lutea is a plant with a great hepatoprotective potential. Although not all its bioactive metabolites have been identified, the presence of rutin has been determined¹⁷, substance that has been shown to have hepatoprotective activity.²⁷ However, this activity may be enhanced by the presence of other bioactive metabolites that have probably not yet been identified, since some other compounds such as quercetin and curcumin have already shown this type of pharmacological activity.^{23,25}

In the most important databases, the information on its activity is very limited, finding only two investigations linked to Peruvian botanical remedies that contain extracts of this plant species^{10,11}, however, the activity corresponds to the mixture of plants and not to a specific species; and although there are undergraduate thesis in Peruvian universities that refer to about the activity of this plant species, they are not conclusive. Therefore, the limited evidence on the hepatoprotective activity of this plant makes it necessary to continue research on its hepatoprotective activity and the bioactive metabolites responsible for this activity.



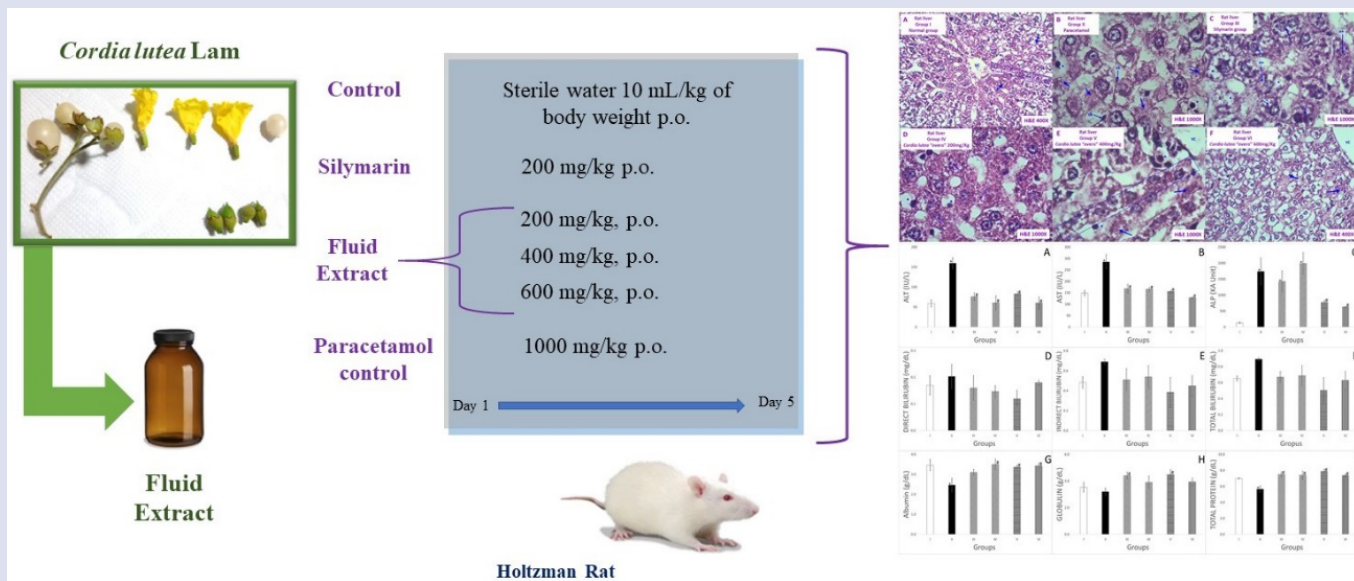
CONCLUSION

The extract of *C. lutea* has a marked hepatoprotective effect, significantly reducing the levels of ALT, AST and ALP, in addition to increasing the levels of albumin, globulin and total proteins, being more effective at a concentration of 400 mg / Kg of body weight in *rattus norvegicus*. *C. lutea* extract is an excellent candidate for use in paracetamol-induced liver diseases. It is expected, with future research, to identify the metabolites responsible for its effect.

REFERENCES

- Hodgman MJ, Garrard AR. A review of acetaminophen poisoning. Crit Care Clin. 2012;28(4):499-516.
- Ramachandran A, Jaeschke H. Acetaminophen toxicity: Novel insights into mechanisms and future perspectives. Gene Expr. 2018;18(1):19-30.
- Kumar G, Banu GS, Pappa PV, Sundararajan M, Pandian MR. Hepatoprotective activity of *Trianthema portulacastrum* L. against paracetamol and thioacetamide intoxication in albino rats. J Ethnopharmacol. 2004;92(1):37-40.
- Adewusi EA, Afolayan AJ. A review of natural products with hepatoprotective activity. J Med Plants Res. 2010;4(13):1318-34.
- Qadir MI, Ahmad Z. Advances in hepatoprotective medicinal plants research. Bangladesh J Pharmacol. 2017;12(3):229-42.
- Sagástegui-Guarniz WA, Silva-Correa CR, Villarreal-La Torre VE, Cruzado-Razco JL, Calderón- Peña AA, Aspajo-Villalaz CL, et al. Hepatoprotective and nephroprotective activity of *Artemisia absinthium* L. on diclofenac-induced toxicity in rats. Pharmacogn J. 2020;12(5):1032-41.
- Villarreal-La Torre VE, Ramirez JK, Rodríguez-Silva CN, Velasquez-Arevalo S. *Muehlenbeckia volcanica* (Benth.) Endl.: Revisión de una polygonaceae peruana de interés científico. Ethnobot Res Appl. 2020;19:16.
- Bussmann RW, Sharon D. Traditional medicinal plant use in Northern Peru: Tracking two thousand years of healing culture. J Ethnobiol Ethnomed. 2006;2:60-70.
- Mendocilla-risco M, Rojas N, Villar-lópez A, Cruzado-ubillús R, Guzmán-coral F. Evidencias preclínicas de *Cordia lutea* Lam: fitoquímica y efecto en daño hepático. Rev Peru Med Integr. 2018;3(4):183-90.
- Semple HA, Sloley BD, Cabanillas J, Chiu A, Aung SKH, Green FHY. Toxicology of a Peruvian botanical remedy to support healthy liver function. J Complement Integr Med. 2016;13(2):163-73.
- Swain MG, Wallace JL, Tyrrell DL, Cabanillas J, Aung SKH, Liu H, et al. Efficacy of a Peruvian Botanical Remedy (Sabell A4+) for treating liver disease and protecting gastric mucosal integrity. Evid Based Complement Altern Med. 2019;2019:5486728.
- Castro I, Fabre N, Bourgeade-Delmas S, Saffon N, Gandini C, Sauvain M, et al. Structural characterization and anti-infective activity of 9,10-Seco-29-norcytloartane Glycosides isolated from the flowers of the Peruvian medicinal plant *Cordia lutea*. J Nat Prod. 2019;82(12):3233-41.
- Rojas-Armas JP, Arroyo-Acevedo JL, Ortiz-Sánchez JM, Palomino-Pacheco M, Herrera-Calderón O, Calva J, et al. *Cordia lutea* L. Flowers: A promising medicinal plant as chemopreventive in induced prostate carcinogenesis in rats. Evid Based Complement Altern Med. 2020;2020:5062942.
- Arroyo-Acevedo J, Franco-Quino C, Ruiz-Ramírez E, Chávez-Asmat R, Anampa-Guzmán A, Raéz-González E, et al. Antiallergic effect of the atomized extract of rhizome of *Curcuma longa*, flowers of *Cordia lutea* and leaves of *Annona muricata*. Ther Clin Risk Manag. 2016;12:1643-7.
- Hernandez T, Canales M, Teran B, Avila O, Duran A, Garcia AM, et al. Antimicrobial activity of the essential oil and extracts of *Cordia curassavica* (Boraginaceae). J Ethnopharmacol. 2007;111(1):137-41.
- Marwah RG, Fatope MO, Mahrooqi R AI, Varma GB, Abadi H AI, Al-Burtamani SKS. Antioxidant capacity of some edible and wound healing plants in Oman. Food Chem. 2007;101(2):465-70.
- Venegas Casanova EA, Reyes S, Valencia JGG, Steve CB, Vallejos YF, Campos JE V, et al. New source of rutin from the flowers of *Cordia lutea* (Boraginaceae). Annu Rev Rev Biol. 2018;23(4):1-7.
- Silva-Correa CR, Cruzado-Razco JL, González-Blas MV, García-Armas JM, Ruiz-Reyes SG, Villarreal-La Torre VE, et al. Identification and structural determination of a sesquiterpene of *Tessaria integrifolia* Ruiz & Pav. leaves and evaluation of its leishmanicidal activity. Rev Peru Med Exp Publica. 2018;35(2).
- Aidy A, Karimi E, Ghaneialvar H, Mohammadpour S, Abbasi N. Protective effect of *Nectaroscordum tripedale* extract and its bioactive component tetramethylpyrazine against acetaminophen-induced hepatotoxicity in rats. Adv Tradit Med. 2020;20(3):471-7.
- Mohamed DA, Mohamed RS, Essa HA, Abdelgayed SS. Protection efficiency of red radish seeds and roots against paracetamol mediated hepatotoxicity in rats. J Herbmed Pharmacol. 2019;8(4):302-307. doi: 10.15171/jhp.2019.44.
- Grudzinski IP, Ruzycka M, Cieszanowski A, Szeszkowski W, Badurek I, Malkowska A, et al. MRI-based preclinical discovery of DILL: A lesson from paracetamol-induced hepatotoxicity. Regul Toxicol Pharmacol. 2019;108:104478.
- Sundari K, Karthik D, Ilavenil S, Kaleeswaran B, Srigopalram S, Ravikumar S. Hepatoprotective and proteomic mechanism of *Sphaeranthus indicus* in paracetamol induced hepatotoxicity in wistar rats. Food Biosci. 2013;1:57-65.
- Ahmad MM, Rezk NA, Fawzy A, Sabry M. Protective effects of curcumin and silymarin against paracetamol induced hepatotoxicity in adult male albino rats. Gene. 2019;712:143966.
- Moshai-Nezhad P, Iman M, Maleki FF, Khamesipour A. Hepatoprotective effect of descurainia sophia seed extract against paracetamol-induced oxidative stress and hepatic damage in mice. J HerbMed Pharmacol. 2018;7(4):267-72.
- Yousef MI, Omar SAM, El-Guendi MI, Abdelmegid LA. Potential protective effects of quercetin and curcumin on paracetamol-induced histological changes, oxidative stress, impaired liver and kidney functions and haematotoxicity in rat. Food Chem Toxicol. 2010;48(11):3246-61.
- Jamshidi-Kia F, Wibowo JP, Elachouri M, Masumi R, Salehi Jouneghani A, Abolhassanzadeh Z, et al. Battle between plants as antioxidants with free radicals in human body. J Herbmed Pharmacol. 2020;9(3):191-199. doi: 10.34172/jhp.2020.25.
- Janbaz KH, Saeed SA, Gilani AH. Protective effect of rutin on paracetamol- and CCl₄-induced hepatotoxicity in rodents. Fitoterapia. 2002;73(7-8):557-63.

GRAPHICAL ABSTRACT



ABOUT AUTHORS



Ruiz-Reyes Segundo G. Professor in the cathedra of pharmacognosy and pharmacobotanics of the Universidad Nacional de Trujillo. Research development in natural therapeutic products. Degrees: Doctor in Pharmacy and Biochemistry. Master's in pharmacy and biochemistry with a major in Natural Therapeutic Producer. Pharmaceutical.



Villarreal-La Torre Víctor E. Master of Chemical Sciences, holds a degree in Pharmacy from Universidad Nacional de Trujillo (2011). Professor in the Medicinal Chemistry undergraduate program and the Molecular basis of the Action of Xenobiotics postgraduate program at the Universidad Nacional de Trujillo. He currently executes research projects aimed at the discovery of antimicrobial compounds in medicinal plants. Graduate student at Doctoral program in Pharmacy and Biochemistry since 2019.




Silva-Correa Carmen R. Department of Pharmacology professor at Universidad Nacional de Trujillo, holds a degree in Pharmacy and Biochemistry (2011), Master of Chemical Sciences (2017), graduate student at Doctoral program in Biomedical Sciences since 2019. Currently participates in research projects on toxicological and pharmacological evaluation of medicinal plants, focusing in the evaluation of the wound healing activity of traditional medicinal plants from Peru



Sagastegui-Guarniz William Antonio. Department of Pharmacology professor at Universidad Nacional de Trujillo, Perú since 1993 – to date. I am a graduated in Pharmacy and Biochemistry. Speaker at the graduate program of Universidad Nacional de Trujillo. Has bachelor in pharmaceutical chemistry 1988. Master's in chemical sciences, 1999. Doctorate in Biomedical Sciences, graduate program of the Universidad Nacional de Trujillo, 2010. Doctorate studies at Universidade Federal Do Ceará, Brazil, 2015-2018. Currently participates in research projects aimed at the phytochemical characterization of medicinal plants, focusing on antimicrobial activity, resistance to antimicrobials, and antimalarial.



Cruzado-Razco José L. Department of Pharmacology professor at the Universidad Nacional de Trujillo, holds a degree in Pharmacy and Biochemistry, Master of Physiology and Biophysics, Doctorate studies in Biomedical Sciences. He has participated in research projects on epidemiology of tropical diseases and currently, in research on antimalarial, leishmanicidal and anti-trypanosomal activity of medicinal plants.



Gamarra-Sánchez Cesar D. Department of Pharmacology professor at Universidad Nacional de Trujillo, holds a degree in Pharmacy and Biochemistry, Master of Pharmacology. He has participated in research projects on medicinal plants activity and drug discovery.



Venegas Casanova Edmundo A. Auxiliary professor exclusive dedication pharmacobotanical and pharmacognosy chair



Miranda-Leyva Manuel. Bachelor of Pharmacy and Biochemistry, Pharmaceutical Chemist, M.Sc. in Chemical Sciences, Doctorate in Biomedical Sciences (completed studies), Principal Professor at Exclusive Dedication, Faculty of Pharmacy and Biochemistry, National University of Trujillo. Researcher in Biomedical Sciences and environmental pollution.



Valdiviezo Campos Juan Ernesto. Pharmaceutical chemist, teaching and research assistant, master's in Pharmacy and Biochemistry with a major in Natural Therapeutic Products. Graduate student at Doctoral program in Pharmacy and Biochemistry of the Universidad Nacional de Trujillo



Cuellar-Cuellar Armando. Bachelor of Chemistry (1971), Master of Chemistry (1974), Doctor of Pharmaceutical Sciences (1997). He was a Full Professor at the University of Havana and has teaching experience for 40 years at that university. He has worked in the study of medicinal plants for 30 years. He has taught courses on natural products in Cuba, Mexico, Peru, Brazil, and Uganda.

Cite this article: Ruiz-Reyes SG, Villarreal-La Torre VE, Silva-Correa CR, Sagástegui Guarniz WA, Cruzado-Razco JL, Gamarra-Sánchez CD, *et al.* Hepatoprotective Activity of *Cordia lutea* Lam Flower Extracts Against Paracetamol-Induced Hepatotoxicity in Rats. *Pharmacog J.* 2021;13(2): 309-16.