

# The Effect of *Artocarpus altilis* (Parkinson) Fosberg Extract Supplementation on Kidney Ischemia-Reperfusion Injury Rat

Anton Bahtiar<sup>1,\*</sup>, Aulia Jihan Miranda<sup>1</sup>, Ade Arsianti<sup>2</sup>

Anton Bahtiar<sup>1,\*</sup>, Aulia Jihan Miranda<sup>1</sup>, Ade Arsianti<sup>2</sup>

<sup>1</sup>Department of Pharmacology and Toxicology, Faculty of Pharmacy, Universitas Indonesia, Kampus UI Depok 16424, West Java, INDONESIA.

<sup>2</sup>Department of Medicinal Chemistry, Faculty of Medicine, Universitas Indonesia, Kampus UI Salemba, Jakarta, INDONESIA.

## Correspondence

Anton Bahtiar

Department of Pharmacology and Toxicology, Faculty of Pharmacy, Universitas Indonesia, Kampus UI Depok 16424, West Java, INDONESIA.

E-mail: anton.bahtiar@farmasi.ui.ac.id

## History

- Submission Date: 09-10-2020;
- Review completed: 05-11-2020;
- Accepted Date: 09-11-2020.

DOI : 10.5530/pj.2021.13.21

## Article Available online

<http://www.phcogj.com/v13/i1>

## Copyright

© 2021 Phcogj.Com. This is an open-access article distributed under the terms of the Creative Commons Attribution 4.0 International license.



## ABSTRACT

**Background:** Acute kidney injury (AKI) is a kidney disease resulting in high morbidity and mortality levels in humans. One of the disorders classified as AKI is ischemia-reperfusion injury (IRI), characterized by two phases. The first phase is Ischemia in the kidneys due to obstruction of the renal arteries or veins, followed by the second phase, which is the occurrence of reperfusion with blood flowing back in the renal arteries veins. The aim of this current research is to analyze the efficacy of *Artocarpus altilis* on Kidney ischemia-reperfusion model rats. **Methods:** To this end, first, we established Ischaemia-reperfusion kidney injury rat. We then evaluated the *Artocarpus altilis* extract on IRI model rats. A total of 36 rats have grouped into six groups. Group I is the Sham group, Group II is the negative control group, Group III is the positive control group (vitamin C 100 mg/kg BW), Group IV is Dose I of *Artocarpus altilis* extract 50 mg/kg BW), Group V is Dose II *Artocarpus altilis* extract 100 mg/kg BW), Group VI is Dose III *Artocarpus altilis* extract 200 mg/kg BW). The vitamin C and *Artocarpus altilis* extract administered 14 days before and after Ischemia-reperfusion treatment. At day 0, Ischemia was made by bilateral renal pedicle clamping method for 30 minutes, sacrificed 14 days after reperfusion. The blood and histology samples were collected on day 0, a day after reperfusion, at 24 hrs after reperfusion, at 48 hrs after reperfusion, and 14 days after treatment. **Results:** The clamping duration of 30 minutes leads to achieving the most representative clinical IRI conditions. It shows the most significant recovery of injury conditions within the 14-day reperfusion period in IRI animal models, making it ideal for IRI operations for the preliminary test. The administration of 100 mg/kg BW of *Artocarpus altilis* extract could reduce the malondialdehyde plasma compared with the sham group. The SOD and Catalase activity showed improvement after reperfusion. **Conclusion:** *Artocarpus altilis* extracts showed antioxidant activity to prevent the kidney from ischemia-reperfusion injury by modulated SOD and Catalase.

**Key Words:** *Artocarpus altilis* (Parkinson) Fosberg, Sukun, Reperfusion injury, Acute kidney disease, Free radicals.

## INTRODUCTION

Kidney disease has not yet become the main focus of most public health campaigns and promotions. It estimates that more than 850 million people worldwide live with various types of kidney disease. The prevalence of kidney disease is roughly twice the prevalence of diabetes (422 million), 20 times the majority of cancer (42 million), and more than the prevalence of HIV / AIDS (36.7 million) in the world.<sup>1</sup> From these data, it can conclude that kidney disease is one of the world's most common conditions.

Kidney disease is classified into acute kidney injury (AKI) and chronic kidney disease (CKD). CKD is defined as an abnormality in the persistent kidneys' structure or function and occurs for more than three months. CKD itself is the most common form of kidney disease, with an estimated prevalence of around 10.4% in men and 11.8% in women in the world.<sup>1</sup>

On the other hand, AKI is a common, severe kidney disease, and many aspects of its natural history are still uncertain.<sup>2</sup> AKI is usually caused by an event

that causes kidney damage, such as dehydration, blood loss from surgery or injury, or the use of drugs. AKI can cause decreased kidney function, disrupt electrolyte homeostasis, and induce an inflammatory response that affects other vital organs. The main risk factors for AKI also vary from country to country, including dehydration, shock, infection, sepsis, heart disease, and nephrotoxic drugs.<sup>3</sup> AKI is experienced by 13.3 million patients each year and can manifest into CKD.<sup>1</sup>

Ischemia-reperfusion injury (IRI) is a form of the disease that is classified as AKI. Various factors cause IRI, the most dominant of which are: 1) ATP depletion, which inhibits the pumping of Ca<sup>2+</sup> ions out of cells, thus causing Ca<sup>2+</sup> accumulation in cells and inducing apoptotic events; 2) the formation of reactive oxygen species that contribute to membrane dysfunction and progressive reduction of mitochondrial function; 3) activation of leukocytes, especially neutrophils, which release reactive oxygen species (ROS), cytokines, proteases, and other inflammatory mediators, causing renal dysfunction; and 4) the formation of endogenous 5-lipoxygenase metabolites which increase the degree of renal

**Cite this article:** Bahtiar A, Miranda AJ, Arsianti A. The Effect of *Artocarpus altilis* (Parkinson) Fosberg Extract Supplementation on Kidney Ischemia-Reperfusion Injury Rat. *Pharmacogn J.* 2021;13(1): 150-4.

injury, renal dysfunction, and inflammation through the expression of adhesion molecules.<sup>4,5</sup>

One of the causes of the poor long-term outcome of IRI is challenging to achieve renal recovery. Until now, there are many types of drugs used in IRI therapy. These include 1) dexmedetomidine, an  $\alpha_2$  agonist, which can reduce levels of inflammatory mediators; 2) montelukast and zafirlukast, leukotriene receptor blockers, which can inhibit neutrophil infiltration; 3) ulinastatin, a protease inhibitor, which can hinder apoptotic events and neutrophil infiltration; 4) vitamins C and E as antioxidants that can suppress the production of proinflammatory cytokines; and 5) Aliskiren, a renin inhibitor, which can inhibit the formation of oxidative stress and increase anti-apoptotic activity.<sup>5</sup>

It is necessary to use appropriate, useful, and appropriate drugs in the treatment of kidney disease. Compounds that can also be used in this Medicine are compounds derived from the stilbene group with an antioxidant mechanism. One of the compounds from this group is tetrahydroxystilbene, one of the components of the breadfruit plant (*Artocarpus communis*).

This tetrahydroxystilbene has many effects that can be utilized by humans as a treatment, including antioxidant, neuroprotective, anti-atherosclerotic, and anti-inflammatory effects.<sup>6</sup> Following the pathophysiology of IRI, tetrahydroxystilbene compounds can treat IRI by 1) cytoprotective effect against oxidative stress by inhibiting malondialdehyde (MDA) and ROS, as well as increasing cellular antioxidant enzymes such as superoxide dismutase (SOD) and glutathione peroxidase (GSH-Px); and 2) upregulation of mRNA which can reduce protein overexpression of inflammatory mediators.<sup>6</sup>

By looking at the effects, this compound has, further research is needed on the effects of tetrahydroxystilbene compounds as antioxidants in IRI treatment. From this research, it is hoped that significant antioxidant and anti-inflammatory effects can be shown so that these compounds can be used as an alternative to IRI treatment.

## MATERIAL AND METHODS

The tools used are animal scales (Mettler Toledo, United States), analytical scales (Ohaus, United States), homeothermic monitor system, urea nitrogen test kit (StanBio, United States), spectrophotometer (Shimadzu, Japan), TLC-densitometer (Camag, Switzerland), creatinine LiquiColor test kit (Stanbio, United States), glassware (Pyrex, Indonesia), micropipettes (Socorex, Switzerland), microtube (Nesco, Indonesia), blue tip (Nesco, Indonesia), yellow tip (Nesco, Indonesia), white tip (Nesco, Indonesia), centrifuge (NUVE NF 048, Turkey), refrigerator, and Soxhlet appliance.

The chemicals used are dichloromethane and methanol (PT Merck, Indonesia), ketamine and xylazine (PT Generik, Indonesia), aqua pro injection (PT Generik, Indonesia), aqua dest (PT Brataco, Indonesia), CMC Na (PT Brataco, Indonesia), formaldehyde and ethanol (PT Merck, Indonesia), periodic acid solutions (PT Merck, Indonesia), Schiff reagent (PT Merck, Indonesia), hematoxylin (Leica Biosystems, Germany), toluene (PT Merck, Indonesia), normal saline (PT Otsuka, Indonesia), urease (PT Merck, Indonesia), picric acid (Sigma Aldrich, Singapore), and NaOH (PT Merck, Indonesia).

### Plant extraction

Following the standard NCI extraction protocol, 353 grams of breadfruit stem bark (*Artocarpus altilis*) was pounded and soaked in CH<sub>2</sub>Cl<sub>2</sub>-MeOH (1: 1) 15 hours in a Soxhlet device. The solvent will be removed, and then the plant material is soaked for another 15 hours in 100% MeOH. The combined extracts were dried in a vacuum and yielded about 36 grams of crude extract.

## Animal treatment

In this experiment, all animals were used following the Faculty of Medicine's animal care guidelines, Universitas Indonesia ethic committee with certificate No: KET.105/UN2.F1/ETIK/PPM.00.01/2020.

The animals used were white male Sprague-Dawley (SD) rats, about two months old, and 200-250 grams. Before being given the treatment, the rats were acclimatized for seven days in the Faculty of Pharmacy's animal facility, Universitas Indonesia. A total of 36 rats have grouped into six groups, they are normal group; Sham group; positive control group (vitamin C 100 mg/kg BW); Dose I *Artocarpus altilis* extract 50 mg/kg BW); Dose II *Artocarpus altilis* extract 100 mg/kg BW); Dose III *Artocarpus altilis* extract 200 mg/kg BW). The vitamin C and *Artocarpus altilis* extract administered 14 days before and after Ischemia-reperfusion treatment. At day 0, Ischemia was made by bilateral renal pedicle clamping method for 30 minutes and sacrificed 14 days after reperfusion. The blood and histology samples were collected on day 0, a day after reperfusion, at 24 hrs after reperfusion, at 48 hrs after reperfusion, and 14 days after treatment.

### Kidney structural evaluation

Histological examination of the kidney tissue using the PAS stain method is a direct way to verify and localize kidney injury.<sup>7</sup>

### Kidney functional evaluation

Kidney Functional evaluation has done by measurement of serum creatinine levels using a LiquiColor creatinine test kit.

## RESULT

### Histopathology

Histopathological observations in the form of tubular injury in kidney samples were assessed from three parameters: cell degradation, necrosis, and neutrophil infiltration. Haematoxylin and eosin stain was used as a control, with microscopic analysis showing the tubular basement membrane clearly and in pink. Then, PAS staining was used as a specific stain against lymphocyte and mucopolysaccharide components in the tissue. In the procedure, PAS staining was treated with counterstaining with hematoxylin. This counterstaining serves to increase color contrast on the network by coloring the cellular compartments, making it easier to localize the components to be analyzed.<sup>8</sup> Microscopic analysis of the PAS stained preparation revealed a magenta-colored tubular basement membrane.

### Oxidant and antioxidant status

The concentration of malondialdehyde as representative of oxidant status was shown in Table 1. As seen in the Sham group, the Ischemia and reperfusion injury demonstrated an increase in malondialdehyde concentration. This result indicated that ischemia-reperfusion produced a high amount of oxidant because there is an increase in malondialdehyde. The addition of Vitamin C before ischemia-reperfusion could reduce the amount of malondialdehyde. The administration of *Artocarpus altilis* extracts, at dose 100 mg/kg BW could reduce the amount of malondialdehyde better than vitamin C administration.

We then evaluated the antioxidant endogen activity of Superoxide Dismutase and catalase in plasma. Table 2 showed that the negative group, which representative of ischemia and reperfusion group, seen reduced of SOD activity. The administration of vitamin C 14 days before ischemia-reperfusion treatment showed could prevent the reduction of SOD activity. The similar results have shown in *Artocarpus altilis*

**Table 1: Effects of *Artocarpus altilis* extract on the concentration of malondialdehyde plasma of IRI model rats.**

Group	Before Reperfusion (ng/mL)	After Reperfusion (ng/mL)	The increased amount of MDA concentration
Sham	127.8 ± 3.3	109.9 ± 4.1	-17.9
Negative group	149.7 ± 7.6	163.5 ± 3.5	13.8
Vit C (100mg/kg BW)	199.8 ± 1.6	170.0 ± 20.5	-29.75
<i>Artocarpus altilis</i> (50mg/kg BW)	72.6 ± 20.5	86.4 ± 6.4	13.8
<i>Artocarpus altilis</i> (100mg/kg BW)	189.1 ± 14.4	119.5 ± 11.7	-69.6
<i>Artocarpus altilis</i> (200mg/kgBW)	155.9 ± 1.4	131.0 ± 29.1	-24.9

**Table 2: Effects of *Artocarpus altilis* extract on the activity of Superoxide Dismutase plasma of IRI model rats.**

Group	Before Reperfusion (ng/mL)	After Reperfusion (ng/mL)	The difference in SOD activity
Sham	9.03 ± 0.001	9.77 ± 0.02	0.074
Negative group	9.14 ± 0.02	8.65 ± 0.015	- 0.490
Vit C (100mg/kgBW)	9.93 ± 0.007	9.97 ± 0.015	0.04
<i>Artocarpus altilis</i> (50mg/kgBW)	9.02 ± 0.02	10.47 ± 0.032	1.45
<i>Artocarpus altilis</i> (100mg/kgBW)	7.20 ± 0.013	9.27 ± 0.006	2.07
<i>Artocarpus altilis</i> (200mg/kgBW)	10.75 ± 0.039	9.60 ± 0.004	- 1.15

**Table 3: Effects of *Artocarpus altilis* extract on the activity of Catalase plasma of IRI model rats.**

Group	Before Reperfusion (ng/mL)	After Reperfusion (ng/mL)	The difference in Catalase activity
Sham	105.27 ± 9.50	104.98 ± 1.86	- 0.029
Negative group	132.57 ± 0.02	109.43 ± 0.78	- 23.14
Vit C (100mg/kgBW)	110.89 ± 8.39	130.61 ± 18.83	19.72
<i>Artocarpus altilis</i> (50mg/kgBW)	105.27 ± 7.09	115.13 ± 3.65	9.86
<i>Artocarpus altilis</i> (100mg/kgBW)	107.83 ± 1.08	117.96 ± 5.70	10.13
<i>Artocarpus altilis</i> (200mg/kgBW)	120.51 ± 4.93	118.11 ± 2.62	- 2.40

extract administration, at dose 100 mg/kg BW could increase SOD activity.

In Table 3 showed that ischemia-reperfusion treatment reduced of Catalase activity. The administration of vitamin C 14 days before ischemia-reperfusion treatment showed could prevent the reduction of Catalase activity. The similar results have shown in *Artocarpus altilis* extract administration, at dose 100 mg/kg BW could increase Catalase activity.

### Creatinine levels

Acute Kidney Injury is currently defined, among other things, as a rapid decrease in the glomerular filtration rate resulting in nitrogen retention, particularly blood urea nitrogen (BUN) and serum creatinine. This decrease in the glomerular filtration rate can occur over several hours to several months but usually occurs several hours to several days. Therefore, we evaluated the creatinine level of the kidney ischemia-reperfusion injury model rat. Table 4 showed that ischemia-reperfusion treatment increased in plasma creatinine levels. Administration of vitamin C before ischemia-reperfusion treatment could prevent the increase in plasma creatinine. The administration of *Artocarpus altilis* extract could reduce plasma creatinine levels.

## DISCUSSION

### Establishment Ischemia-Reperfusion model Rat

Figure 1 showed the histopathology of kidney cells of ischemia-reperfusion injury. At 24 h reperfusion time, with HE and PAS staining, cell degradation did not occur, and necrosis happened on a scale of 3, indicating scattered focal necrosis in the tubules. With Haematoxylin and eosin stain, severe neutrophil infiltration occurred, whereas, with PAS staining, there was a neutrophil infiltration of 4-6 cells. On the other hand, at the reperfusion time of 14 days, these three parameters' conditions had improved. Cell degradation still did not occur, and

necrosis only happened in a few single cells, both in the results of HE and PAS staining. In Haematoxylin and eosin stain, the neutrophils experienced an infiltration of 1-3 cells/area, whereas no neutrophil infiltration was observed in PAS staining.

The condition of the tubular injury that improved in groups I and II after 14 days of reperfusion was probably due to the IRI extension phase, which is characterized by the occurrence of reperfusion, having progressed to the recovery phase. This recovery phase is the last in IRI, which is marked by the event of tissue repair to restoring kidney function.<sup>9</sup> The results of most studies also support this that kidney morphology returns to normal almost two weeks after bilateral Ischemia is carried out.<sup>10</sup>

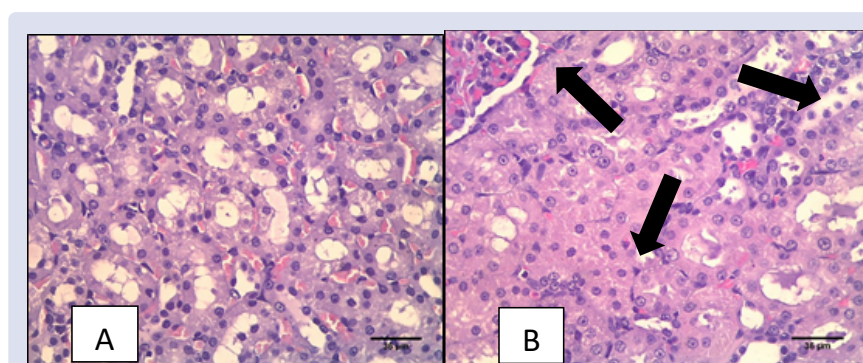
Analysis of tubular kidney injury through histopathology can be carried out by various methods, one of which is the periodic-acid Schiff (PAS) staining method. This PAS staining system provides a standard procedure for assessing the extent of tubular injury to the kidneys by examining parameters such as cell degradation, necrosis, and neutrophil infiltration. These three parameters have their respective damage scale values, starting from 0, indicating the absence of injury, to 4 indicating the most severe injury condition.<sup>11,12</sup>

### Oxidant and antioxidant status of *Artocarpus altilis* treated rat

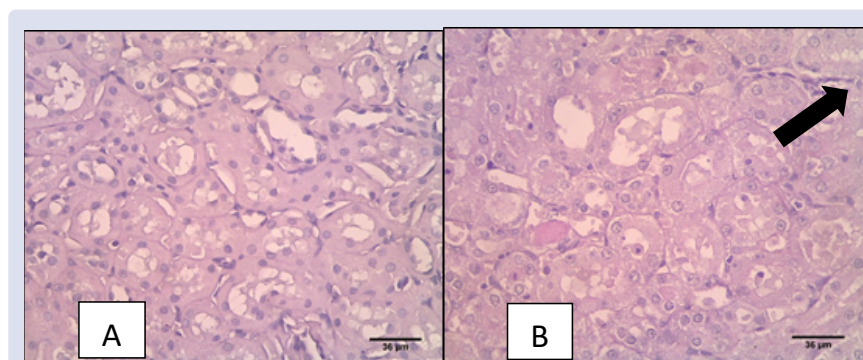
Ischemia-reperfusion injury (IRI) is a form of the disease that is classified as AKI. As the name implies, this IRI condition consists of two distinct phases. First, Ischemia in the kidneys due to hypoperfusion or occlusion of the renal arteries and veins.<sup>13</sup> Second, reperfusion occurs by returning blood to and from the kidneys as a recovery effort.<sup>14</sup> In the end, these two phases cause various responses in the body, the most dominant of which are: 1) ATP depletion, which inhibits the pumping of Ca<sup>2+</sup> ions out of cells, causing Ca<sup>2+</sup> accumulation in cells, and inducing apoptotic events; 2) formation of reactive oxygen species

**Table 4: Effects of *Artocarpus altilis* extract on the concentration of creatinine plasma of IRI model rats.**

Groups	Before Reperfusion (mg/dL)	After Reperfusion (mg/dL)	Increase in basal serum creatinine
Sham	0.1625 ± 0.10	0.2500 ± 0.04	0.0875
Negative group	0.1812 ± 0.04	0.3250 ± 0.05	0.1438
Positive	0.1250 ± 0.06	0.2250 ± 0.06	0.1000
Binahong dose 1	0.2375 ± 0.15	0.2250 ± 0.03	-0.0125
Binahong dose 2	0.1750 ± 0.03	0.1627 ± 0.05	-0.0123
Binahong dose 3	0.2188 ± 0.15	0.2000 ± 0.07	-0.0188



**Figure 1:** The results of hematoxylin and eosin stain of the kidney, which had Ischemia and reperfusion. A. Normal groups; B. 30 minutes of Ischemia and 14 days after reperfusion. No cell degradation was observed, but confluent necrosis occurred in most tubules (arrow) and severe neutrophil infiltration in the tissue.



**Figure 2:** The results of PAS staining of the kidney, which had Ischemia and reperfusion. A. Normal groups; B. 30 minutes of Ischemia and 14 days after reperfusion. No cell degradation and neutrophil infiltration were observed, but confluent necrosis occurred in most of the tubules (arrow) in the tissue.

(ROS) which contribute to membrane dysfunction and progressive reduction of mitochondrial function; 3) activation of leukocytes, especially neutrophils, which release ROS, cytokines, proteases, and other inflammatory mediators, causing renal dysfunction; and 4) the formation of endogenous 5-lipoxygenase metabolites which increase the degree of renal injury, renal dysfunction, and inflammation through the expression of adhesion molecules.<sup>4,5</sup>

According to the pathophysiology, one of the aspects that can occur due to the IRI condition is a tubular injury to the kidneys due to the release of large amounts of ROS.<sup>4</sup> The current research showed that *Artocarpus altilis* extracts could reduce MDA and increase SOD and catalase activity.

## CONCLUSION

*Artocarpus altilis* extracts showed antioxidant activity to prevent the kidney from ischemia-reperfusion injury by modulated SOD and Catalase.

## ACKNOWLEDGMENT

This research was supported by The Ministry of Research and Technology/BRIN Republic Indonesia with contract number NKB-88/UN2.RST/HKP.05.00/2020.

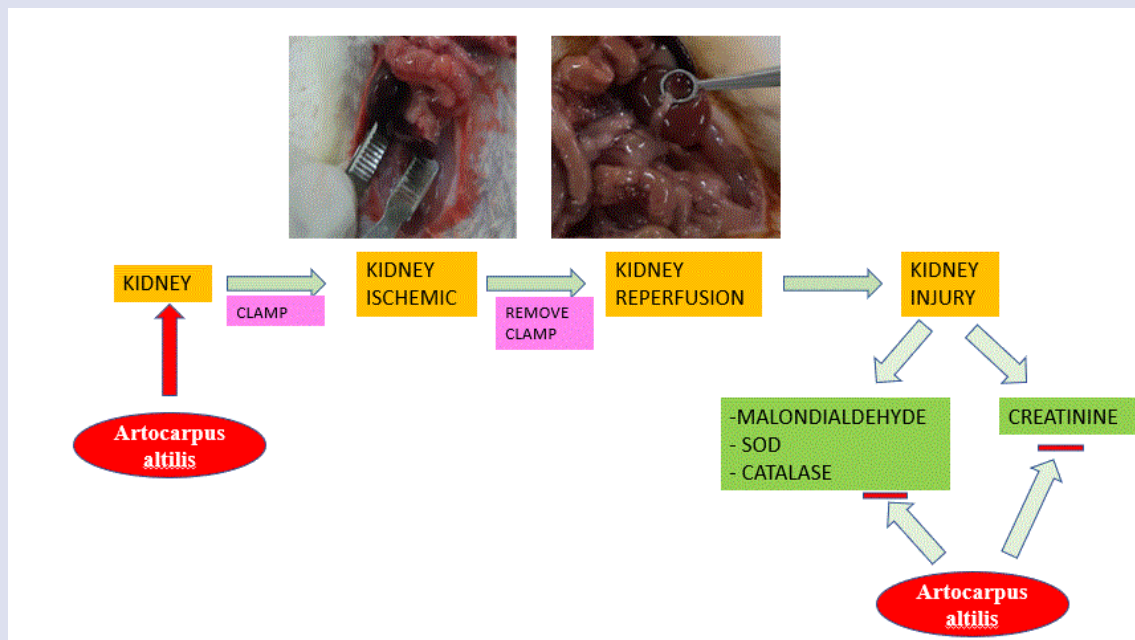
## CONFLICTS OF INTEREST

All authors declared no conflicts of interest.

## REFERENCES

- Levin A. Improving Global Kidney Health: International Society of Nephrology Initiatives and the Global Kidney Health Atlas. *Ann Nutr Metab.* 2018;72(suppl 2):28-32.
- Sawhney S, Fraser SD. Epidemiology of AKI: Utilizing Large Databases to Determine the Burden of AKI. *Adv Chronic Kidney Dis.* 2017;24:194-204.
- Hoste EAJ. Global epidemiology and outcomes of acute kidney injury. *Nat Rev Nephrol.* 2018;14:607-25.
- Buy-Gonçalves GF. Antioxidants as Renoprotective Agents for Ischemia during Partial Nephrectomy. *Biomed Res Int.* 2019;8575398.
- Malek M, & Nematbakhsh M. Renal ischemia/reperfusion injury; from pathophysiology to treatment. *J Ren Inj Prev.* 2015;4:20-7.
- Zhang L, Chen J. Biological Effects of Tetrahydroxystilbene Glucoside: An Active Component of a Rhizome Extracted from *Polygonum multiflorum*. *Oxid Med Cell Longev.* 2018;3641960.
- Wei Q, Dong Z. Mouse model of ischemic acute kidney injury: technical notes and tricks. *Am J Physiol Physiol.* 2012;303:F1487-94.
- Renshaw S. Chapter 4.2 - Immunohistochemistry and Immunocytochemistry. in (ed. Wild, D. B. T.-T. I. H. (Fourth E.) 357–377 (Elsevier, 2013).
- Sutton TA, Fisher CJ, Molitoris BA. Microvascular endothelial injury and dysfunction during ischemic acute renal failure. *Kidney Int.* 2002;62:1539-49.
- Le Clef N, Verhulst A, D'Haese PC, Vervaeke BA. Unilateral Renal Ischemia-Reperfusion as a Robust Model for Acute to Chronic Kidney Injury in Mice. *PLoS One.* 2016;11:e0152153.
- Gobe GC. Increased progression to kidney fibrosis after erythropoietin is used as a treatment for acute kidney injury. *Am J Physiol Physiol.* 2014;306:F681-92.
- Park J. Single-cell transcriptomics of the mouse kidney reveals potential cellular targets of kidney disease. *Science (80-).* 2018;360:758-63.
- Owji SM, Nikeghbal E, Moosavi SM. Comparison of ischaemia-reperfusion-induced acute kidney injury by clamping renal arteries, veins or pedicles in anaesthetized rats. *Exp Physiol.* 2018;103:1390-402.
- Philipponnet C, Anjort J, Garrouste C, Kemeny JL, Heng AE. Ischemia reperfusion injury in kidney transplantation: A case report. *Medicine (Baltimore).* 2018;97:e13650.

## GRAPHICAL ABSTRACT



## ABOUT AUTHORS

- Anton Bahtiar obtained his PhD degree in 2010 from Nara Institute of Science and Technology, Japan. Currently, He is lecturer and researcher at faculty of pharmacy, Universitas Indonesia since 1998. He is also a head of Pharmacology and Toxicology Laboratory. His research projects are focus on Herbal medicine and tried to solve the mechanism of action of herbal medicine, especially for osteoporosis and menopause.
- Aulia Jihan Miranda obtained her Bachelor degree in 2020 from Faculty of Pharmacy, Universitas Indonesia. She is continue her education in Pharmacist profession programme and will graduate on June 2021. Her research focus on drug development for kidney diseases from Natural products in Department of Pharmacology and Toxicology of Faculty of Pharmacy, Universitas Indonesia.
- Ade Arsianti obtained her PhD degree in 2011 from Nara Institute of Science and Technology, Japan. Currently, she is lecturer and researcher at Faculty of Medicine, Universitas Indonesia. She is Head of Department of Medicinal Chemistry on that Faculty.

**Cite this article:** Bahtiar A, Miranda AJ, Arsianti A. The Effect of *Artocarpus altilis* (Parkinson) Fosberg Extract Supplementation on Kidney Ischemia-Reperfusion Injury Rat. *Pharmacog J.* 2021;13(1): 150-4.