

Original Article

Delayed surgical diagnosis and treatment of severe sickle cell arthropathy: The need to raise clinicians' awareness



Olumuyiwa A. Bamgbade, FRCPC^{a,*}, Vera Onongaya, MBBS^b,
Adanna Anomneze-Collins, MBBS^b, Demilade A. Omoniyi, MBBS^c,
Patrice Simmonds-Brooks, MBBS^d and Renee N. Richards, MBBS^e

^a Department of Anesthesiology, University of British Columbia, Vancouver, Canada

^b Department of Medicine, School of Medicine, Cardiff University, Cardiff, Wales, United Kingdom

^c Department of Medicine, University College Hospital, Ibadan, Nigeria

^d Sickle Cell Department, Sickle Cell Unit, Caribbean Institute for Health Research, UWI, Kingston, Jamaica

^e Research Department, Salem Anaesthesia Pain Clinic Surrey, Vancouver, BC, Canada

Received 15 February 2021; revised 23 April 2021; accepted 27 April 2021; Available online 31 May 2021

المخلص

أهداف البحث: مرض فقر الدم المنجلي مرتبط بنخر عظم رأس الفخذ. يتم علاج داء الكريات المنجلية عن طريق رأب مفصل الورك، في غضون ١٨ أسبوعاً من العرض على الطبيب. ومع ذلك، هناك معطيات غير كافية بخصوص توقيت العلاج الجراحي لاعتلال مفصل الورك الحاد في داء الكريات المنجلية. تستكشف هذه الدراسة مشكلة التشخيص المتأخر والعلاج الجراحي لاعتلال مفصل الورك الحاد في داء الكريات المنجلية. ومقارنة النتائج السريرية لاعتلال مفصل الورك لدى مرضى فقر الدم المنجلي من نيجيريا وكندا وإنجلترا.

طرق البحث: هذا هو التدقيق السريري المرتقب للرعاية الروتينية لـ ٣٠ مريضاً بالغاً من مرضى فقر الدم المنجلي الذين خضعوا لعملية رأب مفصل الورك من أجل تنخر عظم رأس الفخذ. وتم جمع البيانات السريرية ومقارنتها من خمس كليات طب في إنجلترا وكندا ونيجيريا.

النتائج: تأخر علاج مفصل الورك لأكثر من ١٨ أسبوعاً في ٣ من ١٤ مريضاً نيجيريا (٢١٪)، و ٧ من كل ١٠ مرضى بريطانيين (٧٠٪)، وجميع المرضى الكنديين الستة (١٠٠٪). مقارنةً بـ ٣٠٪ من المرضى البريطانيين، كان لدى الغالبية العظمى من المرضى النيجيريين (٧٩٪) التصوير التشخيصي والمعالجة الجراحية دون تأخير.

الاستنتاجات: يمكن الرفع من وعي الطبيب وتحسين العلاج الجراحي المتأخر لاعتلال مفصل الورك بفقر الدم المنجلي من خلال تحسين تعليم الأطباء الذين يتعاملون مع مرضى داء الكريات المنجلية. حيث من الضروري تعيين وتدريب ودعم الأطباء المهممين بفقر الدم المنجلي. نظراً لأن داء الكريات المنجلية يؤثر بشكل أساسي على المرضى الصغار، فهناك حاجة إلى معيار دولي لتوقيت المعالجة الجراحية لاعتلال مفصل الورك في داء الكريات المنجلية.

الكلمات المفتاحية: تنخر عظم رأس الفخذ؛ اعتلال المفاصل؛ رأب مفاصل مرضى فقر الدم المنجلي؛ مرض فقر الدم المنجلي؛ وعي الطبيب

Abstract

Objectives: Sickle cell disease (SCD) is associated with femoral head osteonecrosis and is treated with hip arthroplasty 18 weeks after presentation. However, there is inadequate data regarding the timing of surgical management of severe hip arthropathy. This study explores the problem of delayed diagnosis and surgical management of severe SCD hip arthropathy by comparing the clinical outcomes of patients from Nigeria, Canada and Britain.

Methods: This is a prospective clinical audit of the routine care of 30 adult SCD patients who underwent hip arthroplasty for femoral head osteonecrosis. The clinical data are collected from five medical centers in Britain, Canada and Nigeria and compared.

Results: Hip arthroplasty was delayed beyond 18 weeks in 3 of 14 Nigerian patients (21%), 7 of 10 British patients (70%) and all 6 Canadian patients (100%). The majority

* Corresponding address. Department of Anesthesiology, University of British Columbia, P.O. Box 75085, Vancouver, BC, V4A 0B1, Canada.

E-mail: olu.bamgbade@gmail.com (O.A. Bamgbade)

Peer review under responsibility of Taibah University.



of Nigerian patients (79%) and only 30% of British patients had diagnostic imaging and surgical management without delay.

Conclusion: Inadequate physician awareness and delayed surgical management of SCD hip arthropathy can be mitigated by improving the education of physicians who manage patients with SCD. It is essential to recruit, train and support physicians with an interest in SCD. As this primarily affects young patients, it is necessary to set an international standard for the timing of surgical management of SCD hip arthropathy.

Keywords: Femoral head osteonecrosis; Physician awareness; Sick cell arthropathy; Sick cell arthroplasty; Sick cell disease

© 2021 The Authors.

Production and hosting by Elsevier Ltd on behalf of Taibah University. This is an open access article under the CC BY-NC-ND license (<http://creativecommons.org/licenses/by-nc-nd/4.0/>).

Introduction

Sickle cell disease (SCD) is an inherited hemoglobinopathy that can cause major systemic complications.^{1–16} During hypoxia, the defective haemoglobin causes erythrocyte deformity, which consequently creates vaso-occlusive crisis and causes significant pain, the leading cause of SCD hospitalisation.^{1,4,16} SCD negatively impacts the cardiovascular, respiratory, gastrointestinal, renal, neurologic, ocular and skeletal systems.^{4–16} Although the disease is particularly common in people of African and Arabian descent,¹⁶ it is also present in the Caribbean, Central America, South America, central India, the Mediterranean, Britain, Canada and the United States of America.^{15–20} For example, SCD affects 2–3% of the Nigerian population (which is made up of 160 million people),² as well as approximately 5,000 Canadians²¹ and 14,000 people in Britain.²² As a result of improved medical care and life expectancy of SCD patients, the proportion of patients with femoral head osteonecrosis, a major complication that usually requires hip arthroplasty, has increased.^{5–8} About 16% of adult SCD patients now present significant femoral head osteonecrosis, which requires total hip arthroplasty.^{5,6,8}

The multiple comorbidities and frequent hospitalisations associated with SCD may cause psychological problems for these patients and elicit negative attitudes from clinicians.^{17,18} The peculiar dilemma of misconception, mistrust, bias, ignorance, stigma, negativity and pessimism has become a major problem between SCD patients and their clinicians.^{17,18} These negative factors may cause or constitute treatment delay, barriers, underutilisation or disparity among SCD patients,¹⁸ particularly given that severe sickle cell hip arthropathy should be treated with hip arthroplasty within 18 weeks of presentation.¹⁹ Despite this growing issue, there are insufficient data regarding the timeliness of surgical diagnosis and treatment of severe sickle cell hip arthropathy. This prospective clinical audit

evaluates the process and timing of the surgical management of severe femoral head osteonecrosis in a cohort of 30 adult patients with SCD. The study explores some of the barriers of surgical care and factors that contribute to delayed hip arthroplasty.

Materials and Methods

This study presents a prospective clinical audit of the routine medical care of patients with sickle cell hip arthropathy. This quality assurance project was approved by the relevant healthcare facilities, which confirmed that approval from the research ethics board is not required. Routine clinical data were collected from the contemporaneous medical records of consenting adult patients who had undergone hip arthroplasty for femoral head osteonecrosis and were radiologically graded Stage VI on the Steinberg classification system.^{14,23} The collected data include age, race, gender, smoking habits, alcohol use, regular analgesic use, clinical features of hip arthropathy, primary healthcare facility type, hospital location, diagnostic imaging types, diagnostic imaging findings, duration from initial presentation at primary healthcare facility to the day of definitive diagnostic imaging and duration from initial presentation at primary healthcare facility to the day of the hip arthroplasty. The quantitative and qualitative data are presented in [Table 1](#), which include numbers, ranges, categories and descriptions.

Results

[Table 1](#) highlights patients' data, including the patients' country, healthcare setting and race. The time from presentation to arthroplasty is compared to highlight these categories.

Eleven African SCD patients from a Nigerian hospital's outpatient department are included in this study. All these patients had a waddling gait and chronic hip pain, which were managed with daily intake of non-steroidal anti-inflammatory drug (NSAID). These adult males did not smoke or use other substances. Examinations, X-rays and computed tomography (CT) scans that were performed 4–6 weeks after presentation indicated femoral head osteonecrosis. They underwent uncemented hip arthroplasty 11–12 weeks after presentation.

Three African SCD patients from a Nigerian rehabilitation clinic are also included. These patients had buttock claudication and severe chronic hip pain, which was managed with daily intake of NSAID. These adult males did not drink or smoke. Initial physical and X-ray examinations were inconclusive, but CT scans performed 6–9 weeks after presentation highlighted femoral head osteonecrosis. They had uncemented hip arthroplasty 20–24 weeks after presentation.

Six African SCD patients from an urgent clinic in Canada are also included. These patients had acute-on-chronic hip and thigh pain, which was managed using regular prescription of opioid analgesics and no other drug or substances. Appropriate examinations and X-rays were performed 6–8 weeks after presentation and magnetic resonance imaging (MRI) was completed by 13–16 weeks, which confirmed

Table 1: Patient details and clinical information.

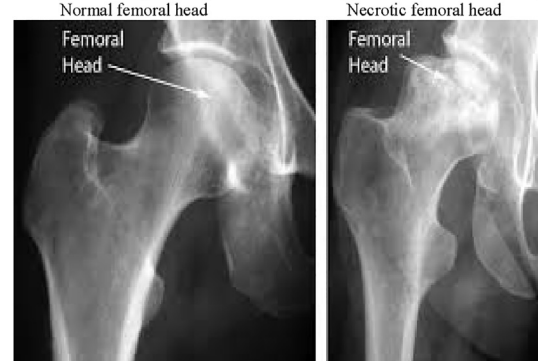
Population	Race	Age range (years)	Smoking, Alcohol.	Regular chronic analgesic	Primary healthcare facility	Country	Clinical presenting features	Imaging type	CT or MRI findings	Time from presentation to CT, MRI	Time from presentation to arthroplasty
11	African	20–35	None	NSAID	Hospital outpatient	Nigeria	Chronic hip pain, waddling gait	X-ray, CT scan	CT scan: femoral head necrosis	4–6 weeks	11–12 weeks
3	African	18–32	None	NSAID	Rehabilitation clinic	Nigeria	Severe hip & buttock claudication	X-ray, CT scan	CT scan: femoral head necrosis	6–9 weeks	20–24 weeks
6	African	40–51	None	Opioid	Urgent clinic	Canada	Acute on chronic hip & thigh pain	X-ray, MRI scan	MRI scan: femoral head necrosis	13–16 weeks	48–52 weeks
4	Arab	33–41	None	NSAID Opioid	Urgent clinic	Britain	Severe buttock pain & limp	X-ray, MRI scan	MRI scan: femoral head necrosis	8–12 weeks	26–36 weeks
3	African	40–52	None	NSAID Opioid	Urgent clinic	Britain	Severe buttock pain & limp	X-ray, MRI scan	MRI scan: femoral head necrosis	8–12 weeks	26–36 weeks
3	African	37–45	None	Opioid	Community clinic	Britain	Chronic worsening hip pain	X-ray, MRI scan	MRI scan: femoral head necrosis	3–6 weeks	10–12 weeks

CT=Computed Tomography; MRI = Magnetic Resonance Imaging; NSAID=Non-steroidal anti-inflammatory drug.

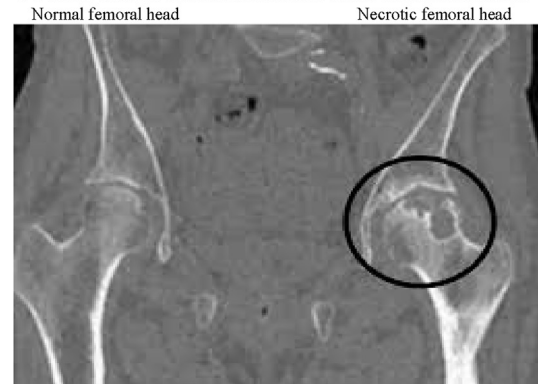
femoral head osteonecrosis. They underwent cemented hip arthroplasty between 48 and 52 weeks after presentation.

Four Arab and three African SCD patients from an urgent clinic in Britain are also included. These patients had a limp and severe buttock pain, which was managed with daily NSAID and occasional opioid analgesic intake. These adult males did not use tobacco, alcohol or other drugs. Initial physical and X-ray examinations were inadequate and the CT scans performed at 2–5 weeks were inconclusive. MRIs were performed at 8–12 weeks, which confirmed that they had femoral head osteonecrosis. Furthermore, they had

XRay shows joint space narrowing & acetabular change.²³



CT scan shows osteosclerosis around necrotic bones.²³



MRI scan shows osteosclerosis & necrotic bone tissue.²³

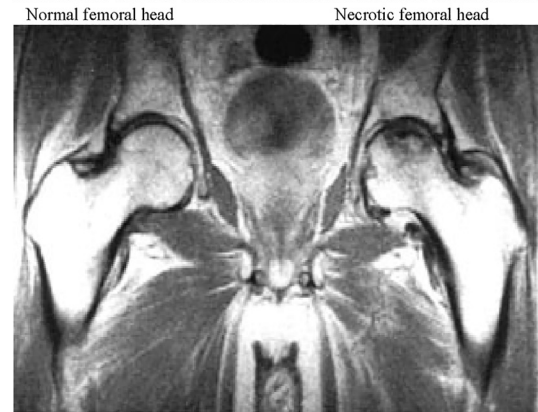


Figure 1: Images of femoral head osteonecrosis.

cemented hip arthroplasty between 26 and 36 weeks after the initial presentation.

Three African SCD patients from a British community clinic are also included. They all had worsening chronic hip pain and regularly took prescribed opioid analgesics to treat it but no other drugs or substances. Examinations, X-rays and MRIs confirmed the presence of femoral head osteonecrosis. MRIs were performed by 3–6 weeks and they developed uncemented hip arthroplasty within 10–12 weeks after the initial presentation.

Discussion

SCD patients with severe hip arthropathy or osteonecrosis should undergo hip arthroplasty within 18 weeks after its initial presentation.¹⁹ Arthroplasty may be performed in less than 18 weeks if the patient's situation is severe and this course of action is deemed appropriate.¹⁹ Delayed surgery impairs the quality of life of these young patients, who are in their prime and desperate for definitive therapy.⁶ Delayed surgery may also increase analgesia or drug dependency and misuse. This prospective clinical audit shows delayed surgery (i.e. beyond 18 weeks) in 3 of 14 Nigerian patients (21%), 7 of 10 British patients (70%), and all 6 Canadian patients (100%). The majority of the Nigerian patients (79%) included in this study had surgical management without delay, which is an encouraging outcome. This is likely to be related to Nigerian physicians' familiarity, confidence, knowledge, and experience treating SCD, since it is the most common genetic disease in Nigeria, which is also the most populated African country.^{1–3} Therefore, Nigerian physicians are probably more knowledgeable or experienced than British and Canadian physicians in terms of diagnosing and managing SCD hip arthropathy or osteonecrosis.

The Nigerian patients had definitive diagnostic imaging using X-rays and CT scans, whereas the Canadian and British patients had definitive diagnoses using MRI scans.^{14,23} According to the Steinberg classification system, the outcome of imaging in all the patients showed Stage VI or advanced degeneration, which indicates that hip arthroplasty is the optimal treatment.²³ In Nigeria, MRIs are not routinely used to diagnose hip osteonecrosis, since CT scans are more affordable and readily available. The Nigerian imaging approach may be due to resource management and greater familiarity with the CT scan features of SCD arthropathy or osteonecrosis, such as showing areas of osteosclerosis around necrotic bones.²³ Therefore, the use of the CT scan imaging option may contribute to the relatively early diagnosis and surgery of Nigerian patients. While MRIs are the imaging of choice because of their sensitivity and specificity in the early radiological diagnosis of hip osteonecrosis, X-rays and CT scans are also reliable when it comes to diagnosing hip osteonecrosis and guiding treatment. Examples of femoral head osteonecrosis images from different radiologic modalities are shown in [Figure 1](#).

In this study, Nigerian SCD patients were generally younger than the British and Canadian patients. This may indicate that SCD patients in Nigeria develop major complications, such as femoral head osteonecrosis, at an earlier

stage. One explanation for this could be the relatively low socioeconomic status, poor nutrition and inadequate medical care. Additionally, Nigerian patients only used NSAID for chronic pain management, whereas Canadian and British patients primarily used opioid analgesics. This may be related to different cultures in terms of patients' pain perception, as well as analgesia prescription by physicians and healthcare resource management. For example, it is possible that the greater availability, accessibility and prescription rates of opioids in Britain and Canada may contribute to opioid overuse in these countries.

The majority of British (70%) and Canadian patients (100%) experienced delayed diagnoses and surgical management of SCD hip arthropathy or osteonecrosis. In countries such as Britain and Canada, physicians in primary care, emergency care, radiology and surgical or other services may be less familiar with SCD and/or its peculiar clinical features. Therefore, these physicians may be more likely to underdiagnose or misdiagnose SCD femoral osteonecrosis. There is evidence that delayed or disparate emergency medical treatments of SCD patients is a common problem, which may be due to institutional, systemic, racial, sociocultural and economic factors of patients and physicians.¹⁸ For example, negative stereotypical traits associated with African, Arab and/or SCD patients include poor education, low socioeconomic status, malingering and hostility, which may contribute to the disparity of care.¹⁸

Additionally, the bias of physicians, stigmatizing language and negative attitudes may exacerbate the disparate medical treatment of SCD patients. Physicians may have misconceptions that SCD patients over-report pain or abuse drugs and over-use medical services.^{17,18} Some of these attitudes can be negatively interpreted by SCD patients, and this may worsen the experience and outcome of SCD patients.^{17,18} Physicians' attitudes may also cause SCD patients to be cynical, uncooperative and non-compliant with treatment.¹⁸ In other words, medical care may be limited by physicians' lack of confidence, comfort, communication, training and knowledge.^{18,24} These types of limitations can be mitigated by providing physicians who are likely to treat SCD patients with continuous and better medical education. It may also be useful to identify, recruit, train and support physicians for treating SCD patients.

This clinical audit is partly limited by its small sample size, which further limited the statistical analysis; therefore, larger studies ought to be used to verify these findings in future studies. Furthermore, the audit was unable to explore the complexity of the medical comorbidities and possible pre-operative medical or haematological optimisation. It is possible that the varying quality of pain management in patients may influence physicians' perception of the urgency of surgical intervention. It is likely that the use of different imaging modalities may affect the timing of diagnosis, but there are insufficient data on the different imaging modalities. In addition to comparing countries, it may also be useful to compare the annual volume of SCD arthroplasty patients at different healthcare centres, since the elective surgery burden at each centre could affect the timing of surgery.

Conclusion

This prospective clinical audit highlights problems related to the delayed management of SCD hip arthropathy. In particular, it shows the variance in the level of physician awareness and inadequate management of surgical time. Furthermore, it confirms that CT scans are reliable for diagnosing advanced SCD hip arthropathy and may expedite surgical management because it is more readily available and affordable compared to MRI scans. These discrepancies in treating SCD hip arthropathy indicate the need for an international standard on the timing of surgical intervention, because this debilitating disease affects young patients in the prime of their life.

Recommendations

It is necessary to make physicians more aware of the treatment disparity among SCD hip arthropathy patients. Better physician knowledge will improve attitudes towards SCD patient care. This can be achieved through cultural competency training programs for physicians and the recruitment of physicians from African or Arab minority groups, which can reduce the delay of SCD hip arthropathy management. Comprehensive multidisciplinary clinical guidelines should be designed and implemented by centres that frequently care for SCD patients.

Source of funding

This research did not receive any specific grant from funding agencies in the public, commercial or non-profit sectors.

Conflict of interest

The authors have no conflict of interest to declare.

Ethical approval

This clinical audit is a quality assurance project that was approved by the relevant healthcare facilities, who confirmed that approval from the research ethics board was not required.

Authors' contribution

OAB, VO, AAC, DAO, PSB and RNR were involved in the conception, design, data collection, data analysis & interpretation, writing initial & final drafts, proof-reading, critical review and approval of the final draft of the manuscript. All authors have critically reviewed and approved the final draft and are responsible for the content and similarity index of the manuscript.

References

- Okongwu CI, Fasola FA, Adekanmi AJ, Onifade AA. Morbidity pattern and interferon gamma level in sickle cell anemia patients with autsplenectomy. *Niger J Clin Pract* 2018 Dec; 21(12): 1615–1621. https://doi.org/10.4103/njcp.njcp_217_18. PMID: 30560826.
- Adewoyin AS. Management of sickle cell disease: a review for physician education in Nigeria (sub-saharan Africa). *Anemia* 2015; 791498. <https://doi.org/10.1155/2015/791498>. Epub 2015 Jan 18. PMID: 25667774; PMCID: PMC4312619.
- Chinawa JM, Emodi IJ, Ikefuna AN, Ocheni S. Coagulation profile of children with sickle cell anemia in steady state and crisis attending the university of Nigeria teaching hospital, Ituku-Ozalla, Enugu. *Niger. J Clin Pract* 2013 Apr-Jun; 16(2): 159–163. <https://doi.org/10.4103/1119-3077.110132>. PMID: 23563454.
- Adebiyi AA, Oyebowale OM, Olaniyi AJ, Falase AO. Heart rate variability study in adult Nigerian subjects with sickle cell disease during vaso-occlusive crisis. *Niger Postgrad Med J* 2019 Jan-Mar; 26(1): 8–12. https://doi.org/10.4103/npmj.npmj_186_18. PMID: 30860193.
- Akinyoola AL, Adediran IA, Asaley CM. Avascular necrosis of the femoral head in sickle cell disease in Nigeria: a retrospective study. *Niger Postgrad Med J* 2007 Sep; 14(3): 217–220. PMID: 17767206.
- Katchy AU, Anyaehie UE, Nwadinigwe CU, Eyichukwu GO. Total hip replacement in sickle cell disorder: a preliminary report of challenges and early outcome of 21 consecutive patients. *Niger J Clin Pract* 2018; 21: 492–495. https://doi.org/10.4103/njcp.njcp_182_17.
- Ekere AU, Eze CB, Ebirim LN. A report of two cases of uncemented total hip replacement in patients with sickle cell disease. *Niger J Clin Pract* 2008; 11: 257–259.
- Ugbeye ME, Lawal W, Ayodabo O, Dim EM, Adegoke S. Total hip arthroplasty in sickle cell disease patients in a developing country. *Niger J Clin Pract* 2020; 23: 1426–1430. https://doi.org/10.4103/njcp.njcp_402_19.
- Alhawsawi ZM, Alshenqeti AM, Alqarafi AM, Alhussayen LK, Turkistani WA. Cholelithiasis in patients with paediatric sickle cell anaemia in a Saudi hospital. *J Taibah Univ Med Sci* 2019 Apr 2; 14(2): 187–192. <https://doi.org/10.1016/j.jtumed.2019.02.007>.
- Yahaya IA. Biochemical features of hepatic dysfunction in Nigerians with sickle cell anaemia. *Niger Postgrad Med J* 2012; 19: 204–207.
- Akuyam SA, Abubakar A, Lawal N, Yusuf R, Aminu SM, Hassan A, et al. Assessment of biochemical liver function tests in relation to age among steady state sickle cell anemia patients. *Niger J Clin Pract* 2017; 20: 1428–1433. https://doi.org/10.4103/njcp.njcp_14_17.
- Lagunju IA, Brown BJ, Sodeinde OO. Stroke recurrence in Nigerian children with sickle cell disease treated with hydroxyurea. *Niger Postgrad Med J* 2013; 20: 181–187.
- Babalola OE, Wambebe CO. Ocular morbidity from sickle cell disease in a Nigerian cohort. *Niger Postgrad Med J* 2005; 12: 241–244.
- Manzary M. Total hip arthroplasty in sickle cell disease. *Reconstr Rev* 2016; 6: 37–42. <https://reconstructivereview.org/ojs/index.php/rr/article/view/137>.
- Madu AJ, Okoye AE, Ajuba IC, Madu KA, Anigbo C, Agu K. Prevalence and associations of symptomatic renal papillary necrosis in sickle cell anemia patients in South-Eastern Nigeria. *Niger J Clin Pract* 2016; 19: 471–474. <https://doi.org/10.4103/1119-3077.183299>.
- Zolaly M, Al-Mohammadi G, Al-Saadi G, Qasim D. Vaso-occlusive crises in patients with sickle cell disease: parents' perspectives and association with disease outcomes. *J Taibah Univ Med Sci* 2019; 14: 515–522. <https://doi.org/10.1016/j.jtumed.2019.09.006>.
- Aloba O, Eyiolawi D. Correlates of hopelessness in clinically stable Nigerian adults with sickle cell disease. *Niger J Clin Pract* 2020; 23: 219–225. https://doi.org/10.4103/njcp.njcp_119_19.

18. Haywood Jr C, Lanzkron S, Hughes M, Brown R, Saha S, Beach MC. The association of clinician characteristics with their attitudes toward patients with sickle cell disease: secondary analyses of a randomized controlled trial. **J Natl Med Assoc** 2015; 107: 89–96. [https://doi.org/10.1016/S0027-9684\(15\)30029-8](https://doi.org/10.1016/S0027-9684(15)30029-8).
19. Arthritis and Musculoskeletal Alliance (ARMA). *Policy position paper on joint replacement surgery. 'Rationing' access to joint replacement surgery and impact on people with arthritis*; August 2017 <http://arma.uk.net/arma-policy-position-paper-on-joint-replacement-surgery/>.
20. Kenanidis E, Kapriniotis K, Anagnostis P, Potoupnis M, Christofilopoulos P, Tsiridis E. Total hip arthroplasty in sickle cell disease: a systematic review. **EFORT Open Rev** 2020; 5: 180–188. <https://doi.org/10.1302/2058-5241.5.190038>.
21. Government of Canada. *National sickle cell awareness day. June 19, 2018*; 2018 <https://www.canada.ca/en/health-canada/news/2018/06/message-from-the-minister-of-health-national-sickle-cell-awareness-day-june-19-2018.html>.
22. Dormandy E, James J, Inusa B, Rees D. How many people have sickle cell disease in the UK? **J Public Health (Oxf)** 2018 Sep 1; 40(3): e291–e295. <https://doi.org/10.1093/pubmed/idx172>. PMID: 29294057.
23. Zhao D, Zhang F, Wang B, Liu B, Li L, Kim SY, et al. Guidelines for clinical diagnosis and treatment of osteonecrosis of the femoral head in adults (2019 version). **J Orthop Translat** 2020 Jan 6; 21: 100–110. <https://doi.org/10.1016/j.jot.2019.12.004>. PMID: 32309135; PMCID: PMC7152793.
24. Alnasser YS, Bin Nafisah HM, Almubarak ZA, Aleisa LA, El Sarrag AI, Babiker AM. Communication skills between physicians' insights and parents' perceptions in a teaching hospital in KSA. **J Taibah Univ Med Sci** 2016 Oct 10; 12(1): 34–40. <https://doi.org/10.1016/j.jtumed.2016.09.002>.

How to cite this article: Bamgbade OA, Onongaya V, Anomneze-Collins A, Omoniyi DA, Simmonds-Brooks P, Richards RN. Delayed surgical diagnosis and treatment of severe sickle cell arthropathy: The need to raise clinicians' awareness. **J Taibah Univ Med Sc** 2021;16(5):683–688.