

## Original Article

## The effects of platelet-rich fibrin on post-surgical complications following removal of impacted wisdom teeth: A pilot study

Ibrahim Nourwali, PhD

Department of Oral and Maxillofacial Surgery, College of Dentistry, Taibah University, Germany

Received 22 November 2020; revised 4 February 2021; accepted 8 February 2021; Available online 13 March 2021



### المخلص

**أهداف البحث:** الفيبرين الغني بالصفائح الدموية عبارة عن مصفوفة من الفيبرين تحتوي على الخلايا، والسيوتوكينات، وعوامل النمو، والتي يمكن تحريرها بعد وقت محدد من الدم، وتعمل كغشاء قابل للذوبان. وقد أظهرت العديد من الدراسات فوائد الفيبرين الغني بالصفائح الدموية في شفاء العظام في جراحة زراعات الوجه والفكين. تقيم دراستنا تأثير الفيبرين الغني بالصفائح الدموية على مضاعفات ما بعد الجراحة بعد قلع أسنان العقل المنحشرة.

**طرق البحث:** تم ضم ٢٠ مريضا في هذه الدراسة السريرية العشوائية المنضبطة. ١٠ مرضى في مجموعة الدراسة و ١٠ في المجموعة المراقبة. وتتراوح أعمار المرضى بين ١٨ و ٤٠ سنة. تم إجراء القلع الجراحي للأسنان المصابة #٣٨ #٤٨ في جميع المرضى. خضعت مجموعة الدراسة لعملية جراحية سنخية سنخية مع استخدام الفيبرين الغني بالصفائح الدموية، في حين خضعت مجموعة التحكم لعملية جراحية بدون الفيبرين الغني بالصفائح الدموية.

**النتائج:** أبلغ جميع المرضى في مجموعة الدراسة عن ألم أقل بكثير بعد الجراحة، وشفاء الأنسجة الرخوة الممتاز خلال فترة المتابعة. في المقابل، كان ٨٠٪ فقط من المرضى في مجموعة التحكم شفاء الأنسجة الرخوة لديهم جيدا. ولم يكن الفرق بين التورم بعد الجراحة بين المجموعتين ذي أهمية إحصائية. بالإضافة إلى ذلك، أفاد ٦٩٪ من المرضى في مجموعة الدراسة عن نوم ليلي مريح خلال اليوم الأول بعد الجراحة مقارنة بنسبة ٣١٪ في مجموعة التحكم. وكان هذا الفرق ذا دلالة إحصائية.

**الاستنتاجات:** استنادا إلى نتائج دراستنا، فإن زرع الفيبرين الغني بالصفائح الدموية في مواقع القلع الجراحي يمكن أن يكون مفيدا في تقليل الألم بعد الجراحة وتحسن شفاء الأنسجة الرخوة. استخدام الفيبرين الغني بالصفائح الدموية في مكان القلع بسيط وآمن بيولوجيا. الآثار المفيدة للفيبرين الغني بالصفائح الدموية تدعم تطبيقه في مجالات جراحة الأسنان.

**الكلمات المفتاحية:** التهاب النقيصة السنخية؛ الجراحة السنخية السنخية؛ الأسنان المنحشرة؛ ألم الأسنان؛ الفيبرين الغني بالصفائح الدموية؛ قلع الأسنان

### Abstract

**Objectives:** Platelet-rich fibrin (PRF) is a fibrin matrix composed of cells, cytokines, and growth factors, which may be liberated from blood at specific times and act as a resorbable membrane. Many studies have demonstrated the benefits of PRF for bone healing in oral and maxillofacial implant surgery. Our study assesses the impact of PRF on postoperative complications following the extraction of impacted wisdom teeth.

**Methods:** Twenty patients were recruited in this blind controlled randomised clinical trial, i.e. ten patients in the study group and ten patients in the control group. The patients were aged between 18 and 40 years. Surgical removal of impacted teeth #38 and #48 was performed in all the patients. The study group underwent dentoalveolar surgery with the use of PRF, while the control group underwent surgery without PRF.

**Results:** All patients in the study group reported significantly less postoperative pain ( $p = 0.02$ ) and excellent soft tissue healing during the follow-up period ( $p = 0.021$ ). In contrast, only 80% of patients in the control group exhibited sufficient soft tissue healing. The difference in postoperative swelling between the two groups was not statistically significant. Additionally, 69% of patients in the study group reported comfortable night sleep during the first 24 h after the operation compared to 31% in the control group. This difference was statistically significant ( $p = 0.02$ ).

**Conclusion:** Based on the outcomes of our study, implanting PRF into surgical extraction sites can be helpful in reducing postoperative pain and improving soft tissue healing. The use of PRF in extraction sockets is simple and biologically safe. The beneficial effects of PRF

E-mail: [ibrahim\\_germany@hotmail.com](mailto:ibrahim_germany@hotmail.com)

Peer review under responsibility of Taibah University.



Production and hosting by Elsevier

support its possible application in the field of dental surgery.

**Keywords:** Alveolar osteitis; Dental pain; Dentoalveolar surgery; Impacted teeth; Platelet rich fibrin; Tooth extraction

Clinical trial registration: ISRCTN13878305

© 2021 The Author.

Production and hosting by Elsevier Ltd on behalf of Taibah University. This is an open access article under the CC BY-NC-ND license (<http://creativecommons.org/licenses/by-nc-nd/4.0/>).

## Introduction

Surgical extraction of impacted teeth is a common procedure in dentoalveolar surgery. In particular, it is widely used for removal of impacted wisdom teeth, which affect numerous young people due to several reasons, and most of them cannot be prevented.<sup>1,2</sup>

The majority of patients undergoing extraction of impacted teeth complain of some or all of the following postoperative complications: postoperative swelling, severe pain, limitations in the ability to open the mouth, infection, and delayed socket healing.<sup>3</sup> Studies were conducted in an attempt to reduce these complications by using prophylactic antibiotics<sup>4</sup> and intravenous or submucosal corticosteroid injections into the area impacted by surgery.<sup>5</sup>

The second generation of platelet concentrate, platelet-rich fibrin (PRF), stems from an anticoagulant-free blood collection that permits fibrin membranes to be supplemented with platelets and various growth factors. PRF is similar to a fibrin complex that allows for the production of fibrin and cell migration, facilitating tissue healing. Studies have shown that PRF placement aids bone formation in the tooth socket and improves the periodontal condition.<sup>6</sup>

Based on these observations, PRF was hypothesised to be useful for decreasing or eliminating complications associated with surgical extraction of impacted teeth.<sup>7</sup> Therefore, a Turkish study on 20 patients with bilateral soft tissue impacted mandibular third molars was conducted to ascertain the benefits of PRF in enhancing the healing of sockets following tooth extraction. However, the study results demonstrated an insignificant difference between the use and non-use of PRF.<sup>7</sup>

In another study conducted in India on 20 patients, the results were based on a radiographic assessment 3 months after the extraction procedure. The study demonstrated an enhancement in the healing of extraction sockets, a reduction in pain levels, and increased bone density when PRF was used. These observations indicated that PRF might be useful in advancing and accelerating the regeneration of soft and hard tissue.<sup>8</sup>

This study aims to investigate the effectiveness of PRF in reducing the postoperative pain, bleeding, and swelling

associated with surgical removal of impacted lower third molars under local anaesthesia.

## Materials and Methods

This single-blind clinical trial was performed in the Department of Oral and Maxillofacial Surgery (DOMFS) at the Taibah University College of Dentistry (TUCoD). Patients undergoing wisdom tooth extraction were approached and informed of the study's value, aims, surgical technique, postoperative period, and potential associated difficulties. A signed informed consent form in Arabic was obtained from each participant before the procedure. When a patient was illiterate, a co-patient or an assistant was asked to read out the consent form to him/her.

The inclusion criterion was the presence of unilateral or bilateral impacted lower third molars requiring extraction. Participants aged 18–40 years who fulfilled the American Society of Anaesthesiologists grade I criteria were included in the study.<sup>9</sup> The exclusion criteria were systemic illness such as diabetes, hypertension, bleeding disorders, immunodeficiencies, mental retardation, and physical disabilities; pregnancy; lactation; or uncooperativeness of a patient.

Patients who met the inclusion criterion were invited to participate in the study. A total of 20 patients were enrolled. The participants were divided into a study group ( $n = 10$ ), which underwent conventional dentoalveolar surgery using surgical burs and the implantation of PRF in the socket of the extracted teeth, and a control group ( $n = 10$ ), which underwent conventional dentoalveolar surgery using surgical burs without the implantation of PRF in the socket of the extracted teeth.

### *Surgical procedure*

All procedures were performed by the same oral surgeon and assistant. Prior to surgery, all participants underwent a radiological examination, which included a panoramic radiograph. In both the control and study groups, the flap incision was an envelope flap with a distal extension. The surgical procedures were performed following administration of a local anaesthetic agent inducing a nerve block for the inferior alveolar, lingual, and long buccal nerve for mandibular third molars. The regional and infiltration anaesthesia for the surgical extractions included 0.012 mg/mL adrenaline hydrochloride and 40 mg/mL articaine hydrochloride.

During all surgical procedures, the extractions were accomplished by elevating a full-thickness mucoperiosteal flap. Following the reflection of the mucoperiosteal flap in the conventional dentoalveolar surgery, osteotomy was performed with a 1.6-mm round bur attached to a Kavo straight surgical handpiece, using copious irrigation. All the teeth were completely removed.

In the study group, the PRF was implanted into the extraction socket following the tooth extraction. In the control group, a sterile physiological saline solution was used to wash the extraction sockets. The post-extraction sockets in both groups were closed using 3–0 polyglycolic acid

resorbable sutures. The sutures were inspected after 7 days and removed after 2 weeks. A gauze pack was placed on the surgical site and held in place by asking the patient to bite on it for 30 min. Patients were instructed to apply cold packs on the operative site at intervals of 15 min for 6 h upon arrival at home. All participants were advised to eat soft and cold meals for 24 h after the operation. The clinical parameters were examined on postoperative days 1, 2, 3, and 7. All postoperative examinations were performed at approximately the same time of the day. Two weeks postoperatively, the patients were called back for suture removal and assessment of postoperative soft tissue healing.

Postoperatively, the patients were administered amoxicillin/clavulanate potassium 625 mg PO, one capsule three times daily for 5 days, or clindamycin 300 mg PO, a capsule three times daily for 5 days, and ibuprofen 400 mg PO, three times daily for 5 days. The participants were also instructed to use a normal saline mouthwash three times daily for 7 days after the first postoperative day.

#### *Evaluation procedure*

The participants were asked to use a visual analogue scale (VAS) to evaluate their postoperative pain and bleeding at 1 h, 2 h, and 6 h after surgery, as well as at night and the next morning. Pain was assessed using a five-point scale, with grade 0 indicating no pain; grade I indicating very weak pain; grade II indicating weak pain; grade III indicating moderate pain; grade IV indicating severe pain; and grade V indicating extreme pain.

Bleeding was assessed on a four-point scale, with grade 0 indicating no bleeding; grade I indicating mild bleeding; grade III indicating moderate bleeding; and grade IV indicating severe bleeding.

Postoperative follow-up also included the assessment of swelling and soft tissue healing. Swelling was assessed as any clinical finding that appeared during the first 4 postoperative days. Soft tissue healing was assessed and documented according to the Landry and Turnbull criteria<sup>10</sup> (Table 1).

#### *PRF preparation protocol*

The French Ministry of Health recognised the current standard preparation technique for PRF developed by Choukroun. This technique allows for PRF to be harvested from blood without using an anticoagulant or bovine thrombin throughout the gelling.<sup>7</sup>

A conventional PRF preparation protocol is followed to obtain a proper measure and excellence of the fibrin matrix, leucocytes, platelets, and growth factors. The equipment for PRF harvesting is comprised of a table centrifuge and a blood collection set containing a 23-gauge butterfly needle and 10 mL blood collection tubes (UNICO® power spin centrifuge) (Figure 1a). In our study, after the injection of local anaesthesia to the operation side, a 10-mL blood sample was drawn from each participant and placed in 10-mL tubes devoid of

anticoagulants. The blood obtained was immediately centrifuged at 3000 rpm for 10 min. During the centrifugation process, when the blood was in contact with the test-tube wall, the platelets became activated, causing initiation of the coagulation cascade. Following centrifugation, the resulting product in the test tube comprised three layers. The uppermost layer contained acellular platelet-poor plasma, the middle layer contained a PRF clot, and the lowermost layer of the test tube contained red blood cells (RBCs).

After centrifugation, the obtained fibrin clot was detached from the tube, and the attached RBCs were scraped off and discarded. PRF can also be obtained in a membrane form by extracting the fluid from the fibrin clot, which is mandatory in the alveolar socket of extraction within 4–6 min of PRF insertion. The period between blood collection and centrifugation is a crucial factor influencing the success and clinical outcomes of the technique. The delay in processing the drawn blood causes diffuse fibrin polymerisation, resulting in the development of small blood clots with abnormal consistency.<sup>6,11</sup>

Data were analysed using the Statistical Package for the Social Sciences IBM SPSS Statistics version 23. Descriptive statistics in terms of frequency and percentages were used, and percentages were used for categorical variables. Inferential statistical analysis was then followed by the chi-square test for group comparisons. The level of significance was set at  $p < 0.05$ , to control for alpha error.

The clinical trial was registered at BioMed Central, a database of Springer Nature, under the registration number ISRCTN13878305.

This is a single-blind study, and none of the patients were aware of the nature of the material applied to their surgical site. Only the surgeon was aware of this information. However, this information was not known to the statistician.

## **Results**

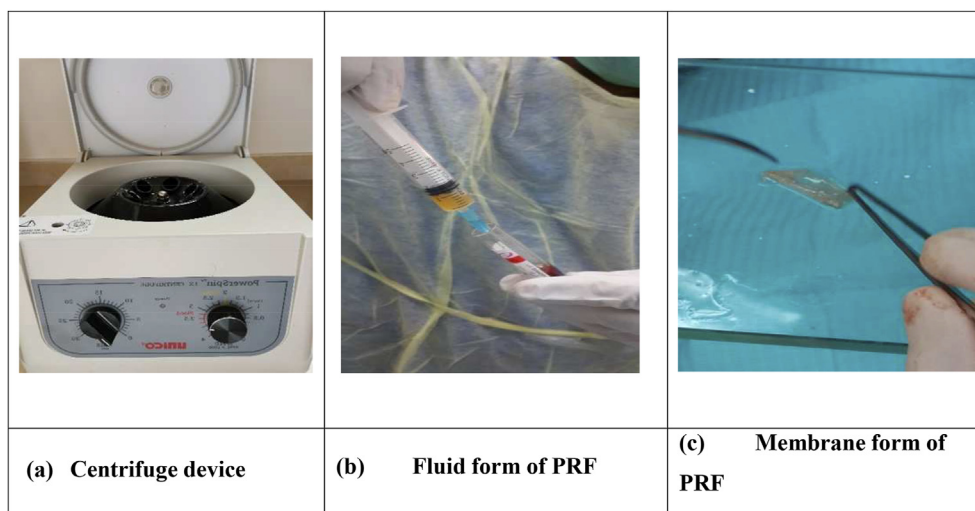
This single-blind clinical trial study was performed at DOMFS at TUCoD. In this clinical study, ten patients underwent surgical wisdom tooth extraction with PRF, while the other ten underwent the procedure without PRF use. Following surgery, 69% of PRF participants reported having a comfortable night's sleep on the first postoperative day compared to 31% in the control group, and the difference was statistically significant ( $p = 0.02$ ) (Table 2).

The number of patients in the study group who experienced no pain in the first hour after the extraction was slightly higher than that in the control group. This trend was also observed during the various postoperative periods, but it was insignificant ( $p > 0.05$ ) (Table 3).

The study group participants demonstrated less postoperative bleeding during various postoperative follow-up periods. In the study group in the first hour, postoperative bleeding occurred with a higher frequency than in the control group. The difference was significant ( $p = 0.044$ ) (Table 4).

**Table 1: Evaluation of soft tissue healing according to the Landry and Turnbull criteria.**

<b>(1) Very poor</b>	Tissue colour: More than 50% of the gingiva is red; Response to palpation: Bleeding; Granulation tissue: Present; Incision Margin: Not epithelialised with loss of epithelium beyond incision margin; Suppuration: Present.
<b>(2) Poor</b>	Tissue colour: More than 50% of the gingiva is red; Response to palpation: Bleeding; Granulation tissue: Present; Incision Margin: Not epithelialised, with connective tissue exposed; Suppuration: No.
<b>(3) Good</b>	Tissue colour: 25% to 50% of the gingiva is red; Response to palpation: No bleeding; Granulation tissue: None; Incision Margin: No connective tissue exposed; Suppuration: No.
<b>(4) Very good</b>	Tissue colour: Less than 25% of the gingiva is red; Response to palpation: No bleeding; Granulation tissue: None; Incision Margin: No connective tissue exposed; Suppuration: No.
<b>(5) Excellent</b>	Tissue colour: All tissues are pink; Response to palpation: No bleeding; Granulation tissue: None; Incision Margin: No connective tissue exposed; Suppuration: No.

**Figure 1:** (a) Table centrifuge, (b) Fluid form of PRF, (c) Membrane form of PRF.**Table 2: Comparison of degree of comfort between the study and control groups during the first postoperative night.**

Degree of comfort	First night's sleep	
	Study N (%)	Control N (%)
Comfortable	9 (69.2)	4 (30.8)
Uncomfortable	1 (14.3)	6 (85.7)
<b>X<sup>2</sup></b>	<b>5.49</b>	
<b>p value</b>	<b>0.02*</b>	

\* Statistical significance at  $p < 0.05$ .

However, this observation was not reflected in other postoperative periods.

From the onset of the 1st, 2nd, 6th, and 8th postoperative day, a greater number of participants demonstrated lower degrees of postoperative swelling in the study group than in the control group. However, this difference between the groups was not significant ( $p > 0.05$ ) (Table 5).

In this study, the Landry et al. index was used to assess whether PRF could influence the restoration of soft tissue covering the extraction sockets. The current study demonstrated a significant difference ( $p = 0.021$ ) in

**Table 3: Comparison of degree of postoperative pain between the study and control groups in various postoperative periods.**

Degree of pain	Periods of postoperative pain									
	1 h postoperatively		2 h postoperatively		6 h postoperatively		First postoperative night		First postoperative day	
	Study	Control	Study	Control	Study	Control	Study	Control	Study	Control
	N (%)	N (%)	N (%)	N (%)	N (%)	N (%)	N (%)	N (%)	N (%)	N (%)
No pain	6 (60)	5 (50)	4 (40)	3 (30)	2 (20)	1 (10)	5 (50)	1 (10)	3 (30)	2 (20)
Mild-to-moderate pain	4 (40)	3 (30)	5 (50)	5 (50)	6 (60)	7 (70)	5 (60)	7 (70)	7 (70)	4 (40)
Severe-to-very severe pain	0	2 (20)	1 (10)	2 (20)	2 (20)	2 (20)	0	2 (20)	0	4 (40)
<b>X<sup>2</sup></b>	<b>2.234</b>		<b>0.476</b>		<b>0.41</b>		<b>5</b>		<b>5.018</b>	
<b>p value</b>	<b>0.327</b>		<b>0.778</b>		<b>0.815</b>		<b>0.82</b>		<b>0.81</b>	

**Table 4: Comparison of degree of postoperative bleeding between the study and control groups during various postoperative periods.**

Degree of bleeding	Postoperative bleeding									
	1 h postoperatively		2 h postoperatively		6 h postoperatively		First postoperative night		First postoperative day	
	Study	Control	Study	Control	Study	Control	Study	Control	Study	Control
	N (%)	N (%)	N (%)	N (%)	N (%)	N (%)	N (%)	N (%)	N (%)	N (%)
No bleeding	4 (40)	0	3 (30)	0	3 (30)	2 (20)	5 (50)	5 (50)	7 (70)	6 (60)
Mild-to-moderate bleeding	4 (40)	9 (90)	5 (50)	9 (90)	5 (50)	8 (80)	4 (40)	5 (50)	3 (30)	4 (40)
Severe bleeding	2 (20)	1 (10)	2 (20)	1 (10)	2 (20)	0	1 (10)	0	0	0
<b>X<sup>2</sup></b>	<b>6.256</b>		<b>4.476</b>		<b>2.892</b>		<b>1.111</b>		<b>0.22</b>	
<b>p value</b>	<b>0.044*</b>		<b>0.107</b>		<b>0.235</b>		<b>0.574</b>		<b>0.639</b>	

\*Statistically significant p < 0.05.

**Table 5: Comparison of degree of postoperative swelling between the study and control groups during various postoperative periods.**

Degree of Swelling	Postoperative swelling							
	First postoperative night		1 day postoperatively		48 h postoperatively		72 h postoperatively	
	Study	Control	Study	Control	Study	Control	Study	Control
	N (%)	N (%)	N (%)	N (%)	N (%)	N (%)	N (%)	N (%)
No swelling	4 (40)	2 (20)	3 (30)	2 (20)	2 (20)	0	3 (30)	0
Mild-to-moderate swelling	6 (60)	7 (70)	6 (60)	5 (50)	4 (40)	6 (40)	6 (60)	9 (90)
Severe-to-very severe swelling	0	1 (10)	1 (10)	3 (30)	4 (40)	4 (40)	1 (10)	1 (10)
<b>X<sup>2</sup></b>	<b>1.744</b>		<b>1.291</b>		<b>2.4</b>		<b>3.6</b>	
<b>p value</b>	<b>0.418</b>		<b>0.524</b>		<b>0.301</b>		<b>0.165</b>	

**Table 6: Comparison of degree of postoperative soft tissue restoration between the study and control groups during the postoperative period.**

Degree of soft tissue healing	Soft tissue healing	
	Study	Control
	N (%)	N (%)
Very poor – poor	0	2 (20)
Good – very good	5 (50)	8 (80)
Excellent	5 (50)	0
<b>X<sup>2</sup></b>	<b>7.692</b>	
<b>p value</b>	<b>0.021*</b>	

\* statistically significant p < 0.05.

the influence of PRF on soft tissue restoration. All of the study group participants had excellent soft tissue healing after 14 days, whereas the majority (80%) of the participants in the control group claimed only good soft tissue healing (Table 6), as assessed by a clinical evaluation.

**Discussion**

The findings of our study show that patients in the study group had significantly less postoperative pain than patients

in the control group. This difference was significant during the postoperative evaluation period (Table 3).

Surgical extraction of bony impacted teeth is a traumatic procedure that produces bleeding, pain, and swelling. Recently, many studies have been conducted to enhance the healing course and reduce associated postoperative complications.<sup>4,5,12</sup>

The healing process consists of three phases, i.e. inflammation, fibroplasia, and maturation. These phases are governed by numerous growth factors that migrate and infiltrate the injured site during healing. Application of growth factors to wounds accelerates the healing process by accelerating granulation tissue establishment and enriching epithelialisation, which has been shown in studies of topical application of growth factors. However, the application of topical growth factors should not be considered as an alternative for reliable wound care, including surgical debridement or revascularisation.<sup>13</sup>

Zarei et al. studied the therapeutic effects of granulocyte-macrophage colony-stimulating factor, platelet-derived growth factor, transforming growth factor- $\beta$ , vascular endothelial growth factor, and basic fibroblast growth factor on chronic wounds and concluded that wound healing is a complex biological process that involves numerous types of cells that are controlled and regulated by several growth factors and cytokines.<sup>14</sup>

The literature data on the impact of PRF on pain and swelling following surgical extraction of impacted molars are scarce.<sup>15</sup> This study aims to explore the outcome of the use of PRF on postoperative pain, the inflammatory response following surgical extraction of impacted teeth, and postoperative bleeding.

PRF contains numerous autogenous cytokines and immune cells and a high concentration of inactive, functional or intact platelets that release a continuous concentration of their contents over a period of 7 days. The fibrin membrane that protects the operative site can be stitched in place, and then the PRF becomes capable of stimulating bone regeneration as a result of osteoblastic proliferation, which has been demonstrated to affect neo-angiogenesis.<sup>16</sup>

Pain is defined as an unpleasant sensation and emotional experience linked to tissue damage, which allows the body to counter and thwart additional tissue damage. It is considered a vital function of the nervous system as it is detected by sensory receptors from the injured sites and transmitted to the central nervous system as electrical signals.<sup>17</sup>

In the current study, a reduced amount of pain was observed in the study group compared to the control group (Table 3). This observation might stem from the effect of PRF on pain reduction. The use of autogenous PRF in the extraction site contributes to quicker healing and pain reduction. Studies by Ozgul,<sup>8</sup> Gülşen,<sup>18</sup> and Singh<sup>19</sup> used a VAS to measure the level of postoperative pain, demonstrating a statistically insignificant difference in the postoperative pain between study groups on the 1st, 3rd, and 7th days, although the pain was lower at the PRF sites. In another study, Uyanık et al. used a larger sample size and a different method and were able to demonstrate a statistical difference in the group that received PRF.<sup>15</sup> These contradicting literature reports might result from

individual variations in the pain threshold and the surgical techniques used.

Bleeding is commonly related to tooth extractions (simple and surgical) and usually stops with the formation of a blood clot. In patients suffering from blood disorders, the bleeding may not stop quickly, and they need special pre-and post-operative management according to their clinical situation.<sup>20,21</sup>

In this study, we observed significantly less bleeding in the study group than in the control group (Table 4). This result may be explained by the presence of enriched platelets and abundant growth factors derived from PRF, in addition to the use of the suture technique and the individual variation in the body's response.

Swelling takes 2–3 days after surgery to reach its maximum. Then, it subsides gradually; this is part of the inflammatory process and is frequently observed after surgical extractions on the side of extraction around the cheeks, mouth, and eyes, bringing discomfort to patients.<sup>20</sup> In this study, there was a statistically insignificant difference in the degree of swelling during the first 24 h between the study group and the control group (Table 5). This observation was also confirmed on postoperative days 2 and 7. These results mirror those of Uyanık,<sup>15</sup> Gülşen,<sup>18</sup> and Ozgul,<sup>8</sup> who stated that there were insignificant differences in swelling on the 1st day post-surgery. They also reported statistically insignificant differences on the 3rd and 7th postoperative days.

The socket healing starts when the blood clot is formed within the first 24 h after tooth extraction. Subsequently, granulation tissue is formed to fill in the tissue lost during the extraction.<sup>22</sup> Other studies have shown similar findings to ours regarding the healing process (Table 6). The granulation tissue transforms into connective tissue before being replaced with bone. The healing of an extraction socket involves both bone and soft tissue remodelling occurring subsequently over the first 3 months post-extraction.<sup>23</sup> The use of PRF is justified by the fact that platelets provide a reservoir of several growth factors which play a pivotal role in both hard- and soft tissue healing process.<sup>24</sup>

Two weeks postoperatively, the soft tissue healing was more proficient in the study group than in the control group, and the difference was statistically significant (Table 6). The improvement in the healing process could be explained by the presence of platelet cytokines, growth factors, and other cells at the sites where PRF was implanted. The PRF in a membrane form acts as a fibrin bandage for clots that fill the extraction socket, hence serving as a matrix to accelerate the healing of wound edges. Neovascularisation begins due to the presence of the PRF clot, and epithelial covering develops over the surgical site.<sup>24</sup> The postoperative soft tissue site heals by primary intention.<sup>25</sup> As a result, the PRF membrane used in extraction sockets has been shown to stimulate local soft tissue healing of gums and reduce the postoperative pain response.<sup>26</sup>

The results of the current study (Table 5) are mirrored by findings of studies conducted by Uyanık et al.,<sup>15</sup> Singh et al.,<sup>19</sup> and Bansal et al.,<sup>26</sup> which determined that PRF accelerates the soft tissue healing process seen clinically and impacts the socket healing process.

A study by Daugela et al.<sup>27</sup> reported that PRF improved soft tissue healing and reduced postoperative pain, swelling, and incidence of alveolar osteitis after impacted mandibular third molar surgical extractions. Moreover, PRF increased dental implant stability 1 week and 1 month after surgery.<sup>28</sup> However, dental implants coated with bone morphogenetic protein (BMP) have a better effect on stability than those coated with PRF alone and those without PRF or BMP.<sup>29</sup>

The main limitation of this study is the limited number of participants enrolled in the trial.

## Conclusions

Based on the outcomes of this study, implanting PRF into surgical extraction sites seems to reduce postoperative pain and bleeding and improve soft tissue healing. Postoperative pain and swelling did not differ significantly; the study demonstrated an excellent clinical response. Using PRF implanted into an extraction socket is simple, biologically safe, and relatively cheap, with a reasonably straightforward chairside preparation. The current study also demonstrated that nominal surgeon expertise was needed to perform PRF preparation and grafting compared to bone harvesting from distant sites.

## Recommendations

Further studies are recommended to evaluate the effects of PRF on postoperative complications associated with the surgical extraction of impacted lower third molars and to examine the impact of PRF on bone remodelling.

## Source of funding

This research did not receive any specific grant from funding agencies in the public, commercial, or not-for-profit sectors.

## Conflict of interest

The authors have no conflict of interest to declare.

## Ethical approval

Ethical approval was obtained from the Research Ethics Committee (TUCD-REC) (protocol number TUCDREC/20160204/29/02/2016).

## References

- Lysell L, Rohlin M. A study of indications used for removal of the mandibular third molar. *Int J Oral Maxillofac Surg* 1988; 17(3): 161–164.
- Aitasalo K, Lehtinen R, Oksala E. An orthopantomography study of prevalence of impacted teeth. *Int J Oral Surg* 1972; 1(3): 117–120.
- Pourmand PP, Sigron GR, Mache B, Stadlinger B, Locher MC. The most common complications after wisdom-tooth removal: part 2: a retrospective study of 1,562 cases in the maxilla. *Swiss Dent J* 2014; 124(10): 1047–51, 1057–1061.
- Poeschl PW, Eckel D, Poeschl E. Postoperative prophylactic antibiotic treatment in third molar surgery—a necessity? *J Oral Maxillofac Surg* 2004; 62(1): 3–8.
- Graziani F, D’Aiuto F, Arduino PG, Tonelli M, Gabriele M. Perioperative dexamethasone reduces post-surgical sequelae of wisdom tooth removal. A split-mouth randomized double-masked clinical trial. *Int J Oral Maxillofac Surg* 2006; 35(3): 241–246.
- Lee JT. Current therapy. In: *Oral and maxillofacial surgery*. 1st ed. Saunders: Elsevier Inc; 2012. pp. 146–149.
- Choukroun J, Diss A, Simonpieri A, Girard M-O, Schoeffler C, Dohan SL, et al. Platelet-rich fibrin (PRF): a second-generation platelet concentrate. Part IV: clinical effects on tissue healing. *Oral Surgery. Oral Med Oral Pathol Oral Radiol Endodontology* 2006 Mar; 101(3): e56–e60.
- Ozgul O, Senses F, Er N, Tekin U, Tuz HH, Alkan A, et al. Efficacy of platelet rich fibrin in the reduction of the pain and swelling after impacted third molar surgery: randomized multicenter split-mouth clinical trial. *Head Face Med* 2015; 11(1): 37.
- Doyle DJ, Garmon EH. *American society of anesthesiologists classification (ASA Class)*. Treasure Island (FL): StatPearls Publishing; 2020 Feb 17. StatPearls [Internet], 2020 Jan-.
- Landry RG, Turnbull RSHT. Effectiveness of benzydamine HCl in the treatment of periodontal post-surgical patients. *Res Clin Forums* 1988; 10: 105–118.
- Naik B, Karunakar P, Jayadev M, Marshal VR. Role of Platelet rich fibrin in wound healing: a critical review. *J Conserv Dent* 2013; 16(4): 284–293.
- Susarla SM, Smart RJ, Dodson TB. Complications associated with dentoalveolar surgery. In: Andersson Lars, Karl-Erik KMP, editors. *Oral and maxillofacial surgery*. 1st ed. Blackwell Publishing Ltd; 2011. pp. 155–157.
- Steed DL. The role of growth factors in wound healing. *Surg Clin* 1997; 77(3): 575–586.
- Zarei FSM. Role of growth factors and biomaterials in wound healing. *Artif Cells, Nano-medicine. Biotechnol* 2018; 46(S1): S906–S911.
- Uyanik LO, Bilginaylar K, Etikan İ. Effects of platelet-rich fibrin and piezosurgery on impacted mandibular third molar surgery outcomes. *Head Face Med* 2015; 11(1): 25.
- Zhang Y, Ruan Z, Shen M, Tan L, Huang W, Wang L, et al. Clinical effect of platelet-rich fibrin on the preservation of the alveolar ridge following tooth extraction. *Exp Ther Med* 2018; 15(3): 2277–2286.
- Basbaum AI, Bautista DM, Scherrer G, Julius D. Cellular and molecular mechanisms of pain. *Cell* 2009; 139(2): 267–284.
- Gülşen U, Sentürk MF. Effect of platelet rich fibrin on edema and pain following third molar surgery: a split mouth control study. *BMC Oral Health* 2017; 17(1): 79.
- Singh A, Kohli M, Gupta N. Platelet rich fibrin: a novel approach for osseous regeneration. *J Maxillofac Oral Surg* 2012; 11(4): 430–434.
- Elitsa G, Deliverska MP. Complications after extraction of impacted third molars - literature review. *J IMAB* 2016; 22(3): 1202–1211.
- Garmo C, Burns B. *Physiology, clotting mechanism*. StatPearls. StatPearls Publishing; 2019.
- Moran IJ, Richardson L, Heliotis M, Bewick A. A bleeding socket after tooth extraction. *BMJ* 2017 Apr 3; 357: j1217.
- Pippi R. Post-surgical clinical monitoring of soft tissue wound healing in periodontal and implant surgery. *Int J Med Sci* 2017; 14(8): 721–728.
- Sharma NK. Platelet-rich fibrin: emerging biomaterial in regeneration. *Natl J Maxillofac Surg* 2018; 9(1): 1.
- Barrientos S, Stojadinovic O, Golinko MS, Brem H, Tomic-Canic M. Growth factors and cytokines in wound healing. *Wound Repair Regen* 2008; 16(5): 585–601.

26. Bansal S, Garg A, Khurana R, Chhabra P. Platelet-rich fibrin or platelet-rich plasma – which one is better? an opinion. **Indian J Dent Sci** 2017; 9(5): 49.
27. Daugela P, Grimuta V, Sakavicius D, Jonaitis J, Juodzbals G. Influence of leukocyte- and platelet-rich fibrin (L-PRF) on the outcomes of impacted mandibular third molar removal surgery: a split-mouth randomized clinical trial. **Quintessence Int** 2018; 49(5): 377–388. <https://doi.org/10.3290/j.qi.a40113>. PMID: 29629438.
28. Canellas JVDS, Medeiros PJD, Figueredo CMDS, Fischer RG, Ritto FG. Platelet-rich fibrin in oral surgical procedures: a systematic review and meta-analysis. **Int J Oral Maxillofac Surg** 2019 Mar; 48(3): 395–414. <https://doi.org/10.1016/j.ijom.2018.07.007>. Epub 2018 Jul 30. PMID: 30072300.
29. Alhussaini AHA. Effect of platelet-rich fibrin and bone morphogenetic protein on dental implant stability. **J Craniofac Surg** 2019 Jul; 30(5): 1492–1496. <https://doi.org/10.1097/SCS.0000000000005131>. PMID: 31299751.

**How to cite this article:** Nourwali I. The effects of platelet-rich fibrin on post-surgical complications following removal of impacted wisdom teeth: A pilot study. *J Taibah Univ Med Sc* 2021;16(4):521–528.