



Case Report

A rare case of the superior vena cava obstruction in a 16-year-old boy with Burkitt's lymphoma: A case report



Mohammad N. Alfahadi, MBBS^{a,*}, Fatima A. Malik, MD^b,
Alzahraa S. Almahlawi, MBBS^b and Wejdan A. Alhamdan, MBBS^a

^a College of Medicine, King Saud bin Abdulaziz University for Health Sciences, Riyadh, KSA

^b Division of Internal Medicine, Department of Medicine, King Abdulaziz Medical City, Ministry of National Guard – Health Affairs, Riyadh, KSA

Received 25 November 2020; revised 19 December 2020; accepted 21 December 2020; Available online 7 January 2021

المخلص

سرطان الغدد الليمفاوية بيركيت، هو سرطان يصيب الغدد الليمفاوية اللاهودجكينية من النوع ب (الخلايا اللمفاوية أو اللمفاويات البائية). انسداد الوريد الأجوف العلوي يُعتبر من النادر حدوثه مع سرطان الغدد الليمفاوية بيركيت، وهو غالبا يحدث مع الأنواع الأخرى من سرطان الغدد الليمفاوية اللاهودجكينية مثل سرطان الخلايا الكبيرة. نبلغ في هذا التقرير عن حالة نادرة لسرطان الغدد الليمفاوية بيركيت من النوع المتفرق مع انسداد الوريد الأجوف العلوي لدى صبي يبلغ من العمر ١٦ عاما مصابا بكتل سرطانية في البلعوم، المنصف الصدري والغدة الكظرية. المريض أتى بانتفاخ في الجزء الأيسر العلوي من الرقبة لمدة شهرين، مع ازدياد الحجم مع مرور الوقت بدون أية أعراض أخرى، وفي اليوم الثاني من التنويم تم اختبار المريض لفايروس كورونا (كوفيد-١٩) وكانت النتيجة إيجابية. في الفحص السريري كان لديه انتفاخ في الغدة اللمفاوية الرقبية وانتفاخان في الجهتين من الغدد اللمفاوية الأذنوية الخلفية. لم يكن هناك شينا ملحوظا في الاختبار الصدري باستثناء بعض الدوالي الوريدية على صدر المريض. لم يكن هناك أية أعراض أو علامات لانسداد الوريد الأجوف العلوي بغض النظر عن نتائج الأشعة المقطعية. بدأ المريض على العلاج الكيميائي المكثف، وكانت لديه استجابة ملحوظة للعلاج في الكتل السرطانية في البلعوم والمنصف الصدري، مع استجابة طفيفة للكتلة السرطانية في الغدة الكظرية. لم يكن هناك أية مضاعفات ملحوظة.

الكلمات المفتاحية: سرطان الغدد الليمفاوية بيركيت؛ انسداد الوريد الأجوف العلوي؛ البلعوم؛ المنصف الصدري؛ الغدة الكظرية

Abstract

Burkitt's lymphoma (BL) is an aggressive non-Hodgkin B-cell lymphoma. Superior vena cava obstruction (SVCO) is considered a rare presentation of BL and it is usually associated with other types of non-Hodgkin lymphoma such as diffuse large-cell. We report a rare case of sporadic BL with SVCO in a 16-year-old boy with nasopharyngeal, mediastinal, and adrenal masses. The patient presented with a two-month history of left upper neck swelling that increased with time and was not associated with other symptoms. The patient tested positive for COVID-19 on the second day after admission. On examination, he had enlarged solitary lateral cervical and bilateral posterior auricular lymph nodes. There were no signs or symptoms of SVCO regardless of the findings suggested by the computed tomography of the chest. The patient was treated with hyper-CVAD chemotherapy and showed a remarkable resolution of the nasopharyngeal and mediastinal masses with a mild response of his adrenal mass. There were no complications detected during this patient's management.

Keywords: Adrenal; Burkitt's lymphoma; Mediastinal; Nasopharyngeal; Superior vena cava obstruction

© 2021 The Authors.

Production and hosting by Elsevier Ltd on behalf of Taibah University. This is an open access article under the CC BY-NC-ND license (<http://creativecommons.org/licenses/by-nc-nd/4.0/>).

* Corresponding address: College of Medicine, King Saud bin Abdulaziz University for Health Sciences, P.O. Box 7535, Riyadh, 13225, KSA.

E-mail: Alfahadi172@gmail.com (M.N. Alfahadi)

Peer review under responsibility of Taibah University.



Introduction

Burkitt's lymphoma (BL) is a high-grade B-cell non-Hodgkin lymphoma.¹ It comprises approximately 1–5% of all non-Hodgkin lymphomas (NHL), and is more common in males.¹ In KSA, it comprises 17.6% of all cases of NHL.² The World Health Organization has classified BL into three types: endemic, sporadic, and immunodeficiency associated. These forms are phenotypically and histologically identical, but they present differently.³ The Epstein–Barr virus (EBV) is closely associated with all cases of the endemic variant.³ The cause is less clear for the sporadic form; however, it is also associated with EBV in some cases. Immunodeficiency type is associated with HIV, congenital immunodeficiency, and organ transplants.³ BL often presents with an asymptomatic mass or some of the characteristic symptoms for each type.⁴ The endemic form usually presents with jaw lesions, genitourinary involvement, or periorbital swelling.³ The sporadic form mainly manifests in the abdomen, yet the head and neck could be involved too.³ Sporadic form patients usually present with nausea, vomiting, abdominal distention, gastrointestinal bleeding, and ileocecal disease.³ Constitutional symptoms such as fever, night sweats, and weight loss are more likely to be found in adult patients for each type of BL.⁴ BL rarely affects the mediastinum, which can either obstruct superior vena cava, or affects the central nervous system of the patient.⁵ Sampling of lymph nodes superficially by excisional biopsy is preferred for diagnosis.⁶ The overall cure rate is 90% in paediatrics and young adults for sporadic BL, where systemic chemotherapy is considered the gold standard treatment⁷ and this is stratified according to the patient's age and stage. This case report describes a 16-year-old adolescent male with a sporadic presentation found to have adrenal, nasopharyngeal, and mediastinal masses with superior vena cava compression identified with computed tomography (CT) and excisional biopsy. The aim of this case report is to describe the uncommon clinical and anatomical manifestations of sporadic BL.

Case presentation

A 16-year-old Middle Eastern adolescent with a two-month history of left upper neck swelling noticed incidentally that it was increasing with time, however, there was no association with fever, weight loss, or night sweats. There were no local symptoms such as pain, tenderness, redness, or pus discharge. Previously, he had a history of five days of fever and sore throat that resolved spontaneously. He denies any other swelling in his body. The patient tested positive for COVID-19 and symptoms started on the second day after admission. He is neither sexually active, an IV drug user, nor an alcohol drinker, and there is no radiation exposure. His vaccinations are up to date, and his father died from an unknown malignancy. On examination, he had a single lateral cervical swelling, firm and fixed, non-tender 4×4 cm, no fluctuation, and non-sinuses. He had bilateral posterior auricular swelling (2×1 , 2×3), no supraclavicular, or

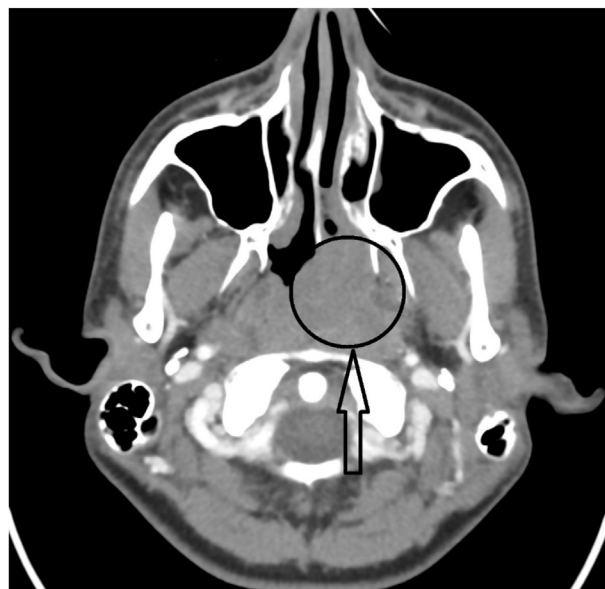

Figure 1: Brain CT.

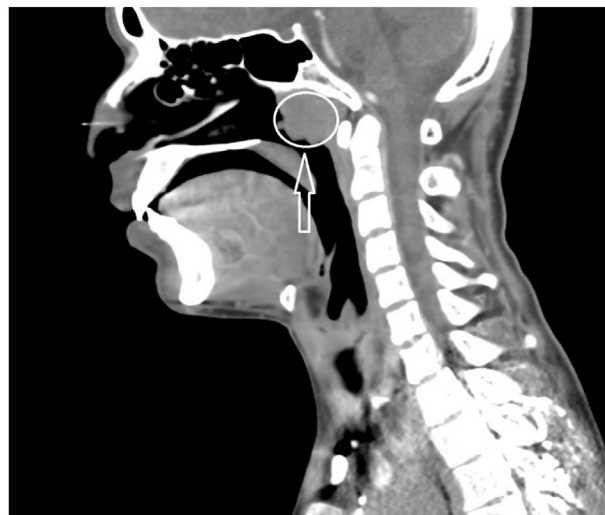
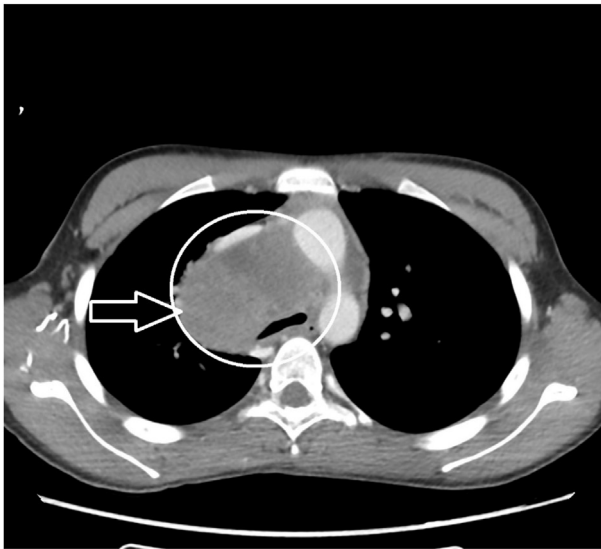
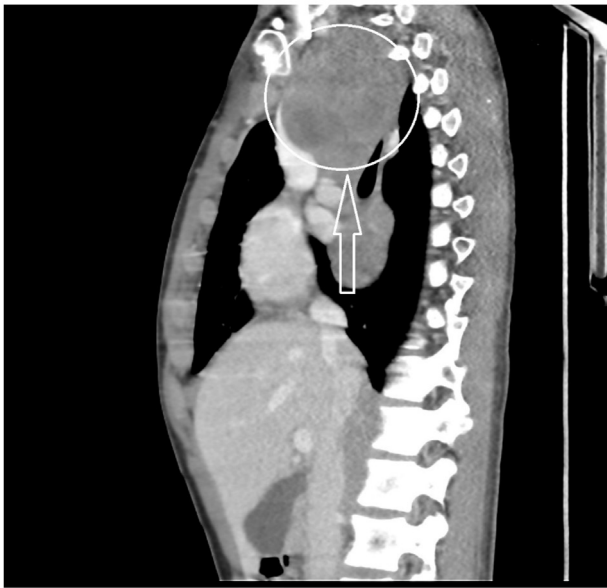Figure 2: Neck CT.

axillary or inguinal palpable lymph nodes (LN). His chest exam was normal aside from dilated veins on his chest; the cardiac and abdominal exams were also normal. His brain CT showed a lobulated left nasopharyngeal mass lesion extending into the left nasal cavity, measuring 4.3×3.5 cm (Figure 1). His neck CT showed an enlarged cervical LN at left level II, measuring $3.9 \times 3.1 \times 5.7$ cm (AP \times ML \times CC) and an enlarged, partially calcified right retropharyngeal LN, measuring 2.4×2.3 cm (Figure 2).



A



B

Figure 3: A. Chest CT. B. Chest CT.

His chest CT showed that the superior vena cava and azygos were compressed by a large right mediastinal mass extending to the superior and posterior mediastinum in the subcarinal region measuring approximately $8 \times 6.3 \times 15$ cm (Figure 3A & B). His abdominal CT showed a right adrenal multilobulated heterogeneous low attenuation mass, measuring $6.5 \times 6.5 \times 4.5$ cm, which was indenting the liver and pushing the right kidney down (Figure 4). The cerebrospinal fluid analysis result was negative. The patient was managed using the treatment including systematic chemotherapy which had undetectable complications.

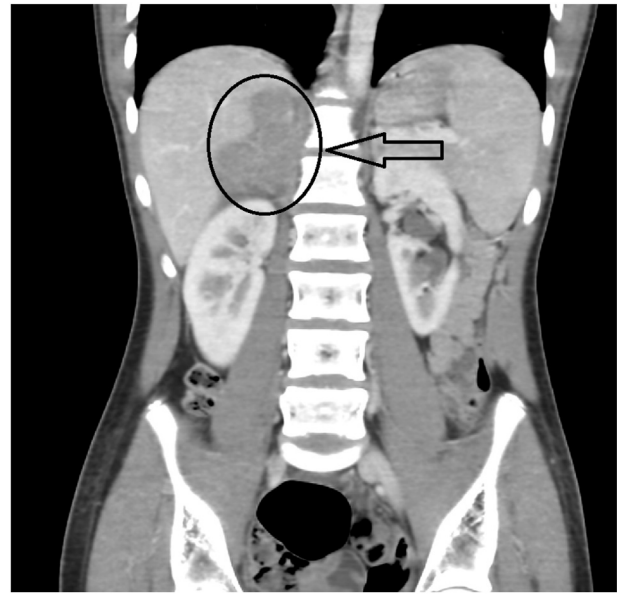


Figure 4: Abdominal CT.

Discussion

Sporadic BL has no specific geographic distribution.⁴ It accounts for 1% of adult NHL in the US.⁵ The majority of patients are male, with a 3–4:1 male:female ratio.⁸ The average age at diagnosis is 30 years, and the peak at 50 years or older.⁴ BL patients often present with an asymptomatic mass or may have associated systemic symptoms such as fever, drenching night sweats, and unexplained weight loss.⁴ Other symptoms which can be present with BL include fatigue, weakness, anorexia, and pruritus.⁴ There are uncommon intrathoracic manifestations of BL that include pericardial and myocardial involvement, lung parenchymal and endobronchial lesions, and chest wall masses, presenting with single or multiple masses.⁹ In emergent presentations of BL, cardiac tamponade will appear as a large pericardial effusion with cardiac chamber distortion and signs of reduced cardiac output.¹⁰

Sporadic BL mainly presents with abdominal masses that originate from the lymphoid tissue in the terminal ileum or respiratory mass.⁸ Mesenteric and retroperitoneal LN enlargement are the most common sites.⁸ On the other hand, the head and neck are the characteristically most common sites of involvement in the endemic form of BL, occurring in up to 50–60% of all cases.¹¹ Extra-nodal involvement of sporadic BL often includes the cecum, distal ileum, stomach, and/or mesentery, kidney, ovaries, testes, and central nervous system involvement.⁸ Head and neck involvement of sporadic BL is most likely to be in Waldeyer's ring, which includes the palatine, lingual tonsils, and adenoids of the nasopharynx.¹² The Epstein–Barr virus is associated with approximately 30% of all sporadic cases.⁸ This case had a positive antibody for EBV. On

the other hand, 90% of endemic BL cases are associated with EBV.⁸

A review of the literature suggests that nasopharyngeal BL occurs only in childhood.¹³ However, one case has been reported of a 72-year-old Caucasian male with symptomatic nasopharyngeal mass.¹³ It is further estimated that 4% of NHL patients showed evidence of adrenal gland involvement.¹⁴ Those with adrenal involvement usually present with adrenal insufficiency symptoms such as abdominal pain, fatigue, anorexia, weight loss, or hyperpigmentation.¹⁴ However, in this case the patient was asymptomatic despite the adrenal involvement.

BL rarely presents with mediastinal masses that obstruct the superior vena cava.⁵ It is estimated that 2–4% of superior vena cava obstruction (SVCO) is caused by NHL.⁵ The incidence of SVCO in NHL varies according to the subtype. Of these, diffuse large-cell and lymphoblastic lymphomas are the most common.⁵ It is critical to recognise the SVCO and its aetiology early to avoid complications. Patients with SVCO usually present with a cough, dyspnoea, facial or neck swelling, distended neck veins, or bleeding upper extremity swelling.¹⁵ Unexpectedly, this case was asymptomatic despite CT findings that showed that the superior vena cava and azygos vein were compressed by the mediastinal mass, causing multiple dilated tortuous collaterals in the upper thorax. A histopathological sample is required to diagnose the masses. It rarely requires emergency management unless there are critical presentations such as haemodynamic instability or airway obstruction. In this case, endovascular stenting is required, followed by a long-term anticoagulant. After stenting, chemotherapy is started to shrink the tumour's size and prevent recurrence. The prognosis generally depends on the type of malignancy.

The risk factors in sporadic BL are unknown other than infectious agents; however, there is a study that observed and investigated risk factors of sporadic BL in 295 cases which showed that BL in younger patients was positively associated with a history of eczema among individuals without other atopic conditions and inversely associated with a history of allergy.⁴ Regardless of age, BL was positively associated with height and inversely associated with alcohol consumption.⁴ This patient had a positive antibody for EBV and positive family history of unknown cancer.

Due to the tumour's sensitivity to cytotoxic agents, systematic chemotherapy is considered the gold standard treatment.⁷ Surgical management may be considered for debulking or to remove the primary site in case of obstruction.⁷ A favourable prognosis is estimated to be approximately 80–90% in paediatrics and 50–60% in adults.⁷ This case was managed by using hyper-CVAD chemotherapy; this consists of two courses (A & B) that are given frequently with smaller doses. Course A involves cyclophosphamide, vincristine, and doxorubicin, and course B consists of methotrexate and cytarabine. The patient had a marked response to the treatment with improvement in the size of his nasopharyngeal mass and reduction of his mediastinal mass from 8.8 cm to 6.1 cm. He also had a mild decrease in his adrenal mass. The patient is still undergoing chemotherapy treatment.

We could not find any correlation between COVID-19 infection and lymphoma; however, one study showed increased SARS-CoV-2 susceptibility in patients with haematological malignancies such as leukaemia, lymphoma, or myeloma.¹⁶ Patients with haematological cancers had a more severe COVID-19 disease trajectory and required more intensive clinical support, with additional risk conferred by recent chemotherapy use.¹⁶ The patient was tested for COVID-19 as a protocol of hospital admission and developed COVID-19 symptoms on the second day of presentation to hospital without a clear history of contact with COVID-19 patients.

Conclusion

BL is an extremely fast-growing lymphoma of B-cell type, and this signifies the importance of early diagnosis. Sporadic BL usually affects the head and neck, and cervical adenopathy is the most common presentation. These lymphomas are usually managed with systemic chemotherapy, with a favourable prognosis when detected early. This case described a rare presentation of SVCO in a 16-year-old boy with nasopharyngeal, mediastinal, and adrenal masses. The patient responded well to hyper-CVAD chemotherapy with no complications.

Source of funding

This research did not receive any specific grant from funding agencies in the public, commercial, or not-for-profit sectors.

Conflict of interest

The authors have no conflict of interest to declare.

Ethical approval

The authors certify that they obtained all appropriate patient consent forms. In the form, the patient gave consent for images and other clinical information to be reported in the journal. The patient understands that his name and initials will not be published, and due efforts will be made to conceal patient identity, but anonymity cannot be guaranteed.

Authors contributions

MNA conceived the article topic and did a literature review for many articles. ASA and WAA wrote the initial and final draft and provided logistic support for the content. FAM and MNA wrote and reviewed the radiological findings with a special radiologist. All authors checked for plagiarism and are jointly responsible if it is detected. All authors have critically reviewed and approved the final draft and are responsible for the content and similarity index of the manuscript.

References

1. Nagy G, Chira R, Crisan D, Munteanu M, Mircea PA. Unusual multiple metastatic localisations in adult Burkitt's lymphoma. A case report. *Med Ultrason* 2016; 18: 518–520.
2. Sabbah R, Ali A, Lewall D, Aur R. Burkitt's lymphoma in Saudi Arabia: clinical, pathological, and epidemiological analyses of 16 cases. *King Faisal Spec Hosp Med J* 1982 Apr; 2(2): 77–83.
3. Graham B, Lynch D. *Burkitt lymphoma*. 2020. Treasure Island (FL): StatPearls Publishing; 2020 Jan. First.
4. Carmona-Campos M. A rare presentation of Hodgkin lymphoma [Internet]. *Hematol Oncol*. [cited 2020Dec5]. Available from: <https://www.hematologyandoncology.net/archives/october-2011/a-rare-presentation-of-hodgkin-lymphoma/>.
5. Salhan D, Verma P, Naing T, Rehman E, Kandel S, Enriquez D, et al. Primary pulmonary lymphoma presenting with superior vena cava syndrome in a young female. *Case Rep Pulmonol* 2017; 2017: 1937107.
6. Moor JW, Murray P, Inwood J, Goulesbrough D, Bem C. Diagnostic biopsy of lymph nodes of the neck, axilla and groin: rhyme, reason or chance? *Ann R Coll Surg Engl* 2008; 90(3): 221–225.
7. Verma S. Burkitt's lymphoma: thorax to pelvis. *Indian J Chest Dis Allied Sci* 2016; 58: 49–51.
8. Blum K, Lozanski G, Byrd J. Adult Burkitt leukemia and lymphoma. *Blood* 2004; 104(10): 3009–3020.
9. Chan O, Igwe M, Breburda CS, Amar S. Burkitt lymphoma presenting as an intracardiac mass: case report and review of literature. *Am J Case Rep* 2016; 17: 553–558.
10. Kaul P, Javangula K. Burkitt lymphoma masquerading as cardiac tamponade. *J Cardiothorac Surg* 2007; 2: 30.
11. Dozzo M, Carobolante F, Donisi PM, Scattolin A, Maino E, Sancetta R, et al. Burkitt lymphoma in adolescents and young adults: management challenges. *Adolesc Health Med Ther* 2017; 8: 11–29.
12. Derinkuyu BE, Boyunağa O, Öztunali C, Tekkeşin F, Damar Ç, Alımlı AG, et al. Imaging features of Burkitt lymphoma in pediatric patients. *Diagn Interv Radiol* 2016; 22(1): 95–100.
13. Upile T, Jerjes W, Abiola J, Kafas P, Sandison A, Hamdoon Z, et al. A patient with primary Burkitt's lymphoma of the post-nasal space: case report [Internet] *Head Neck Oncol* 2012; 4: 33. BioMed Central.
14. Rizzo C, Camilleri DJ, Betts A, Gatt A, Fava S. Primary bilateral non-Hodgkin's lymphoma of the adrenal gland presenting as incidental adrenal masses [Internet] *Case Rep Med* 2015; 2015. Hindawi.
15. Lepper P, Ott Sebastian R, Hoppe H, Schumann C, Stammberger U, Bugalho A, et al. Superior vena cava syndrome in thoracic malignancies. *Respir Care* May 2011; 56(5): 653–666.
16. Lee L, Cazier J, Starkey T, Briggs S, Arnold R, Bisht V, et al. COVID-19 prevalence and mortality in patients with cancer and the effect of primary tumour subtype and patient demographics: a prospective cohort study. *Lancet Oncol* 2020; 21: 1309–1316.

How to cite this article: Alfahadi MN, Malik FA, Almahlawi AS, Alhamdan WA. A rare case of the superior vena cava obstruction in a 16-year-old boy with Burkitt's lymphoma: A case report. *J Taibah Univ Med Sc* 2021;16(3):465–469.