



32.9(±4.7) mm, 16.3(±4.2) mm, and 20.7(±5.9) mm, respectively. For most cadavers, the distal EBSLN had Cernea type 2a-like relationship with the STA. Certain variations were also observed in the way these nerves branched with respect to the origin of the STA.

**Conclusions:** This study provides metric information (linear measurements) regarding the distance between the branches of SLN and certain unique landmarks. This could potentially aid in minimising intraoperative trauma to these branches.

**Keywords:** Anatomy; Cadaver dissection; External Laryngeal Nerve; Internal Laryngeal Nerve; Superior Laryngeal Nerve

© 2021 The Authors.

Production and hosting by Elsevier Ltd on behalf of Taibah University. This is an open access article under the CC BY-NC-ND license (<http://creativecommons.org/licenses/by-nc-nd/4.0/>).

## Introduction

The Superior Laryngeal Nerve (SLN) provides sensory supply to the laryngeal mucosa and motor supply to the cricothyroid muscle through its two branches, namely the Internal (IBSLN) and External (EBSLN).<sup>1</sup> Recognition of the SLN's crucial role in phonation rejuvenated interest among anatomists and surgeons about its anatomy. Subsequently, they elaborated a detailed anatomical course of the SLN, its terminal branches, and their surrounding relationships.<sup>1-5</sup> Since both these branches of SLN are vulnerable to iatrogenic trauma during common surgical procedures like thyroidectomy and anterior cervical spine surgery, surgeons need a three-dimensional anatomical understanding of the same and must adopt adequate measures to prevent intraoperative injury to these nerves.<sup>5-8</sup> Some researchers not only recognised a few landmarks that can be used during surgeries to aid in identifying and preserving these nerves, but also validated their intraoperative reliability.<sup>9-11</sup> Most notably, Cernea et al. (1992) classified the distal course of the EBSLN into three types depending on its relationship with the superior thyroid vessels.<sup>11</sup> The relationship is considered type 1 if the EBSLN crosses the Superior Thyroid Artery (STA) 1 cm above the superior thyroid pole. In types 2a and 2b, this crossing respectively occurs above and below the superior thyroid pole within 1 cm of the same. This classification marked the beginning of a new era in the history of thyroid surgeries by gaining worldwide acceptance as a tool for intraoperative identification and preservation of the EBSLN.<sup>12</sup> Interestingly, both the EBSLN and STA have anatomical variations, and they may suffer distortions caused by large thyroid swellings, decreasing the reliability of these landmarks for intraoperative usage in such scenarios.<sup>13-15</sup> Consequently, a few other researchers extended the Cernea et al. criteria further to improve intraoperative identification and preservation of the EBSLN.<sup>16,17</sup> Recently, Wang et al. (2017) proposed another working classification of the

EBSLN based on the relationship of its lowest point with the superior thyroid pole.<sup>15</sup> However, all these newer classifications related to the EBSLN are also based on soft-tissue landmarks like the STA or Inferior Constrictor muscle.<sup>15-17</sup> Few studies explored similar anatomical relationships with respect to the distal course of the IBSLN.

Generally, bony landmarks like the hyoid bone and thyroid notch are more prominent and robust and not greatly affected by anatomical variations or enlargement of the thyroid gland. The anatomical relationship of these bony landmarks as well as some of the more stable soft-tissue landmarks like the carotid bifurcation and origin of the STA remained unexplored thus far with respect to the course of the EBSLN and IBSLN. This study measured the distance between these unexplored landmarks and entry zones of the EBSLN and IBSLN in a set of human cadavers. Although some previous studies determined the distance between the EBSLN and landmarks like the superior pole of thyroid or sternothyroid muscle, none studied its relationship with bony and soft-tissue landmarks, which we considered in our study. Further, no study analysed such relationships with respect to the IBSLN as well.<sup>13,15,18-20</sup> Our objective is to explore the anatomical relationships (linear measurements) of the EBSLN and IBSLN with these unexplored landmarks. Moreover, since the anatomical relationship of distal SLN and its branches is known for geographical and ethnic atypicality, every new study could potentially contribute to the further understanding of the multi-dimensional anatomical relationship of these structures.<sup>17,21,22</sup>

## Materials and Methods

### *Study design and setting*

This exploratory cadaveric study was conducted collaboratively by the Department of Otolaryngology - Head and Neck Surgery and Department of Anatomy at a tertiary care medical school in Southern India.

### *Study sample and conduct*

This study included cadavers procured through a voluntary body donation program and those regularly utilised for undergraduate teaching. Only adult human cadavers were included without any gender preferences. Ones with severe antemortem trauma to the neck were excluded from the study due to possible disruptions of the cervical anatomy, resulting in misrepresentation of landmarks. Formalin embalmed cadavers were dissected as per Cunningham's manual of dissection.<sup>23</sup> The same standard instruments and digital callipers were used for dissecting and measuring the landmarks in all the cadavers. A midline incision extending from the chin to the sternum was made, which was then extended laterally along the lower margin of the mandible superiorly and the anterior surface of clavicles inferiorly. The skin was reflected inferolaterally, and the platysma was reflected upwards. The superficial nerves and veins were identified and preserved as much as possible and the investing layer of the deep cervical fascia was cleared. The infrahyoid strap muscles were identified and carefully reflected layer by layer. All the deeper structures/

landmarks of interest were delineated through careful dissection to preserve the anatomical orientation. The corresponding relationships were noted/measured separately.

#### Outcome measures

On either side of the neck, four landmarks were delineated – the greater cornua of hyoid bone (distal-most or lateral-most point of the bone), thyroid notch, Carotid bifurcation, and origin of the STA. Courses of the IBSLN and EBSLN were traced from the base of the skull to their respective entry points into the larynx. The former's entry point into the Thyrohyoid membrane and the latter's into the Inferior Constrictor muscle were marked on either side of the neck. Distances between the piercing points of these nerves and the above-mentioned landmarks were studied separately on either side of the cadavers. All distances were measured

once on each side of the cadaver during which the first two authors collectively evaluated the landmarks and marked the measurement points in consensus. During each linear measurement, the reading was noted by placing the callipers at the centre of the desired landmark. The relationship of the distal EBSLN with the superior thyroid vessels and superior thyroid pole was classified as per the description provided by Cernea et al.<sup>11</sup> Apart from the standard measurements mentioned above, any unusual variations in the anatomy were noted separately. Throughout the dissection process, photographic documentation was carried out wherever deemed necessary.

#### Results

Out of the 10 cadavers, 2 were excluded due to the gross anatomical distortion of the neck, and 3 out of the 16 sides of 8 cadavers were excluded from the analysis as the anatomical

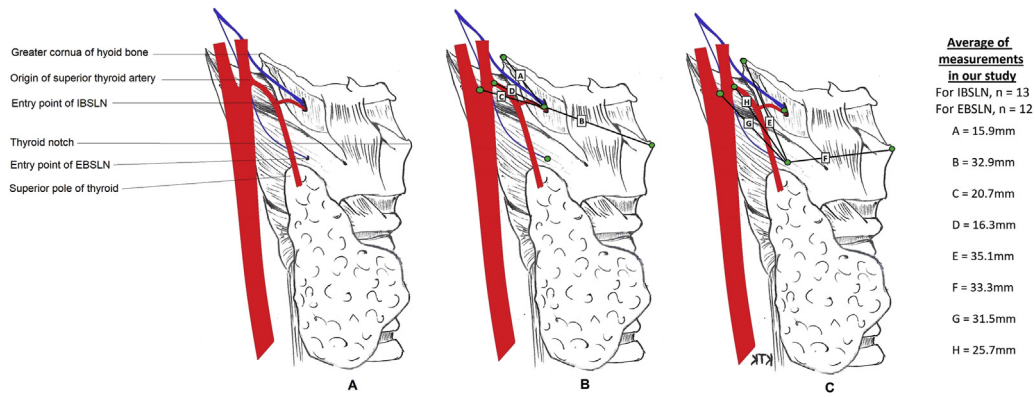
**Table 1: Demographic details of the cadavers included and the metric information related to the branches of superior laryngeal nerve.**

Serial no	Age (in years)	Sex	Side	Division	Cernea's classification type	Superior thyroid artery origin	Carotid bifurcation	Thyroid notch	Hyoid bone greater cornua	Other comments*
1	75	Male	Right	EBSLN	1	30.1	34.2	31.1	42.3	No branching
				IBSLN	–	11.6	14.3	32.7	13.9	3 branches
			Left	EBSLN	1	32.9	38.7	36.1	44.8	No branching
				IBSLN	–	19.3	26.9	28.9	16.7	3 branches
2	65	Male	Right	EBSLN	–	–	–	–	–	Excluded because of gross hematoma in upper neck
				IBSLN	–	–	–	–	–	
			Left	EBSLN	2a	28.9	34.2	31.6	38.1	No branching
				IBSLN	–	10.9	16.1	32.9	7.6	3 branches
3	63	Female	Right	EBSLN	2a	23.2	30.5	31.4	27.5	No branching
				IBSLN	–	14.3	21.6	25.8	13.3	3 branches
			Left	EBSLN	2b	19.7	33.3	28.6	23.5	No branching
				IBSLN	–	20.8	29.6	28.3	11.0	3 branches
4	92	Male	Right	EBSLN	2a	33.2	35.8	38.4	43.1	No branching
				IBSLN	–	20.1	24.9	34.2	27.8	No branching
			Left	EBSLN	2a	33.1	37.1	39.8	38.7	2 branches
				IBSLN	–	23.7	28.1	33.8	22.1	No branching
5	57	Male	Right	EBSLN	–	–	–	–	–	Excluded as the nerve got cut during dissection
				IBSLN	–	10.9	12.1	44.4	13.1	
			Left	EBSLN	2a	20.9	24.8	36.1	28.0	No branching
				IBSLN	–	16.0	20.1	31.3	17.7	3 branches
6	81	Male	Right	EBSLN	2a	24.4	30.0	32.6	32.1	No branching
				IBSLN	–	19.1	21.8	32.9	15.9	4 branches
			Left	EBSLN	2a	29.5	29.6	34.2	39.8	No branching
				IBSLN	–	17.2	24.3	33.2	15.6	5 branches
7	82	Female	Right	EBSLN	–	–	–	–	–	Excluded as landmarks were found disrupted during dissection
				IBSLN	–	–	–	–	–	
			Left	EBSLN	2b	15.9	21.5	33.9	36.2	2 branches
				IBSLN	–	11.5	17.3	38.8	24.2	3 branches
8	78	Female	Right	EBSLN	2a	16.9	28.5	26.8	27.0	No branching
				IBSLN	–	17.0	12.3	30.5	7.8	3 branches
			Left	EBSLN	–	–	–	–	–	Excluded as anatomy got disrupted during dissection
				IBSLN	–	–	–	–	–	

All the measurements are in millimetres.

EBSLN – External branch of superior laryngeal nerve and IBSLN – Internal branch of superior laryngeal nerve.

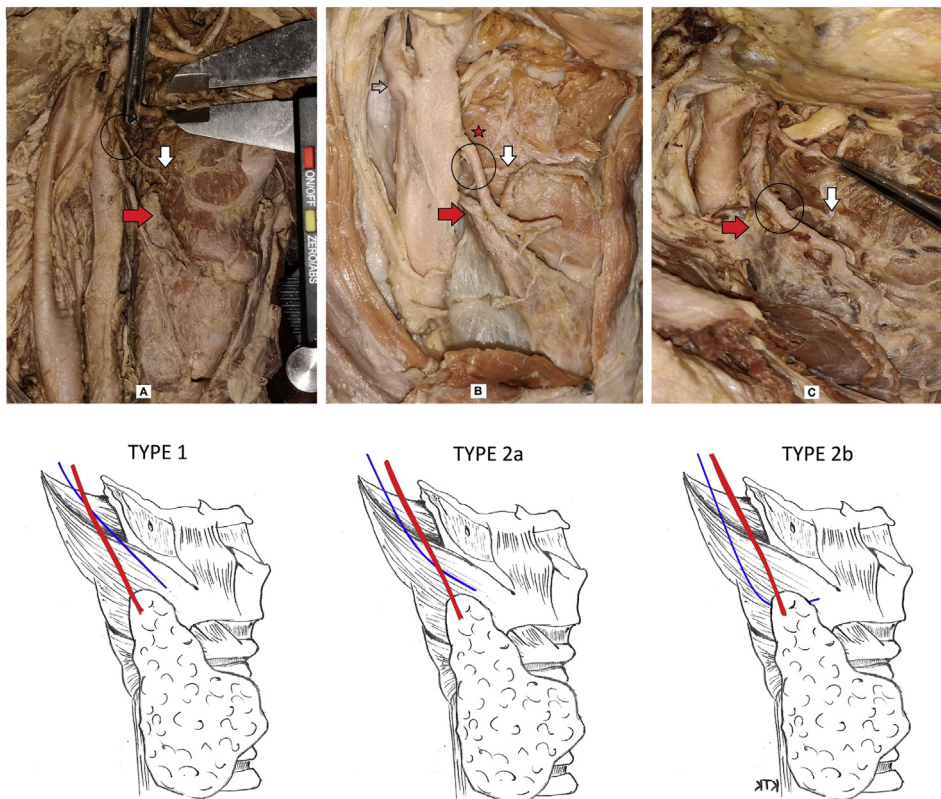
\* Branching of nerves just before their entry into extra laryngeal musculature.



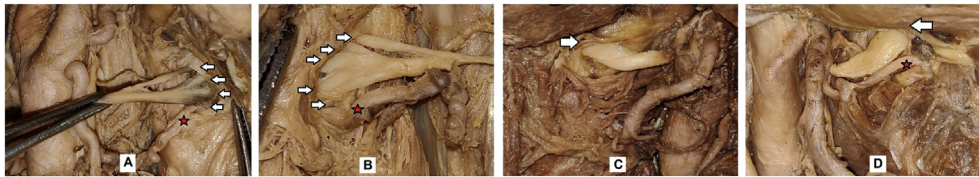
**Figure 1:** Schematic representation of landmarks and the measured distances. A - Showing location of landmarks; B – Distance between IBSLN and greater cornua of hyoid bone (A), Thyroid Cartilage prominence (B), Carotid bifurcation (C) and origin of the STA (D); and C – Distance between EBSLN and greater cornua of hyoid bone (E), Thyroid Cartilage prominence (F), Carotid bifurcation (G) and origin of the STA (H). Abbreviations; IBSLN- Internal Branch and EBSLN – External Branch of Superior Laryngeal Nerve, STA – Superior Thyroid Artery.

landmarks or the nerves themselves were grossly disrupted during dissection in these cases. In another cadaver, the EBSLN was violated during dissection, and hence was excluded from the final analysis. Table 1 shows the demographic details of the included cadavers. The branching of SLN occurred in the skull base or high in the

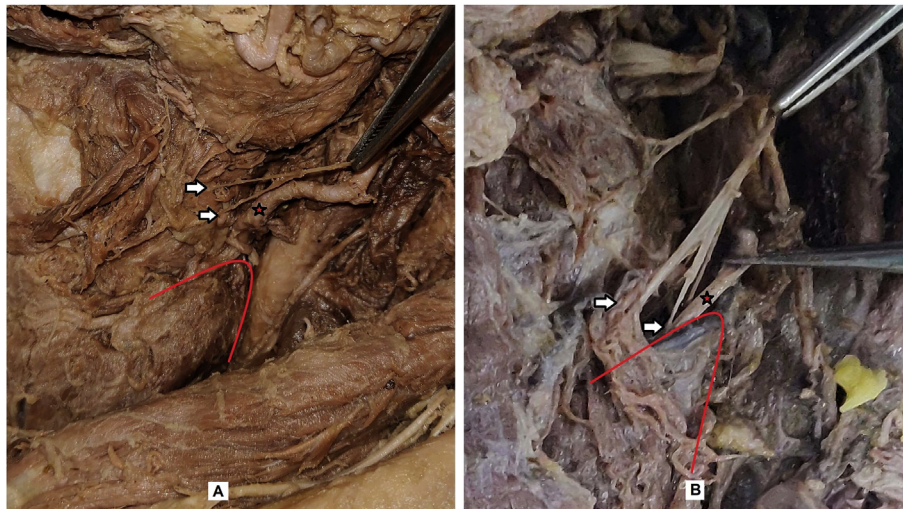
neck in all the dissected cadavers. Both the EBSLN and IBSLN were seen running down as separate divisions below the level of the hyoid bone and were located medial and posterior to the carotid sheath. Table 1 shows the linear distances between the piercing points of these nerves and the delineated landmarks for each of the 13 sides. On



**Figure 2:** Cernea's classification of the relationship between the EBSLN and STA; sub-items A, B, and C representing Cernea types 1, 2a, and 2b, respectively. Illustrations below the dissection pictures depict the corresponding courses of the EBSLN and STA. (white arrow – entry point of EBSLN; red arrow – superior thyroid pole; black circle – crossing of EBSLN and STA; red star – showing origin of STA from common carotid artery; black arrow – level of Carotid bifurcation). Abbreviations; EBSLN – External Branch of Superior Laryngeal Nerve, STA – Superior Thyroid Artery.



**Figure 3:** Variations in the IBSLN branching just before its entry into the Thyrohyoid membrane; sub-items A and B showing multiple branching, and C and D demonstrating the undivided nerve just before entering the thyrohyoid membrane. (white arrows – IBSLN and its branches; red star – superior laryngeal artery paralleling the nerve/its branches before piercing). Abbreviations; IBSLN – Internal Branch of Superior Laryngeal Nerve



**Figure 4:** Branching of the EBSLN seen in two different cadavers represented as sub-items A and B. (white arrows – different entry points of bifurcated EBSLN; red line – corresponds to a margin of superior thyroid pole; red star – STA). Abbreviations; EBSLN – External Branch of Superior Laryngeal Nerve, STA – Superior Thyroid Artery.

an average, the IBSLN's entry into the thyrohyoid membrane was 15.9 mm (standard deviation, SD = 5.9) away from the greater cornua of hyoid bone and 32.9 mm (SD = 4.7) away from the thyroid cartilage prominence (Figure 1). Regarding EBSLN's entry point, the distances were 35.1 mm (SD = 7.2) and 33.3 mm (SD = 3.8) from the greater cornua of hyoid bone and from thyroid cartilage prominence, respectively. Similarly, the average distance between the origin of STA and entry points of the IBSLN and EBSLN was 16.3 mm (SD = 4.2) and 25.7 mm (SD = 6.3), respectively. The average distance from the carotid bifurcation to the entry point of the IBSLN was 20.7 mm (SD = 5.9) and to that of the EBSLN was 31.5 mm (SD = 5.0).

Regarding the relationship of the EBSLN to STA, 58.3% (n = 7) of studied nerves (n = 12) had Cernea type 2a arrangement, followed by type 1 in 25% (n = 3), and type 2b in 16.6% (n = 2). Although we could not measure these nerves' actual diameters in all the cadavers, to naked eye, the IBSLN appeared much thicker (Figure 3) compared to the EBSLN (Figure 2 and 4). Before entering into the Thyrohyoid membrane, the IBSLN branched into three divisions in most cadavers. However, in one of them, this nerve had more than three divisions on both sides (Figure 3A and 3B). Interestingly, in another cadaver, the IBSLN had pierced the membrane undivided on either side

of the neck, mimicking thick muscular tendons (Figure 3C and 3D). The diameter of the nerves was measured separately in this cadaver and were 6 mm on both sides. In two of the cadavers, the EBSLN had an additional thin branch apart from the main nerve (Figure 4), which was confirmed by the histological examination of these branches. These extra branches seemed to part from the main EBSLN below the level of the hyoid bone and posterior to the Carotid artery. They were piercing the inferior constrictor muscle separate from the main nerve. We also noted anatomical variation regarding the origin of the STA. In most cadavers, the STA formed a branch of the external carotid artery but had originated from the common carotid artery in one cadaver (Figure 1B) and from the carotid bifurcation in another (Figure 2A).

## Discussion

Both the IBSLN and EBSLN may suffer injuries in their distal courses during surgical procedures around that region. Identification of the distal segment of the EBSLN during thyroid surgery is no longer just an option but a compulsion to ensure its preservation.<sup>24</sup> Though the latest recommendation is to use an 'intraoperative nerve monitor' for locating and preserving these branches, the manoeuvre

is of little help without in-depth knowledge of its relationships and known anatomical variations.<sup>24–27</sup> After arising from the inferior nodosum of the cranial nerve X at the level of the C2 cervical vertebra, the SLN runs down dorsal to the carotid sheath and bifurcates into two branches at around 1.5 cm from its origin and approximately 2.5 cm cranial to the carotid bifurcation.<sup>1,5,24</sup> The larger IBSLN runs downwards along the internal carotid artery and dorsal to it until it crosses the greater cornua of the hyoid bone. It then turns medially and pierces the thyrohyoid membrane along with the superior laryngeal artery, a branch of the STA.<sup>1,5</sup> The smaller EBSLN further descends dorsal to the carotid sheath and turns medially at the level of the carotid bifurcation to travel downwards and medially, closely hugging the inferior constrictor muscle.<sup>1,24,27</sup> It crosses the STA dorsally at a variable distance from the superior thyroid pole and pierces the Inferior constrictor before innervating the cricothyroid muscle over and above the cricoid cartilage.<sup>1,16,24,27</sup>

Many soft-tissue landmarks, such as the STA, inferior constrictor muscle, cricothyroid muscle, and superior thyroid pole help identify and preserve the EBSLN during surgeries involving the thyroid gland.<sup>3,11,16</sup> The sternothyroid-laryngeal triangle bound by the sternothyroid muscle anteriorly or superiorly, superior thyroid pole laterally, and inferior pharyngeal constrictor and cricothyroid muscles medially is used intraoperatively for locating the EBSLN.<sup>3</sup> The Cernea et al. classification also uses the same soft-tissue landmarks to stratify the risk of injury to EBSLN in thyroid surgeries. However, many surgeons find it challenging to identify this nerve, especially in cases of enlargement of the thyroid gland, because these soft-tissue landmarks are likely to be covered or distorted by the enlargement.<sup>12,16,25,27,28</sup> In other words, though the existing soft-tissue landmarks enable better identification of the EBSLN in cadaveric studies, their practical intraoperative utility is not infallible. This is supported by the fact that the reported identification rates of the EBSLN using these landmarks are much less in clinical studies compared to cadaveric ones.<sup>21</sup>

As a preliminary step towards exploring stable landmarks for easy identification and preservation of the EBSLN and IBSLN, we identified a few additional and probably more robust landmarks, and measured their distance from entry points of the EBSLN and IBSLN. Some of these landmarks have never been explored, and a few have been studied sparsely in previous studies.<sup>5,19,20,22,29</sup> Nevertheless, the landmarks included in our study are likely to remain unhindered by the thyroid gland's size and weight, and thus, they can potentially serve as stable landmarks for identifying the EBSLN and IBSLN intraoperatively. Relatively unoccupied midline landmarks like the thyroid cartilage prominence might actually enable a safer anterior approach to the cricothyroid, EBSLN, and STA during thyroidectomy.<sup>20,22</sup> As for the classification of Cernea et al., most of our specimens had 2a type of arrangement. However, the sample size in our study may not be sufficient to analyse the prevalence of Cernea classification with certainty because a shift of one or two samples from type 1 to type 2a would yield contradicting results.

Interestingly, though many previous studies reported similar outcomes to ours with respect to Cernea's classification, some others have identified type 1 arrangement to be more frequent than type 2.<sup>16,17,20–22,28,30,31</sup> This disparity is not surprising as the relationship of the distal EBSLN and STA depends on many factors, including the race, ethnicity, and neck length of an individual. This relationship also varies quite often as per the size and weight of the thyroid gland itself.<sup>12,16,22,27,28</sup>

We encountered a few more interesting but atypical anatomical characteristics in our study cadavers. Generally, the IBSLN branches into two or three divisions just before or after piercing the Thyrohyoid membrane.<sup>4,5,29</sup> We had more than three divisions of the IBSLN on both sides of the neck in one cadaver and an undivided thick IBSLN outside the Thyrohyoid membrane bilaterally in another cadaver. Regarding the EBSLN, we identified the nerve's bifurcation before entering the inferior constrictor muscle in two cadavers. In fact, existing literature suggests that such division of the EBSLN is more common than expected.<sup>20,22,24,32</sup> This variation is surgically significant during thyroidectomy. Thyroid surgeons should be careful to preserve all the extra tissues that surround the STA and superior thyroid pole rather than being too complacent after identifying the EBSLN, as this nerve may have additional branches. Lastly, in our study, two cadavers showed anomalous origin of the STA. The literature review indicates that the origin of the STA is vastly variable. It arises from the external carotid artery in 40%–88% specimens, from the carotid bifurcation in 8%–32%, and directly from the common carotid artery in 1.5%–35%.<sup>31,33–35</sup> Although rare, the STA can sometimes originate even from the lingual artery.<sup>31</sup> Thyroid surgeons should be aware of such variations, which would prove useful if the STA is not found in its usual location, especially in case of unusually large goitres. Further, since the origin of the STA varies, the distance between the point of its origin and the SLN branches' entry points may not be as reliable as we hypothesised in the beginning of this study. As for the limitations of the study, the sample size was inadequate for evaluating intragroup variations of the measured distances. However, we calculated the SD to measure this variability in the population. The other probable drawback of the study is the absence of three-dimensional measurements. Nevertheless, the linear measurements reported in this study must be interpreted by considering the known anatomical orientation between these structures, as this gross anatomical organisation is unlikely to differ.

## Conclusion

Our study explored some of the previously unconsidered landmarks that could potentially aid in identifying the EBSLN during surgeries in cases of enlarged thyroid gland, which otherwise may distort the conventional soft-tissue landmarks. Unlike most of the previous studies that have explored either of the EBSLN and IBSLN, we studied the linear relationships of both these nerves with the newer landmarks.

## Recommendations

Our study provides basic linear measurements between some of the previously unexplored landmarks and the entry points of the IBSLN and EBSLN. It provides reference measurements for surgeons and researchers about the more robust landmarks that could potentially offer better intra-operative utility. In addition to validating our results, subsequent studies may also consider assessing the three-dimensional geometrical relationships between these structures.

## Source of funding

This research did not receive any specific grant from funding agencies in the public, commercial or not-for-profit sectors.

## Conflict of interest

The authors have no conflict of interest to declare.

## Ethical approval

This study was approved by the Institutional Ethics committee of Kasturba Medical college and Kasturba Hospitals with reference number IEC:782/2019, dated 9 October 2019.

## Authors contributions

KD was involved in the conception and design of the work, the acquisition, analysis, interpretation of data, and writing the initial and final drafts of the article. RP conceived and designed the study, conducted research, provided research materials, collected and organized data, and wrote the initial draft of article. SGK was involved in drafting the work, revising it critically for important intellectual content, and approval of the final version. KP was involved in drafting the work and revising it critically for important intellectual content. All authors critically reviewed and approved the final draft and are responsible for the content and similarity index of the manuscript.

## Acknowledgment

Authors would like to thank Dr Tulasi Kota Karanth, a post-graduate student of the Department of Otorhinolaryngology, for providing the basic artwork for this study, which was subsequently used for creating the illustrations.

## References

1. Monfared A, Kim D, Jaikumar S, Gorti G, Kam A. Microsurgical anatomy of the superior and recurrent laryngeal nerves. *Neurosurgery* 2001; 49: 925–932. discussion 932-933.
2. Gregg RL. Avoiding injury to the extralaryngeal nerves. *Ann Otol Rhinol Laryngol* 1957; 66: 656–678.
3. Moosman DA, DeWeese MS. The external laryngeal nerve as related to thyroidectomy. *Surg Gynecol Obstet* 1968; 127: 1011–1016.
4. Paraskevas GK, Raikos A, Ioannidis O, Brand-Saberi B. Topographic anatomy of the internal laryngeal nerve: surgical considerations. *Head Neck* 2012; 34: 534–540.
5. Kiray A, Naderi S, Ergur I, Korman E. Surgical anatomy of the internal branch of the superior laryngeal nerve. *Eur Spine J* 2006; 15: 1320–1325.
6. Folk D, Wahba B, Sasaki CT. Is the external branch of the superior laryngeal nerve dispensable in thyroid surgery? *Thyroid* 2016; 26: 169–173.
7. Guraya SY, Eltinay OF, Alzobydi AH. Total thyroidectomy for bilateral benign thyroid disease: safety profile and therapeutic efficacy. *Kuwait Med J* 2007; 39: 149–152.
8. Yang S, Zhou L, Lu Z, Ma B, Ji Q, Wang Y. Systematic review with meta-analysis of intraoperative neuromonitoring during thyroidectomy. *Int J Surg Lond Engl* 2017; 39: 104–113.
9. Lennquist S, Cahlin C, Smeds S. The superior laryngeal nerve in thyroid surgery. *Surgery* 1987; 102: 999–1008.
10. Cernea CR, Ferraz AR, Furlani J, Monteiro S, Nishio S, Hojaij FC, et al. Identification of the external branch of the superior laryngeal nerve during thyroidectomy. *Am J Surg* 1992; 164: 634–639.
11. Cernea CR, Ferraz AR, Nishio S, Dutra A, Hojaij FC, dos Santos LR. Surgical anatomy of the external branch of the superior laryngeal nerve. *Head Neck* 1992; 14: 380–383.
12. Dionigi G, Kim HY, Randolph GW, Wu C-W, Sun H, Liu X, et al. Prospective validation study of Cernea classification for predicting EMG alterations of the external branch of the superior laryngeal nerve. *Surg Today* 2016; 46: 785–791.
13. Naidoo D, Boon JM, Mieny CJ, Becker PJ, Schoor A-N van. Relation of the external branch of the superior laryngeal nerve to the superior pole of the thyroid gland: an anatomical study. *Clin Anat* 2007; 20: 516–520.
14. Ravikumar K, Sadacharan D, Muthukumar S, Mohanpriya G, Hussain Z, Suresh RV. EBSLN and factors influencing its identification and its safety in patients undergoing total thyroidectomy: a study of 456 cases. *World J Surg* 2016; 40: 545–550.
15. Wang K, Cai H, Kong D, Cui Q, Zhang D, Wu G. The identification, preservation and classification of the external branch of the superior laryngeal nerve in thyroidectomy. *World J Surg* 2017; 41: 2521–2529.
16. Friedman M, LoSavio P, Ibrahim H. Superior laryngeal nerve identification and preservation in thyroidectomy. *Arch Otolaryngol Head Neck Surg* 2002; 128: 296–303.
17. Kierner AC, Aigner M, Burian M. The external branch of the superior laryngeal nerve: its topographical anatomy as related to surgery of the neck. *Arch Otolaryngol Head Neck Surg* 1998; 124: 301–303.
18. Ng S-K, Li H-N, Chan JY-K, Wong EWY, Vlantis AC. A useful landmark to locate the external branch of the superior laryngeal nerve during thyroidectomy. *Gland Surg* 2020; 9: 647–652.
19. Ortega C, Marañillo E, McHanwell S, Sañudo J, Vázquez-Osorio T. External laryngeal nerve landmarks revisited. *Head Neck* 2018; 40: 1926–1933.
20. Cha YH, Moon S-Y, Jehoon O, Tansatit T, Yang H-M. Anatomy of the external branch of the superior laryngeal nerve in Asian population. *Sci Rep* 2017; 14952.
21. Cheruiyot I, Kipkorir V, Henry BM, Munguti J, Ciocchi R, Odula P, et al. Surgical anatomy of the external branch of the superior laryngeal nerve: a systematic review and meta-analysis. *Langenbeck's Arch Surg* 2018; 403: 811–823.

22. Whitfield P, Morton RP, Al-Ali S. Surgical anatomy of the external branch of the superior laryngeal nerve. *ANZ J Surg* **2010**; 80: 813–816.
23. Romanes GJ. *Cunningham's manual of practical anatomy*. 15<sup>th</sup> ed., vol. 3. Oxford University Press; 1986.
24. Barczyński M, Randolph GW, Cernea CR, Dralle H, Dionigi G, Alesina PF, et al. External branch of the superior laryngeal nerve monitoring during thyroid and parathyroid surgery: international Neural Monitoring Study Group standards guideline statement. *Laryngoscope* **2013**; 123: S1–S14.
25. Uludag M, Aygun N, Kartal K, Cıtgez B, Besler E, Yetkin G, et al. Contribution of intraoperative neural monitoring to preservation of the external branch of the superior laryngeal nerve: a randomized prospective clinical trial. *Langenbeck's Arch Surg* **2017**; 402: 965–976.
26. Gurleyik E, Dogan S, Cetin F, Gurleyik G. Visual and electrophysiological identification of the external branch of superior laryngeal nerve in redo thyroid surgery compared with primary thyroid surgery. *Ann Surg Treat Res* **2019**; 96: 269–274.
27. Potenza AS, Araujo Filho VJF, Cernea CR. Injury of the external branch of the superior laryngeal nerve in thyroid surgery. *Gland Surg* **2017**; 6: 552–562.
28. Menon RR, Murali S, Nair CG, Babu MJC, Jacob P. Correlation between the Cernea classification of external branch of superior laryngeal nerve in relation to the ultrasound-based volume of thyroid gland. *Indian J Endocrinol Metab* **2017**; 21: 845–847.
29. Stephens RE, Wendel KH, Addington WR. Anatomy of the internal branch of the superior laryngeal nerve. *Clin Anat N Y N* **1999**; 12: 79–83.
30. Gavid M, Dubois MD, Larivé E, Prades JM. Superior laryngeal nerve in thyroid surgery: anatomical identification and monitoring. *Eur Arch Oto-Rhino-Laryngol* **2017**; 274: 3519–3526.
31. Dessie MA. Variations of the origin of superior thyroid artery and its relationship with the external branch of superior laryngeal nerve. *PLoS One* **2018**; 13:e0197075.
32. Maranillo E, León X, Quer M, Orús C, Sañudo JR. Is the external laryngeal nerve an exclusively motor nerve? The cricothyroid connection branch. *Laryngoscope* **2003**; 113: 525–529.
33. Sreedharan R, Krishna L, Shetty A. Origin of superior thyroid artery: under the surgeon's knife. *J Vasc Bras* **2018**; 17: 290–295.
34. Esen K, Ozgur A, Balci Y, Tok S, Kara E. Variations in the origins of the thyroid arteries on CT angiography. *Jpn J Radiol* **2018**; 36: 96–102.
35. Joshi A, Gupta S, Vaniya VH. Anatomical variation in the origin of superior thyroid artery and its relation with external laryngeal nerve. *Natl J Med Res* **2014**; 4: 138–141.

**How to cite this article:** Devaraja K, Punja R, Kalthur SG, Pujary K. Unmapped landmarks around branches of the Superior Laryngeal Nerve: An exploratory cadaveric study. *J Taibah Univ Med Sc* 2021;16(3):328–335.