

4-28-2023

Protective Effect of Betulinic Acid Administration on Kidney Damage in Acetaminophen-Induced Nephrotoxicity Model

Eda Dokumacioglu

Department of Nutrition and Dietetics, Faculty of Healthy Sciences, Artvin Coruh University, Artvin 08000, Turkey, edadokumacioglu@yahoo.com

Hatice İskender

Department of Nutrition and Dietetics, Faculty of Healthy Sciences, Artvin Coruh University, Artvin 08000, Turkey, haticeiskender2011@hotmail.com

Armagan Hayirli

Department of Animal Nutrition and Nutritional Disorders, Faculty of Veterinary Medicine, Ataturk University, Erzurum 25420, Turkey, ahayirli_2000@yahoo.com

Guler Yenice

Department of Animal Nutrition and Nutritional Disorders, Faculty of Veterinary Medicine, Ataturk University, Erzurum 25420, Turkey, gulerata2003@hotmail.com

Kubra Asena Terim Kapakin

Department of Pathology, Faculty of Veterinary Medicine, Ataturk University, Erzurum 25420, Turkey, kubra.terim@atauni.edu.tr

See next page for additional authors

Follow this and additional works at: <https://scholarhub.ui.ac.id/mjhr>



Part of the [Alternative and Complementary Medicine Commons](#), [Chemicals and Drugs Commons](#), and the [Disease Modeling Commons](#)

Recommended Citation

Dokumacioglu E, Iskender H, Hayirli A, Yenice G, Kapakin KAT, Bolat I, et al. Protective Effect of Betulinic Acid Administration on Kidney Damage in Acetaminophen-Induced Nephrotoxicity Model. Makara J Health Res. 2023;27.

Protective Effect of Betulinic Acid Administration on Kidney Damage in Acetaminophen-Induced Nephrotoxicity Model

Authors

Eda Dokumacioglu, Hatice Iskender, Armagan Hayirli, Guler Yenice, Kubra Asena Terim Kapakin, Ismail Bolat, and Esra Manavoglu Kirman

Protective Effect of Betulinic Acid Administration on Kidney Damage in Acetaminophen-Induced Nephrotoxicity Model

Eda Dokumacioglu^{1*}, Hatice Iskender¹, Armagan Hayirli², Guler Yenice²,
Kubra Asena Terim Kapakin³, Ismail Bolat³, Esra Manavoglu Kirman³

¹Department of Nutrition and Dietetics, Faculty of Healthy Sciences, Artvin Coruh University, Artvin 08000, Turkey

²Department of Animal Nutrition and Nutritional Disorders, Faculty of Veterinary Medicine, Ataturk University, Erzurum 25420, Turkey

³Department of Pathology, Faculty of Veterinary Medicine, Ataturk University, Erzurum 25420, Turkey

Abstract

Background: Acetaminophen (APAP) is the most widely used analgesic drug worldwide, but it may induce renal toxicity. Betulinic acid (BA) ameliorates the oxidative stress and inflammatory response to renal damage. The present study aimed to investigate the potential protective effects of BA treatment through an experimental kidney damage rat model administered with APAP.

Methods: Sprague–Dawley male rats were randomly divided into four groups: control, BA (25 mg/kg for 15 days), APAP (1 g/kg), and APAP + BA groups. BA was administered via oral gavage at a dose of 25 mg/kg for 15 days. APAP was dissolved in hot saline and administered on the last day to produce nephrotoxicity via a single oral gavage at a dose of 1 g/kg. Kidney tissue samples were analyzed for human cartilage glycoprotein 39 (YKL-40), kidney injury molecule 1 (KIM-1), interleukin 18 (IL-18), superoxide dismutase (SOD), and malondialdehyde (MDA). Data were subjected to one-way analysis of variance and the Wilcoxon rank-sum test

Results: Renal tissue YKL-40, KIM-1, IL-18, and MDA levels in the APAP group were significantly higher than those in the control group ($p < 0.05$). The BA treatment completely restored renal KIM-1, YKL-40, and MDA levels and partially restored renal IL-18 and SOD levels in the rats subjected to renal damage induction ($p < 0.05$). The intertubular regions of rats administered with APAP had degeneration, necrosis, and infiltration of inflammatory cells and were immunopositive for IL-1 beta and 8-hydroxy-2'-deoxyguanosine.

Conclusions: BA can be used in the prevention and replacement treatment of nephrotoxicity due to its inhibitory properties in multiple pathways and powerful antioxidant effects.

Keywords: acetaminophen, betulinic acid, interleukin 18, kidney injury molecule 1, malondialdehyde, superoxide dismutase

INTRODUCTION

Acetaminophen (APAP) is one of the most widely used analgesic drug worldwide despite its capability to induce renal toxicity at overdose. Metabolites from APAP–glutathione and APAP–cysteine conjugates have been implicated in renal toxicity.¹ APAP transforms into the harmful *p*-aminophenol metabolite, which is a nephrotoxin in the kidney that initiates tissue damages, specifically tubular and cortical necrosis.² In addition to APAP-induced oxidative stress and renal damages,³ the activation of inflammatory and oxidative mediators contributes to nephrotoxicity.⁴

The principal response to kidney injury is the development of inflammation and oxidative stress, which can lead to renal fibrosis. Biomarkers associated with renal inflammation and repair may be helpful in distinguishing patients at risk of kidney damage from

those who are likely to recover.⁵ Biomarkers are frequently examined to diversify risk prediction, in addition to the usual clinical variables, and to explore potential pathological mechanisms that may be targets for future intervention. Human cartilage glycoprotein 39 (YKL-40), a member of “mammalian chitinase-like proteins,” is secreted by macrophages, neutrophils, chondrocytes, endothelial cells, vascular smooth muscle cells, and cancer cells and also known as chitinase-3-like protein 1. It is a novel biomarker for acute and chronic inflammation. A high serum YKL-40 concentration indicates poor prognosis in a wide range of diseases and clinical conditions.^{6,7}

The kidney can effectively recover from an ischemic or toxic insult that results in cell death as the tubular epithelium can proliferate and replace lost cells. The balance between injury and repair is the key determinant of the fate of the injured kidney. Potent factors induced by injury facilitate adaptive repair.⁸ Kidney injury molecule 1 (KIM-1), a transmembrane glycoprotein, is upregulated more than any other protein in the proximal tubule of the kidney with various forms of injury. KIM-1 is a phosphatidylserine receptor that mediates phagocytosis of apoptotic bodies and oxidized lipids. The chronic

*Corresponding author:

Eda Dokumacioglu
Department of Nutrition and Dietetics, Faculty of Healthy Sciences,
Artvin Coruh University, Artvin, Turkey
E-mail: edadokumacioglu@yahoo.com

expression of KIM-1 results in progressive kidney fibrosis and chronic kidney failure, which are possibly related to its phagocytic function to take up noxious compounds, such as oxidized lipids.^{9,10}

The role of inflammation in nephrotoxicity has been increasingly appreciated with the involvement of leukocytes, adhesion molecules, chemokines, and cytokines. Interleukins (ILs) are important mediators of the immune reaction in the innate immune system response and adaptive immunity. IL-18 is a proinflammatory cytokine involved in the pathogenesis of acute kidney damage.^{11,12}

Betulinic acid (BA) is mainly isolated from plant sources, such as birch, eucalyptus, and plane trees.¹³ Its potent physiological and pharmacological activities are related to anti-diabetic, antitumor, anti-inflammatory, and antibacterial effects. BA can help protect cells against oxidative damage by reducing the oxidative stress caused by free radicals. These antioxidant effects can potentially mitigate the negative effects associated with aging, inflammation, and certain diseases. BA exerts a strong anti-inflammatory effect by inhibiting inflammation. BA can also reduce the excessive response of the immune system and regulate the production of inflammatory cytokines.^{14,15} The present study was conducted to determine whether BA has protective effects on experimentally induced kidney damage using a rat model administered with APAP.

METHODS

Animals and experimental design

Ethics committee approval of the study was obtained from Atatürk University Local Ethics Committee for Animal Experiments. Male Sprague–Dawley rats (N = 32, 200–250 g, and 6–8 weeks old) from the Experimental Animal Laboratory of Atatürk University were housed in special rooms with an ambient temperature of 22°C ± 2°C and humidity of 50%–60% under a photoperiod of 12:12 h light:dark conditions. The animals were given tap water and standard diet *ad libitum*. The rats were randomly divided into four groups (n = 8 per group): (1) control, (2) BA, (3) APAP, and (4) APAP + BA groups. BA (Sigma Chemical Co., St. Louis, MO) was administered via oral gavage at a dose of 25 mg/kg for 15 days.¹⁶ APAP (Sigma Chemical Co., St. Louis, MO) was dissolved in hot saline and administered on the last day to induce nephrotoxicity via a single oral gavage at a dose of 1 g/kg.¹⁷ APAP was administered 24 h after the last BA treatment.

After APAP injection for 24 h, the rats intraperitoneally administered with ketamine (80 mg/kg; Ketalar®, 50 mg/ml, Eczacıbasi, Istanbul, Turkey) and xylazine (10 mg/kg; Rompun®, 2%, Bayer, Istanbul, Turkey) were sacrificed, and blood and kidney tissues were harvested for analyses. Blood samples were centrifuged at 3000 rpm

for 15 min to separate the sera. Serum samples were analyzed for blood urea nitrogen (BUN), creatinine, alanine amino transferase (ALT), and alkaline phosphatase (ALP). Kidney tissues were stored in a –80°C freezer for the analyses of KIM-1, YKL-40, IL-18, superoxide dismutase (SOD), and malondialdehyde (MDA).

Biochemical examination

Serum BUN, creatinine, ALT, and ALP were analyzed using an autoanalyzer (RX Monaco; Randox Laboratories Ltd., County Antrim, UK). The method of Sun *et al.*¹⁸ was used to determine the SOD activity (U/mg protein) in kidney tissue samples; the method is based on the utilization of the xanthine oxidase system as a superoxide generator and inhibition of nitroblue tetrazolium reduction. Renal MDA levels (nmol/mg protein) were determined by the method of Esterbauer and Cheeseman¹⁹ based on the measurement of the absorbance of the pink complex that formed in the presence of thiobarbituric acid at a wavelength of 532 nm.

Renal KIM-1, YKL-40, and IL-18 levels (pg/mg) were measured by enzyme-linked immunoassay (ELISA; ELK Biotechnology Co., Ltd, Wuhan East Lake Hi-Tech Development Zone, Hubei, China), in accordance with the manufacturer's instructions. In the ELISA method, an antigen immobilized on a solid surface was complexed with an antibody linked to an enzyme. Detection is accomplished by assessing the conjugated enzyme activity via incubation with a substrate to produce a measurable product at 450 nm.

Histopathological examination

The kidney tissue samples were fixed in 10% buffered formalin and routinely processed for histological examination by embedding in paraffin wax. The tissue sections were cut at 4 µm thickness and stained by hematoxylin–eosin (H&E) for observation under a light microscope (Olympus Bx51 with a DP72 camera system, Olympus Corp., Tokyo, Japan).²⁰

Each specimen was examined in 10 randomly selected areas of an X40 objective. The scores for hyperemia, degeneration, necrosis, and inflammatory cells were derived semi-quantitatively using light microscopy on the preparations from each rat and reported as follows: Grade 0 = –(negative); Grade 1 = +1 (mild); Grade 2 = +2 (moderate); Grade 3 = +3 (severe); Grade 4 = +4 (most severe).²¹

Immunohistochemical examination

All the tissue samples were cut into 4 µm sections and processed for immunohistochemical examination by a standard avidin–biotin–peroxidase method described by the manufacturer. Rabbit polyclonal antibodies that react with rat IL-1β antibody (Catalog No. ab9722, Santa Cruz Biotechnology, Dallas, US) and 8-hydroxy-2'-deoxyguanosine

(8-OHdG) (sc-66036, Santa Cruz Biotechnology, Dallas, US) at the dilution of 1:200 were used for 60 min. A secondary antibody was used following the manufacturer's protocol (exposed mouse and rabbit-specific HRP/DAB detection IHC Kit, Abcam Cat. No. ab80436; Abcam, Cambridge, UK). After three washes with 0.1% Tween 20 in phosphate-buffered saline, the sections were incubated with 3,3'-diaminobenzidine (Dako Cytomation, Santa Clara, CA) and counterstained with Mayer's hematoxylin (Dako Cytomation).

Statistical analysis

The data were analyzed using a commercial software (Statistical Analysis of the System (SAS), Version 9.0, SAS Institute Inc., Cary, NC). Biochemical parameters (continuous data) were subjected to one-way analysis of variance

using the GLM procedure. The group mean differences were elucidated by the least-significant difference option. Histopathological and immunohistochemical parameters (discrete data) were subjected to the Wilcoxon rank-sum test using the NPAR1WAY Procedure (SAS). Values at $p \leq 0.05$ were considered significant.

RESULTS

Kidney injury markers

The APAP administration group caused 4.1-, 2.7-, 3.3-, and 2.5-fold increases in concentrations of BUN, creatinine, ALT, and ALP, respectively, compared with the control group ($p < 0.05$, Table 1). Except for that of ALP, the BA treatment reduced BUN, creatinine, and ALT concentrations in the APAP group to the levels of the control group.

TABLE 1. Effect of BA treatment on serum biochemistry profile of rats exposed to APAP-induced nephrotoxicity*

Groups ²	Parameters ¹			
	BUN (mg/dL)	Creatinin (mg/dL)	ALT (U/L)	ALP (U/L)
Control	14.7 ± 1.1 ^b	0.80 ± 0.08 ^b	34 ± 3.0 ^b	65 ± 5.0 ^c
APAP	60.7 ± 7.6 ^a	2.13 ± 0.39 ^a	111 ± 13.0 ^a	165 ± 12.0 ^a
BA	15.1 ± 1.0 ^b	1.07 ± 0.10 ^b	33 ± 3.0 ^b	64 ± 6.0 ^c
APAP+BA	25.3 ± 2.3 ^b	1.13 ± 0.14 ^b	39 ± 3.0 ^b	101 ± 5.0 ^b

*Data are the least square means ± standard error (SE). Different superscripts within columns differ ($p < 0.05$).

¹BUN = blood urea nitrogen; ALT = alanine aminotransferase; ALP = alkaline phosphatase.

²BA was administered via oral gavage at a dose of 25 mg/kg for 15 days (Nader and Baraka 2012). The APAP, after its dissolution in hot saline, was administered on the last day to produce nephrotoxicity via a single oral gavage at a dose of 1 g/kg (Dokumacioglu *et al.* 2017).

TABLE 2. Effect of BA treatment on renal KIM-1, YKL-40, IL-18, SOD, and MDA levels in rats exposed to APAP-induced nephrotoxicity*

Groups ²	Parameters ¹				
	KIM-1 pg/mg	YKL-40 ng/mg	IL-18 pg/mg	SOD U/mg protein	MDA nmol/mg protein
Control	348 ± 41.0 ^b	27.9 ± 3.2 ^b	221 ± 31.0 ^c	250 ± 47.0 ^a	24.6 ± 2.5 ^b
APAP	755 ± 63.0 ^a	63.4 ± 8.5 ^a	724 ± 47.0 ^a	90 ± 14.0 ^c	49.3 ± 4.3 ^a
BA	354 ± 24.0 ^b	28.7 ± 2.5 ^b	174 ± 23.0 ^c	216 ± 18.0 ^{ab}	22.1 ± 1.8 ^b
APAP+BA	383 ± 28.0 ^b	30.9 ± 5.1 ^b	399 ± 3.08 ^b	147 ± 13.0 ^{bc}	26.8 ± 2.4 ^b

*Data are the least square means ± SE. Different superscripts within columns differ ($p < 0.05$).

¹KIM-1 = kidney injury molecule; YKL-40 = glycoprotein 39 or chitinase-3-like protein; IL-18 = interleukin 18; SOD = superoxide dismutase; MDA = malondialdehyde.

²BA was administered via oral gavage at a dose of 25 mg/kg for 15 days (Nader and Baraka 2012). APAP, after its dissolution in hot saline, was administered on the last day to produce nephrotoxicity via a single oral gavage at a dose of 1 g/kg (Dokumacioglu *et al.* 2017).

TABLE 3. Effect of BA treatment on the histopathology and immunohistochemistry of renal tissues from rats exposed to APAP-induced nephrotoxicity*

Groups ²	Parameters ¹					
	Hyperemia	Degeneration	Necrosis	Inflam. cells	IL1β	8-OHdG
Control	0 (0–1) ^c	0 (0–1) ^c	0 (0–0) ^c	0 (0–0) ^c	0 (0–0) ^c	0 (0–1) ^c
APAP	2 (2–3) ^a	2 (2–3) ^a	2 (1–2) ^a	2 (1–2) ^a	2.5 (2–3) ^a	3 (2–3) ^a
BA	0 (0–1) ^c	1 (0–1) ^c	0 (0–0) ^c	0 (0–0) ^c	0 (0–0) ^c	0.5 (0–1) ^c
APAP+BA	1 (0–2) ^b	1.5 (1–2) ^b	0.5 (0–1) ^b	1 (0–1) ^b	1 (1–1) ^b	1.5 (1–2) ^b

*Data are the median score (minimum–maximum). Different superscripts within columns differ ($p < 0.05$).

¹IL1β = interleukin 1 beta; 8-OHdG = 8-hydroxy-2'-deoxyguanosine.

²BA was administered via oral gavage at a dose of 25 mg/kg for 15 days (Nader and Baraka 2012). APAP, after its dissolution in hot saline, was administered on the last day to produce nephrotoxicity via a single oral gavage at a dose of 1 g/kg (Dokumacioglu *et al.* 2017).

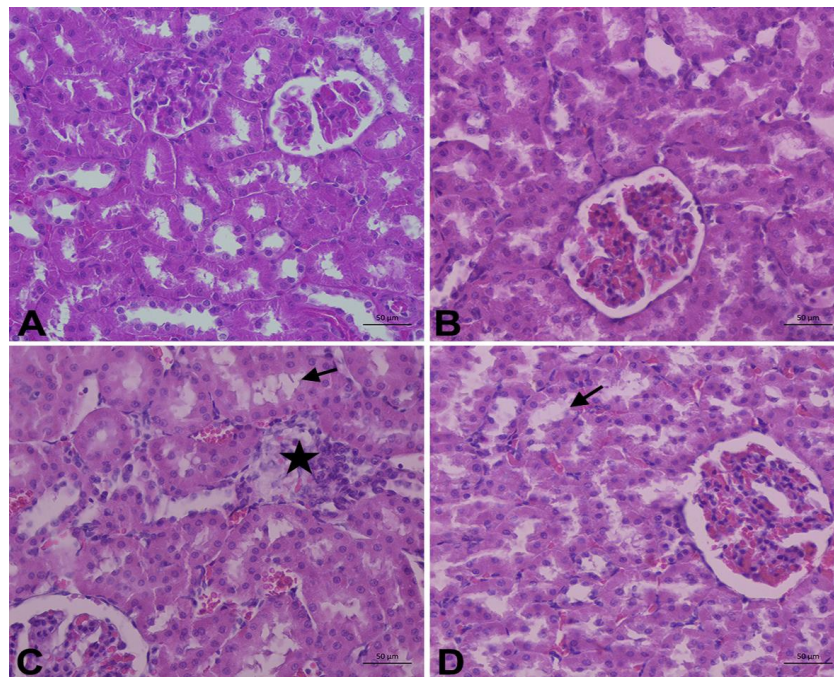


FIGURE 1. Effect of BA treatment on the histopathology of renal tissue in rats exposed to APAP-induced nephrotoxicity. HxE, Bar: 50 µm. A–B) No histopathological lesions in the healthy rats not given BA (control) and given BA (BA group). C) Inflammatory cell infiltration, degeneration, and necrosis in the epithelial cells of proximal tubules in rats with APAP-induced nephrotoxicity (APAP group). The star on the figures indicates inflammatory cell infiltration, and the black arrow shows degeneration and necrosis. D) Moderate histopathological changes were observed in rats with APAP-induced nephrotoxicity and treated with BA (Group APAP + BA).

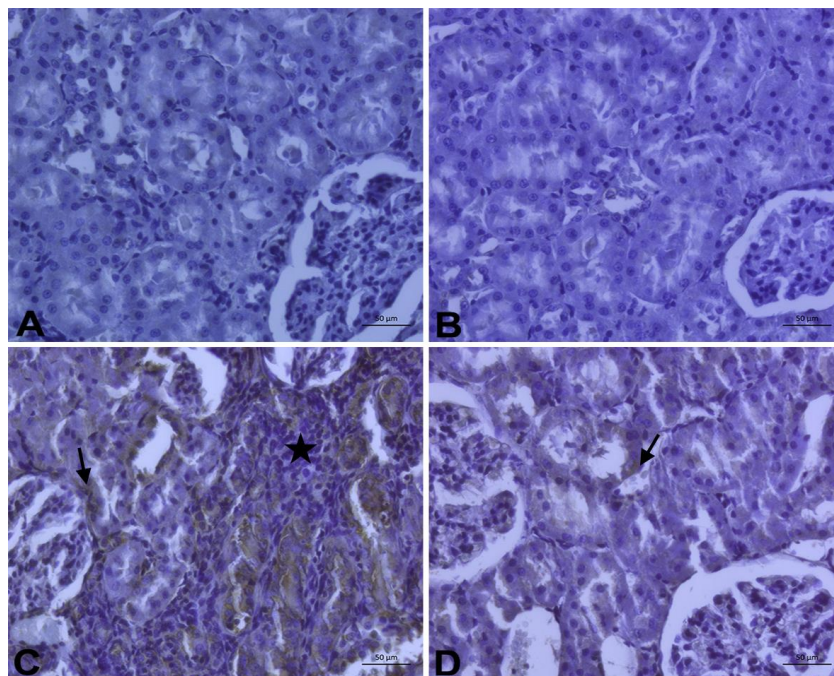


FIGURE 2. Effect of BA treatment on the immunohistochemistry of IL-1 β expression in rats exposed to APAP-induced nephrotoxicity. Immunopositive stained epithelial cells, mesengial cells, and endothelial cells of blood vessels. The star on the figures indicates inflammatory cell infiltration, and the black arrow shows degeneration and necrosis. Bar: 50 µm.

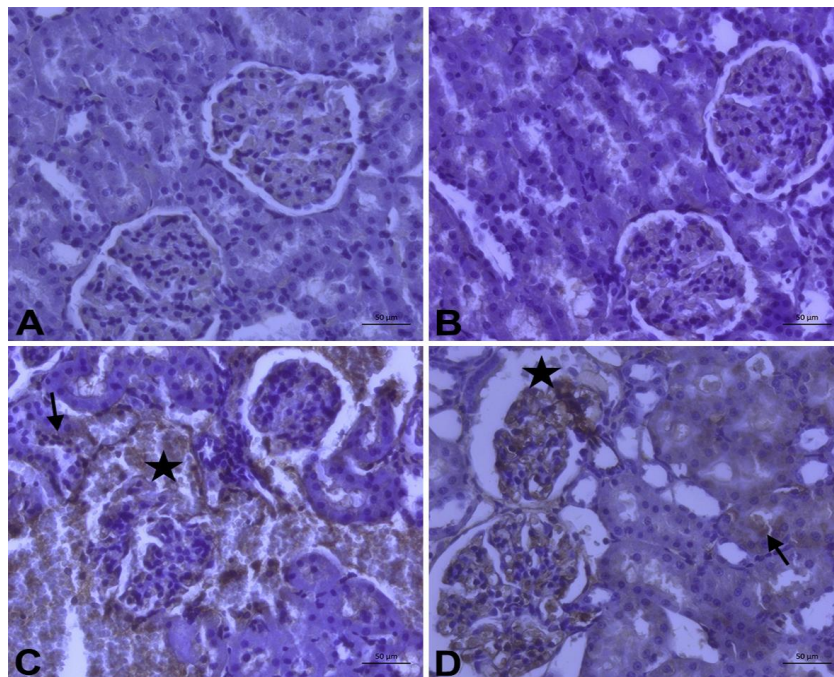


FIGURE 3. Effect of BA treatment on the immunohistochemistry of 8-OHdG expressed in rats exposed to APAP-induced nephrotoxicity. Immunopositive stained epithelial cells, mesangial cells, and endothelial cells of blood vessels. The star on the figures indicates inflammatory cell infiltration, and the black arrow shows degeneration and necrosis. Bar: 50 μm .

Compared with the control group, the APAP administration increased renal KIM-1, YKL-40, IL-18, and MDA levels by 117%, 127%, 228%, and 100%, respectively ($p < 0.05$, Table 2) and decreased renal the SOD level by 64% ($p < 0.05$, Table 2). The BA treatment completely restored renal KIM-1, YKL-40, and MDA levels and partially restored renal IL-18 and SOD levels in the rats subjected to renal damage induction.

Tissue analysis

Nephrotoxicity induction by APAP administration was successful, as reflected by the dramatic increases in the scores for hyperemia, degeneration, necrosis, and infiltration of inflammatory cells (macrophages and lymphocytes) in the intertubular region (Table 3; Figures 1A, 1B, and 1C). BA treatment was partially effective in ameliorating these histopathological parameters (Table 3; Figure 1D).

Biomarker expression

Responses to immunopositivity for IL-1 β (Table 3; Figure 2) and 8-OHdG (Table 3; Figure 3) among the experimental groups were similar to the histopathological findings. APAP administration resulted in immunopositivity for IL-1 β and 8-OHdG of the kidney tubular epithelial cells, mesangial cells, and endothelial cells of blood vessels, which were partially alleviated by the BA treatment (Table 3; Figures 2 and 3).

DISCUSSION

APAP is one of the nonsteroidal anti-inflammatory drugs and has a widespread clinical use. When it is used at high

doses, however, APAP can cause acute toxicity in organs involved in its metabolism and elimination, particularly in the liver and kidneys.²² Kidneys are dynamic organs having important roles in maintaining body homeostasis, water, and acid–base and electrolyte balance. Some biochemical and physiological properties of the kidney make it more susceptible to ischemic and toxic damage compared with other organs.²³ This experiment questioned whether BA treatment alleviates APAP-induced nephrotoxicity using biochemical and histopathological markers pertinent to kidney damage.

Many studies indicated elevated BUN and creatinine levels as the evidence of renal dysfunction.²⁴ Naguib *et al.*²⁵ and Das *et al.*²⁶ reported increases in BUN and creatinine levels upon the hepatorenal damage induction by paracetamol. In agreement with previous studies, APAP-induced nephrotoxicity was associated with elevations in BUN, creatinine, ALT, and ALP concentrations. APAP is a nephrotoxin and can induce nephrotoxicity at a single dose of its administration.^{27,28} In APAP intoxication, increased levels of N-acetyl-p-benzoquinoneimine lead to increased formation of superoxide radicals (O_2^-) and hydrogen peroxide (H_2O_2).²⁹ Kidney damage induced by nephrotoxins may result in chronic renal failure, nephrotic syndrome, tubular dysfunction, and acute renal failure due to triggering by oxidative stress.^{23,30} MDA, an important indicator of oxidative stress, is formed by the peroxidation of polyunsaturated fatty acids. Lipid peroxidation is the chemical reaction initiated by free radicals and involves the oxidation of polyunsaturated fatty acids on the membrane structure. Reactive

aldehydes, including MDA, cause cross-linking and polymerization in membrane components, which eventually leads to alterations in membrane functions, involving deterioration in membrane structure, ion transport, and enzyme activity.³¹ SOD is an endogenous antioxidant enzyme protecting the cells responsible for oxygen metabolism from the adverse effects of superoxide radicals. In the literature, SOD activity was shown to decrease in acute kidney injuries.^{32,33} Double MDA concentration and decreased SOD concentration in the APAP group can be attributed to the lipid peroxidation reaction and decreased antioxidant protection system success of renal damage. BA has been suggested to exhibit antioxidant properties, thus attenuating the development of oxidative stress in experimental animal models. BA has antioxidant effects, which can protect kidney cells from oxidative damage caused by free radicals. Oxidative stress contributes to kidney damage. Thus, the antioxidant properties of BA may support kidney health. BA can help protect cells against oxidative damage by reducing MDA levels and inducing SOD activity. These effects can potentially mitigate the negative effects associated with kidney damage.^{34,35}

Severe inflammatory response also occurs in kidney damage resulting from oxidative stress.³⁶ The study by Ucar *et al.*³⁷, in which kidney damage was induced by APAP administration, revealed increases in the levels of inflammatory cytokines. Inflammation underlies the pathogenesis of many acute or chronic kidney diseases, and IL-18 is a useful marker for the diagnosis of diseases and prediction of their severity and prognosis.³⁸ In agreement with the study of Shen *et al.*³⁹, a dramatic increase in IL-18 concentration was observed in rats exposed to kidney damage upon APAP administration.

KIM-1 is found at very low levels in the proximal tubules of the normal kidney. However, its level increases in damaged epithelium.^{40,41} It is one of the proteins most induced in the kidneys following acute kidney injury^{42,43} and considered a prominent biomarker.⁴⁴ The KIM-1 response upon APAP administration is similar to those reported by Kim *et al.*⁴⁵ and Coban *et al.*²⁸ We observed the positive effects of BA on KIM-1 in our study. No research investigated the relationship between BA and KIM-1. However, some studies suggested that BA may have a protective effect on kidneys by reducing oxidative stress⁴⁶ and inflammation⁴⁷, which can lead to decreased KIM-1 levels. KIM-1 is a biomarker used to detect early signs of kidney injury, and its reduction may indicate improved kidney function. Further research is needed to fully understand the potential relationship between BA and KIM-1.

YKL-40, identified as a new inflammatory marker, plays an important role in inflammation, angiogenesis, extracellular matrix remodeling, and fibrosis development.^{48,49} Puthumana *et al.*⁵⁰ reported that YKL-40 levels increased

to limit kidney damage and support adaptive repair mechanisms. The YKL-40 level became more than doubled in the APAP group, which was accompanied by increased cytokine levels because inflammatory cytokines stimulate the synthesis.^{51,52} YKL-40 is a marker of inflammation and tissue remodeling and associated with various pathological conditions, including kidney diseases. However, no current evidence suggests that BA has a direct effect on YKL-40 levels or activity. In our study, we observed the positive effects of BA on YKL-40. We believe that the positive effect of BA on YKL-40 levels resulted from its capability to halt the inflammatory process. Decreased inflammation may have led to a decrease in YKL-40 levels. Further research is needed to explore any potential relationship between BA and YKL-40 in kidney disease or other conditions.

The APAP-induced renal damage was evident, as reflected by histopathological findings, such as degeneration in kidney tissues and necrosis and hyperemia in epithelial cells. Moreover, immunohistochemical findings revealed the increased expressions of IL-1 β and 8-OHdG. Inflammation and oxidative stress play important roles in the pathophysiology of many kidney diseases and their complications.⁵³ Acute kidney injury, as a result of long-term use of APAP, is one of the most common conditions. Natural ingredients with high antioxidant potency may help protect renal tissues from the APAP-induced nephrotoxicity.

BA may have various positive effects on kidneys. Some studies suggest that BA can help the kidneys function in a healthy way by protecting kidney cells from oxidative stress and inflammation.^{46,54} In addition, BA is being investigated as a potential treatment option for some kidney diseases, such as kidney inflammations and kidney stones. Khataylou⁵⁴ showed that BA markedly decreased the production of proinflammatory cytokines.

BA supplementation provides nephron-protective effects through ameliorating oxidative stress and inflammatory response.⁵⁵ Lingaraju *et al.*⁵⁵ reported that BA administration increased renal antioxidant activity by suppressing inflammatory cytokines. BA reduced oxidative stress and inflammation in renal tissue. An experimental study examining the effects of BA on renal fibrosis reported that BA prevents fibrosis by inhibiting nuclear factor- κ B activation.⁵⁶ The BA treatment completely and partially ameliorated the serum parameters. These positive effects on metabolic profile were accompanied by an enhanced antioxidant status. The beneficial effects of BA treatment were also notable in histopathological and immunohistochemical evaluations.

CONCLUSIONS

Acute APAP exposure generated inflammation and oxidative stress in tissues, as reflected by the increases in

specific (KIM-1, YKL-40, and IL-18) and general (SOD and MDA) biomarkers involved in the pathophysiology of nephrotoxicity. Overall, BA treatment was partially effective in ameliorating renal damage. Studies investigating the effect of BA on kidney injury are limited. Our study is one of the few research investigating the effect of BA on kidney injury, which makes the topic innovative and interesting. Our study can contribute new information to the literature regarding the effect of BA on kidney injury. This can provide an important scientific contribution for researchers and healthcare professionals. The study results suggested that BA ameliorated the oxidative stress and inflammatory response of APAP-induced renal damage by reducing the KIM-1/YKL-40/IL-18 signaling pathway. Future research should consider different treatment dosages and durations of BA treatment for kidney injury.

CONFLICT OF INTEREST

The authors declare that they have no known competing financial interests nor personal relationships that could have appeared to influence the work reported in this paper.

FUNDING

This work was supported by Coordinator of Scientific Research Projects [2021.M84.02.02] at Artvin Coruh University.

Received: December 25, 2022 | Accepted: March 15, 2023

REFERENCES

1. Brune K, Renner B, Tieggs G. Acetaminophen/paracetamol: A history of errors, failures and false decisions. *Eur J Pain*. 2015;19:953–65.
2. Salama M, Elgamal M, Abdelaziz A, Ellithy M, Magdy D, Ali L, *et al.* Toll-like receptor 4 blocker as potential therapy for acetaminophen-induced organ failure in mice. *Exp Ther Med*. 2015;10(1):241–6.
3. Ghosh J, Das J, Manna P, Sil PC. Acetaminophen induced renal injury via oxidative stress and TNF- α production: therapeutic potential of arjunolic acid. *Toxicology*. 2010;268:8–18.
4. Alshahrani S, Ashafaq M, Hussain S, Mohammed M, Sultan M, Jali AM, *et al.* Renoprotective effects of cinnamon oil against APAP-Induced nephrotoxicity by ameliorating oxidative stress, apoptosis and inflammation in rats. *Saudi Pharm J*. 2021;29:194–200.
5. Puthumana J, Thiessen-Philbrook H, Xu L, Coca SG, Garg AX, Himmelfarb J, *et al.* Biomarkers of inflammation and repair in kidney disease progression. *J Clin Invest*. 2021;131:e139927.
6. Persson F, Borg R. YKL-40 in dialysis patients: Another candidate in the quest for useful biomarkers in nephrology. *Kidney Int*. 2018;93:2–22.
7. Keskin GS, Helvacı Ö, Yayla Ç, Paşaoğlu Ö, Keskin Ç, Arınsoy T, *et al.* Relationship between plasma YKL-40 levels and endothelial dysfunction in chronic kidney disease. *Turkish J Med Sci*. 2019;49:139–46.
8. Yang L, Brooks CR, Xiao S, Sabbiseti V, Yeung MY, Hsiao LL, *et al.* KIM-1-mediated phagocytosis reduces acute injury to the kidney. *J Clin Invest*. 2015;125:1620–36.
9. Ichimura T, Hung CC, Yang SA, Stevens JL, Bonventre JV. Kidney injury molecule-1: A tissue and urinary biomarker for nephrotoxicant-induced renal injury. *Am J Physiol Renal Physiol*. 2004;286:F552–63.
10. Bonventre JV. Kidney injury molecule-1(KIM-1): A specific and sensitive biomarker of kidney injury. *Scand J Clin Lab Invest Suppl*. 2008;241:78–83.
11. Hegazy R, Salama A, Mansour D, Hassan A. Renoprotective Effect of Lactoferrin against chromium-induced acute kidney injury in rats: Involvement of IL-18 and IGF-1 Inhibition. *PLoS One*. 2016;11:e0151486.
12. Griffin BR, Faubel S, Edelstein CL. Biomarkers of drug-induced kidney toxicity. *Ther Drug Monit*. 2019;41:213–26.
13. Lou H, Li H, Zhang S, Lu H, Chen Q. A Review on preparation of betulinic acid and its biological activities. *Molecules*. 2021;26:5583.
14. Jiang W, Li X, Dong S, Zhou W. Betulinic acid in the treatment of tumour diseases: Application and research progress. *Biomed Pharmacother*. 2021;142:111990.
15. Ríos JL, Máñez S. New pharmacological opportunities for betulinic acid. *Planta Med*. 2018;84:8–19.
16. Nader MA, Baraka HN. Effect of betulinic acid on neutrophil recruitment and inflammatory mediator expression in lipopolysaccharide-induced lung inflammation in rats. *Eur J Pharm Sci*. 2012;46:106–13.
17. Dokumacıoğlu E, Iskender H, Terim Kapakin KA, Yenice G, Mokthare B, Bolat İ, *et al.* Effect of betulinic acid administration on TLR-9/NF- κ B /IL-18 levels in experimental liver injury. *Turk J Med Sci*. 2021;51:1544–53.
18. Sun Y, Oberley LW, Li Y. A simple method for clinical assay of superoxide dismutase. *Clin Chem*. 1988;34:497–500.
19. Esterbauer H, Cheeseman KH. Determination of aldehydic lipid peroxidation products: Malonaldehyde and 4-hydroxynonenal. *Method Enzymol*. 1990;186:407–21.
20. Terim-Kapakin KA, Gumus R, Imik H, Kapakin S, Sağlam YS. Effects of ascorbic and α -lipoic acid on secretion of HSP-70 and apoptosis in liver and kidneys of broilers exposed to heat stress. *Ankara Univ Vet J*. 2012;59:279–87.
21. Apaydin Yildirim B, Kordali S, Terim Kapakin KA, Yildirim F, Aktas Senocak E, Altun S. Effect of Helichrysum plicatum DC. subsp. plicatum ethanol extract on gentamicin-induced nephrotoxicity in rats. *J Zhejiang Univ Sci B*. 2017;18:501–11.
22. Seok PR, Kim JH, Kwon HR, Heo JS, Choi JR, Shin JH. Protective effects of Gastrodia elata Blume on acetaminophen-induced liver and kidney toxicity in rats. *Food Sci Biotechnol*. 2018;27:1445–54.

23. Parlakpınar H, Örum MH, Acet A. Free oxygen radicals in drug-induced nephrotoxicity. *Firat Univ Med J Health Sci.* 2013;27:51–6.
24. Oğutmen MB. Acute renal failure. *CVT Anaesth Inten Care Soc.* 2011;17:25–33.
25. Naguib YM, Azmy RM, Samaka RM, Salem MF. Pleurotus ostreatus opposes mitochondrial dysfunction and oxidative stress in acetaminophen-induced hepatorenal injury. *BMC Complem Altern Med.* 2014;14:494.
26. Das J, Ghosh J, Manna P, Sil PC. Taurine protects acetaminophen-induced oxidative damage in mice kidney through APAP urinary excretion and CYP2E1 inactivation. *Toxicology.* 2010;269:24–34.
27. Hiragi S, Yamada H, Tsukamoto T, Yoshida K, Kondo N, Matsubara T, et al. Acetaminophen administration and the risk of acute kidney injury: A self-controlled case series study. *Clin Epidemiol.* 2018;10:265–76.
28. Coban FK, Ince S, Demirel HH, Islam I, Aytug H. Acetaminophen-induced nephrotoxicity: Suppression of apoptosis and endoplasmic reticulum stress using boric acid. *Biol Trace Elem Res.* 2023;201:242–9.
29. Kamaş N, Karabag CF. Investigation of caffeic acid phenethyl ester effect on inflammation and oxidative stress in paracetamol induced hepatotoxicity. *Atatürk Uni Vet J.* 2019;14:290–8.
30. Jaeschke H, McGill MR, Williams CD, Ramachandran A. Current issues with acetaminophen hepatotoxicity—A clinically relevant model to test the efficacy of natural products. *Life Sci.* 2011;88:737–45.
31. Aydin S, Atukeren P, Cakatay U, Uzun H, Altuğ T. Gender-dependent oxidative variations in liver of aged rats. *Biogerontology.* 2010;11:335–46.
32. Costa NA, Gut AL, Azevedo PS, Tanni SE, Cunha NB, Magalhães ES, et al. Erythrocyte superoxide dismutase as a biomarker of septic acute kidney injury. *Ann Intens Care.* 2016;6:95–102.
33. Mortensen J, Shames B, Johnson CP, Nilakantan V. MnTMPyP, a superoxide dismutase/catalase mimetic, decreases inflammatory indices in ischemic acute kidney injury. *Inflamm Res.* 2011;60:299–307.
34. Zhou XR, Bai YY, Qian LB. Betulinic acid attenuates lipopolysaccharide-induced vascular hyporeactivity in the rat aorta by modulating Nrf2 antioxidant function. *Clin J Biochem Mol Biol.* 2018;34:455.
35. Adeleke GE, Adaramoye OA. Betulinic acid abates N-nitrosodimethylamine-induced changes in lipid metabolism, oxidative stress, and inflammation in the liver and kidney of Wistar rats. *J Biochem Mol Toxicol.* 2021;35:e22901.
36. El-Sayed EM, Abd-Allah AR, Mansour AM, El-Arabey AA. Thymol and carvacrol prevent cisplatin-induced nephrotoxicity by abrogation of oxidative stress, inflammation, and apoptosis in rats. *J Biochem Mol Toxicol.* 2015;29:165–72.
37. Ucar F, Taslipinar MY, Alp BF, Aydin I, Aydin FN, Agilli M, et al. The effects of N-acetylcysteine and ozone therapy on oxidative stress and inflammation in acetaminophen-induced nephrotoxicity model. *Ren Fail.* 2013;35:640–7.
38. Hirooka Y, Nozaki Y. Interleukin-18 in inflammatory kidney disease. *Front Med (Lausanne).* 2021;8:639103.
39. Shen Y, Jin X, Chen W, Gao C, Bian Q, Fan J, et al. Interleukin-22 ameliorated acetaminophen-induced kidney injury by inhibiting mitochondrial dysfunction and inflammatory responses. *Appl Microbiol Biotechnol.* 2020;104:5889–98.
40. Vaidya VS, Waikar SS, Ferguson MA, Collings FB, Sunderland K, Gioules C, et al. Urinary biomarkers for sensitive and specific detection of acute kidney injury in humans. *Clin Transl Sci.* 2008;1:200–8.
41. Bonventre JV. Kidney injury molecule-1 (KIM-1): A urinary biomarker and much more. *Nephrol Dial Transplant.* 2009;24:3265–8.
42. Han WK, Bailly V, Abichandani R, Thadhani R, Bonventre JV. Kidney injury molecule-1 (KIM-1): A novel biomarker for human renal proximal tubule injury. *Kidney Int.* 2002;62:237–44.
43. Vaidya VS, Ozer JS, Dieterle F, Collings FB, Ramirez V, Troth S, et al. Kidney injury molecule-1 outperforms traditional biomarkers of kidney injury in preclinical biomarker qualification studies. *Nat Biotechnol.* 2010;28:478–85.
44. Edelstein CL, Faubel S. Biomarkers in acute kidney injury. In: Edelstein CL. Ed. *Biomarkers of kidney disease*, Academic Press, 2011, p. 177–232.
45. Kim BW, Kim BW, Kim HJ, Kim SH, Baik HJ, Kang MS, et al. 15-Hydroxyprostaglandin dehydrogenase inhibitor prevents contrast-induced acute kidney injury. *Ren Fail.* 2021;43:168–79.
46. Li X, Wang X, Liu S, Wang J, Liu X, Zhu Y, et al. Betulinic acid attenuates T-2 toxin-induced cytotoxicity in porcine kidney cells by blocking oxidative stress and endoplasmic reticulum stress. *Comp Biochem Physiol C Toxicol Pharmacol.* 2021;249:109124.
47. Huang L, Zhu L, Ou Z, Ma C, Kong L, Huang Y, et al. Betulinic acid protects against renal damage by attenuation of oxidative stress and inflammation via Nrf2 signaling pathway in T-2 toxin-induced mice. *Int Immunopharmacol.* 2021;101:108210.
48. Bilim O, Takeishi Y, Kitahara T, Ishino M, Sasaki T, Suzuki S, et al. Serum YKL-40 predicts adverse clinical outcomes in patients with chronic heart failure. *J Card Fail.* 2010;16:873–9.
49. Okyay GU, Er RE, Tebudak MY, Paşaoğlu Ö, Inal S, Öneç K, et al. Novel inflammatory marker in dialysis patients: YKL-40. *Ther Apher Dial.* 2013;17:193–201.
50. Puthumana J, Hall IE, Reese PP, Schröppel B, Weng FL, Thiessen-Philbrook H, et al. YKL-40 associates with renal recovery in deceased donor kidney transplantation. *J Am Soc Nephrol.* 2017;28:661–70.
51. Recklies AD, White C, Ling H. The chitinase 3-like protein human cartilage glycoprotein 39 (hcgp39) stimulates proliferation of human connective-tissue cells and activates both extracellular signal regulated kinase and protein kinase B-mediated signalling pathways. *Biochem J.* 2002;365:119–26.
52. Recklies AD, Ling H, White C, Bernier SM. Inflammatory cytokines induce production of CHI3L1 by articular chondrocytes. *J Biol Chem.* 2005;280:41213–21.
53. Ozbek E. Induction of oxidative stress in kidney. *Int J Nephrol.* 2012;2012:465897.

54. Jafari Khataylou Y, Ahmadi Afshar S, Mirzakhani N. Betulinic acid reduces the complications of autoimmune diabetes on the body and kidney through effecting on inflammatory cytokines in C57BL/6 mice. *Vet Res Forum*. 2021;12:203–10.
55. Lingaraju MC, Pathak NN, Begum J, Balaganur V, Ramachandra HD, Bhat RA, *et al*. Betulinic acid attenuates renal oxidative stress and inflammation in experimental model of murine polymicrobial sepsis. *Eur J Pharm Sci*. 2015;70:12–21.
56. Wang S, Yang Z, Xiong F, Chen C, Chao X, Huang J, *et al*. Betulinic acid ameliorates experimental diabetic-induced renal inflammation and fibrosis via inhibiting the activation of NF- κ B signaling pathway. *Mol Cell Endocrinol*. 2016;434:135–43.