

# Diagnostic value and clinical significance of high-resolution ultrasonography compared to magnetic resonance imaging in diagnosing temporomandibular joint dislocation: a systematic review

Thariqah Salamah, Glancius Nironsta Harefa



pISSN: 0853-1773 • eISSN: 2252-8083  
<https://doi.org/10.13181/mji.oa.247184>  
**Med J Indones.** 2024;33:29–34

**Received:** September 30, 2023  
**Accepted:** February 13, 2024  
**Published online:** March 25, 2024

**Authors' affiliations:**  
 Department of Radiology, Faculty of  
 Medicine, Universitas Indonesia, Cipto  
 Mangunkusumo Hospital, Jakarta,  
 Indonesia

**Corresponding author:**  
 Glancius Nironsta Harefa  
 Department of Radiology, Faculty of  
 Medicine, Universitas Indonesia, Cipto  
 Mangunkusumo Hospital, Jalan Pangeran  
 Diponegoro No. 71, Central Jakarta  
 10430, DKI Jakarta, Indonesia  
 Tel/Fax: +62-21-3106705  
 E-mail: glancius13@gmail.com

## ABSTRACT

**BACKGROUND** Temporomandibular joint (TMJ) dislocation is uncommon, yet it is associated with a significant negative effect on the patient's quality of life. Magnetic resonance imaging (MRI), a gold standard for diagnosing TMJ dislocation, is expensive, time-consuming, and cannot be performed on patients with pacemakers and metallic prostheses. On the other hand, high-resolution ultrasonography (HRUS) has low cost, high accessibility, and is less time-consuming. This study aimed to compare the accuracy and reliability of HRUS to MRI in diagnosing TMJ dislocation.

**METHODS** A comprehensive literature search was conducted using PubMed, Cochrane Library, ScienceDirect, and EBSCOhost databases. Keywords such as temporomandibular joint dislocation, temporomandibular displacement, MRI, and ultrasonography were utilized for the search. The articles obtained were then selected based on the inclusion and exclusion criteria, and the quality assessment was conducted using the QUADAS-2 tool.

**RESULTS** 5 studies were included in this systematic review. The critical appraisal results showed sensitivity ranging from 74.3–93.7%, specificity from 84.2–100%, positive predictive value from 68.2–100%, negative predictive value from 64.0–98.3%, and accuracy from 77.7–91.7% of HRUS compared to MRI.

**CONCLUSIONS** HRUS is a reliable method for diagnosing TMJ dislocation. However, MRI is still necessary in selected and more advanced cases.

**KEYWORDS** magnetic resonance imaging, temporomandibular joint, ultrasonography

The temporomandibular joint (TMJ) is a part of the craniofacial complex and consists of bilateral synovial articulations. It mainly consists of the articular fossa, articular eminence, articular disc, and mandibular condyle, which are essential in speech and mastication.<sup>1</sup> TMJ dislocation is a musculoskeletal dysfunction involving the TMJ and masticatory muscles. It is an uncommon event, with a lifetime prevalence of 5–8% and an incidence of up to 25 per 100,000 people per year.<sup>2</sup> Clinical manifestations of TMJ dislocation include restricted movement of the

mandibular joint, facial pain, and noise during jaw movement, resulting in a decreased quality of life.<sup>3</sup>

Precise and prompt diagnosis is key to appropriate treatment, and medical imaging plays a significant role in diagnosing TMJ dislocation.<sup>4</sup> Magnetic resonance imaging (MRI), a noninvasive and ionizing radiation-free diagnostic tool, is considered the gold standard for diagnosing TMJ dislocation because of its excellent ability to differentiate soft tissue images. However, despite its superiority, MRI has several limitations, including its time-consuming nature, high cost, limited

availability in hospital facilities, and restrictions on patients with pacemakers, metallic prostheses, or claustrophobia.<sup>4,5,6</sup>

As an alternative, ultrasonography (USG), particularly high-resolution ultrasonography (HRUS), has emerged as a promising diagnostic method for TMJ dislocation in recent years. HRUS is inexpensive, provides quick examinations with real-time results, and is widely available in most hospital facilities. Recent studies have shown outstanding results in diagnosing TMJ disorders using HRUS.<sup>7-10</sup> This study aimed to compare the accuracy and reliability of HRUS to MRI in diagnosing TMJ dislocation.

## METHODS

### Search strategy

A systematic literature search was conducted using electronic databases, including PubMed, Cochrane Library, ScienceDirect, and EBSCOhost. Keywords such as temporomandibular joint dislocation, temporomandibular joint displacement, MRI, and ultrasonography were used in the search. MeSH keywords were also included in the literature search (Table 1). Limitations were applied to the literature search, which included articles published within the last decade (2010–2022). The reference lists of the included articles were screened to identify relevant studies. This study adhered to the guidelines outlined in the Preferred Reporting Items for Systematic Reviews and Meta-Analyses checklist.

### Study selection and data collection

The inclusion criteria were as follows: (1) study population of patients suspected of having TMJ

dislocation, (2) diagnosis using both MRI and HRUS, and (3) data on the sensitivity and specificity of MRI and HRUS. Case reports, reviews, conference abstracts, non-English articles, and animal studies were excluded. Articles were selected based on the inclusion and exclusion criteria. Data extracted from all studies included the characteristics of participants (age and sex), sample size, study design, gold standard diagnostic tool, types of USG, final study conclusion (outcome), and study limitations.

### Quality assessment

Both authors independently assessed the study quality using the Quality Assessment of Diagnostic Accuracy Studies-2 tool. It consisted of patient selection, index tests, reference standards, patient flow throughout the study, and the timing of the index tests and reference standards. Each domain was evaluated for the risk of bias and applicability.

## RESULTS

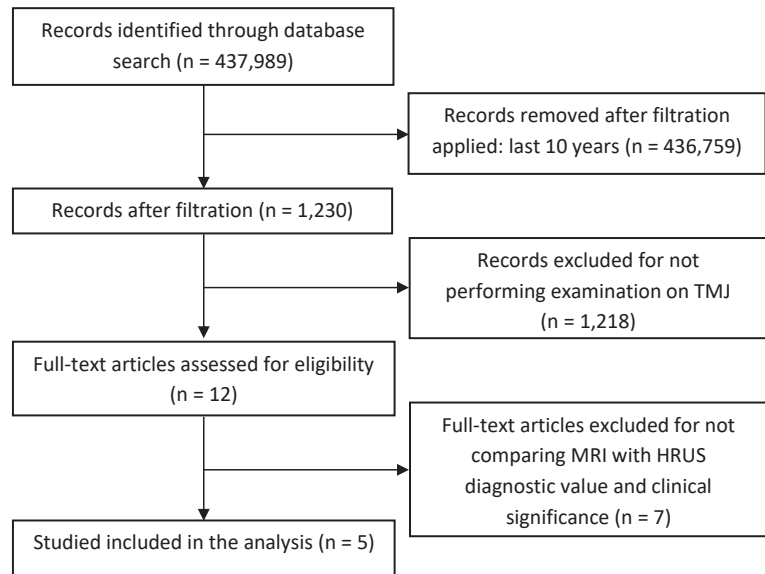
Of the 437,989 prospectively relevant articles included in the initial search, 436,759 were excluded, leaving 1,230 articles remaining. After an initial review of the titles and abstracts, a full-text analysis was conducted on 12 articles. Ultimately, five studies were selected for qualitative synthesis and critical appraisal (Figure 1).

### Characteristics of the studies

All articles used MRI as the reference standard for diagnosing TMJ disorders and compared it to HRUS. HRUS (5–17 MHz) with a linear array transducer was employed in all studies. Talmaceanu et al<sup>11</sup> conducted two types of sonographic evaluations using an 8–40

**Table 1.** Search strategy

Databases	Search strategy	Hits	Selected
PubMed	((((((((temporomandibular joint dislocation [Title/Abstract])) OR (temporomandibular joint dislocation [MeSH Terms])) OR (temporomandibular joint displacement [Title/Abstract])) OR (temporomandibular joint displacement [MeSH Terms])) AND (temporomandibular [Title/Abstract])) AND ((((((mri[Title/Abstract])) OR (magnetic resonance imaging[Title/Abstract])) OR (ultrasonography[Title/Abstract])) OR (usg[Title/Abstract]))	774	3
ScienceDirect	("temporomandibular joint dislocation" OR "temporomandibular joint displacement") AND ("magnetic resonance imaging" OR "mri" OR "ultrasonography" OR "usg")	177	2
Cochrane Library	(temporomandibular joint dislocation):ti,ab,kw OR (temporomandibular joint displacement):ti,ab,kw OR (temporomandibular joint dislocation):ti,ab,kw (Word variations have been searched) AND (magnetic resonance imaging):ti,ab,kw OR (mri):ti,ab,kw (ultrasonography):ti,ab,kw OR (usg):ti,ab,kw	142	0
EBSCOhost	("temporomandibular joint dislocation" OR "temporomandibular joint displacement") AND ("magnetic resonance imaging" OR "mri" OR "ultrasonography" OR "usg")	137	0

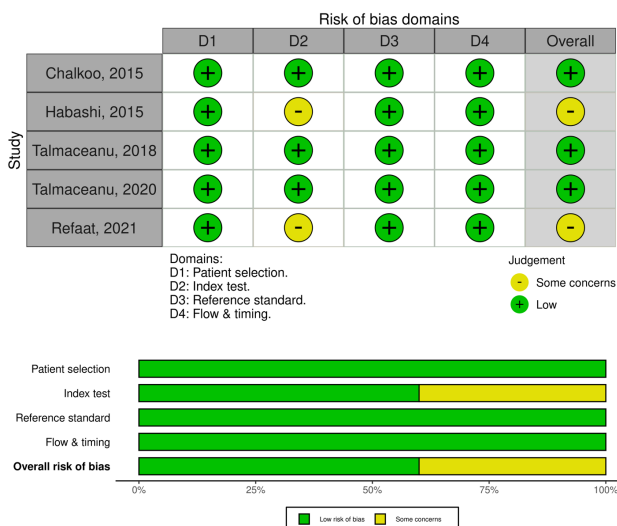


**Figure 1.** PRISMA flow diagram. HRUS=high-resolution ultrasonography; MRI=magnetic resonance imaging; PRISMA=Preferred Reporting Items for Systematic Reviews and Meta-Analyses; TMJ=temporomandibular joint

**Table 2.** Characteristics of the studies

First author, year	Study design	Place setting	Sample size	Patient characteristics	HRUS examination	Outcome	Study limitations
Chalkoo, <sup>12</sup> 2015	Case-control	India	19	Case*: 4 males and 7 females; control*: 3 males and 5 females; 23–70 years old	Open- and closed-mouth position; linear array probe 17 MHz	USG as a noninvasive diagnostic technique was potential for detecting TMJ internal derangement at significantly lower cost.	Small sample sizes
Habashi, <sup>13</sup> 2015	Cross-sectional	Haifa, Israel	39	13 males and 26 females; 18–77 years old	TMJ static and dynamic movement; linear array transducer 5–17 MHz	<ul style="list-style-type: none"> <li>• HRUS was a potential imaging method for diagnosing TMJ disc displacement.</li> <li>• MRI was still needed in selected cases.</li> </ul>	<ul style="list-style-type: none"> <li>• Small population</li> <li>• Each examination was conducted by a single examiner.</li> </ul>
Talmaceanu, <sup>14</sup> 2018	Cross-sectional	Romania	74	14 males and 60 females; 13–69 years old	TMJ static and dynamic movement; linear transducer 6.5–13 MHz	HRUS demonstrated high accuracy, sensitivity, and specificity in diagnosing TMJ disc displacement.	<ul style="list-style-type: none"> <li>• Each examination was performed by a single radiologist.</li> <li>• The accuracy of MRI might be slightly different (accuracy not 100%).</li> <li>• Influenced by the examiner's experience</li> </ul>
Talmaceanu, <sup>11</sup> 2020	Cross-sectional	Romania	50	8 males and 42 females; 15–61 years old	TMJ static and dynamic movement; linear array transducer 8–40 MHz; linear array probe 6.5–13 MHz	<ul style="list-style-type: none"> <li>• HRUS showed high sensitivity, specificity, and accuracy for TMJ disc displacement.</li> <li>• The 20 MHz probe enabled a better differentiation tissue structure compared to 13 MHz.</li> </ul>	NA
Refaat, <sup>15</sup> 2021	Cross-sectional	Egypt	40	10 males and 30 females; 16–59 years old	Static position; linear array transducer 5–17 MHz	HRUS may be used to diagnose internal derangement	Small sample sizes

HRUS=high-resolution ultrasonography; MRI=magnetic resonance imaging; NA=not available; TMJ=temporomandibular joint; USG=ultrasonography  
 \*Case was patients with TMJ problems; †control consisted of patients who had neither any history nor any signs and symptoms of TMJ disorder on the head and neck examination. All patients had TMJ disorders, and all studies used MRI as the gold standard



**Figure 2.** Quality assessment using Quality Assessment of Diagnostic Accuracy Studies-2 (QUADAS-2)

MHz linear array transducer and a 6.5–13 MHz linear array probe. Table 2 presents the characteristics of these studies.

**Quality of the studies**

The results of the methodological quality assessment of all studies are presented in Figure 2. All studies included patients with TMJ disorders. MRI was performed as the gold standard test in all studies. The HRUS images were obtained using a 5–17 MHz linear probe array. Two studies did not explain the blinding process, and three blinded the examiners to the clinical and MRI findings. Examinations were performed in a dark room with the patient in a supine position.

**MRI compared to HRUS**

The results showed variations in sensitivity, specificity, and accuracy, ranging from 74.3–93.7%,

84.2–100%, and 77.7–91.7%, respectively<sup>11–15</sup> (Table 3). Three studies<sup>11,13,14</sup> reported high sensitivity, specificity, and accuracy of HRUS for diagnosing TMJ disc displacement. Meanwhile, Refaat et al<sup>15</sup> suggested that improving image quality through increased and purer frequencies in sonographic units could make HRUS widely applicable for diagnosing internal derangement of TMJ. Similarly, Chalkoo et al<sup>12</sup> indicated that HRUS could identify the disc, its position, and the presence of TMJ internal derangements in the sagittal and coronal sections. Nonetheless, a larger number of patients is required to draw a definitive conclusion. Among the five included studies, the HRUS examination was performed in both a static position (open- and closed-mouth) and during dynamic movement of TMJ in three studies,<sup>11,13,14</sup> whereas the other two conducted the HRUS examination only in a static position.<sup>12,15</sup>

**DISCUSSION**

Numerous imaging techniques, each with their strengths and weaknesses, have been employed to diagnose TMJ dislocation. The present study evaluated HRUS as a promising alternative diagnostic tool for TMJ dislocation, comparing its efficacy with the conventional gold standard MRI. This review found that the accuracy of sonography in diagnosing TMJ dislocation ranged from 77.7% to 91.7%, with a sensitivity of 74.3% to 93.7%, specificity of 84.2% to 100%, positive predictive value of 68.2% to 100%, and negative predictive value of 64.0% to 98.3%. The variations in the results can be partially attributed to the diverse resolutions of the ultrasound equipment. All five studies utilized multiple transducers with frequencies ranging from 5 to 17 MHz. Transducers with a high resolution ( $\geq 12$  MHz) offer improved visualization of the TMJ. Another factor influencing sonography

**Table 3.** Sensitivity and specificity data of each study

First author, year	Sensitivity (%)	Specificity (%)	PPV	NPV	LR+ (%)	LR- (%)	AUC (%)	Accuracy (%)
Chalkoo, <sup>12</sup> 2015	90.9	100	100	88.9	$\infty$	0.1	N/A	N/A
Habashi, <sup>13</sup> 2015	74.3	84.2	89.7	64.0	4.7	0.3	N/A	77.7
Talmaceanu, <sup>14</sup> 2018	93.1	87.8	87.1	93.5	7.7	0.1	N/A	90.3
Talmaceanu, <sup>11</sup> 2020	75.8	86.8	90.3	68.7	5.8	0.3	N/A	80
Refaat, <sup>15</sup> 2021	93.7	89.1	68.2	98.3	8.6	0.1	91.4	91.7

AUC=area under the curve; LR+=positive likelihood ratio; LR-=negative likelihood ratio; NPV=negative predictive value; PPV=positive predictive value

results is the operator's skill and experience, as sonography relies on the operator's expertise. While three studies<sup>11,13,14</sup> specified that senior radiologists with years of experience in sonography conducted the sonography examinations, two studies<sup>12,15</sup> did not provide information about the examiners.

Three studies<sup>12,14,15</sup> recorded outstanding sensitivity (>90%), and all studies<sup>11-15</sup> showed excellent specificity (>80%) for HRUS in diagnosing TMJ dislocation compared to MRI. Ultrasound must exhibit high sensitivity for routine use as a screening test and good specificity for a confirmatory test. Additionally, four of five studies reported the accuracy of HRUS compared to MRI in diagnosing TMJ dislocation, with an accuracy exceeding 75% in all four studies. This further supports the assertion that HRUS can be an alternative to MRI for diagnosing TMJ dislocation.

Refaat et al<sup>15</sup> proposed enhancing image quality using higher and clearer frequencies in sonographic units, bringing an interesting dimension to the discussion and suggesting a potential method of improving HRUS technology. The idea involves obtaining pictures through sonography of the musculoskeletal system and using advanced and clearer sound frequencies. This suggestion holds significance, as it could contribute to refining the capabilities of HRUS, making it more effective in diagnosing conditions such as TMJ dislocation.

The assessment of internal derangement of the TMJ has prompted the utilization of various imaging techniques, each with its distinctive strengths and weaknesses. A crucial aspect of this diagnostic pursuit is determining the disc position, which often requires specialized information that contributes to an accurate diagnosis. Dynamic sonography exhibited a higher specificity (95%) than MRI. The divergence in HRUS examination approaches among the selected studies adds complexity to interpreting the results. Three studies<sup>11,13,14</sup> incorporated dynamic assessments, evaluating both open- and closed-mouth positions and dynamic movements to provide a more comprehensive understanding of TMJ functionality. In contrast, the two remaining studies<sup>12,15</sup> conducted HRUS examinations solely in static positions. This discrepancy emphasizes the variability in methodologies across research endeavors, prompting the need for standardized protocols to ensure consistency and comparability in future studies.

Comparisons with previous studies<sup>6-8</sup> indicated that dynamic high-resolution sonography has valuable potential for diagnosing TMJ disorders, offering information on internal derangement and abnormal disc positions. However, limitations in distinguishing certain conditions and the need for better standardization of sonographic techniques underscore the complementary role of MRI in selected cases.

The limitation of this systematic review was the small sample sizes in three out of five studies included. Therefore, further research with larger sample sizes is necessary to validate these findings.

A good diagnostic tool should have high sensitivity and specificity. The findings of this study have significant implications for policy and practice regarding the diagnosis of TMJ disorders. The positive results regarding the sensitivity and specificity of sonography underscore its potential as a valuable diagnostic tool for TMJ evaluation.

In conclusion, HRUS showed high sensitivity, specificity, and accuracy in diagnosing TMJ disc displacement. HRUS is a promising and reliable alternative diagnostic tool for assessing the position of TMJ discs in TMJ disorders. However, the diagnostic value of HRUS is highly dependent on the examiner's skills and should be correlated with the clinical findings. Notably, MRI is still necessary for more complex or advanced cases.

#### Conflict of Interest

The authors affirm no conflict of interest in this study.

#### Acknowledgment

None.

#### Funding Sources

None.

## REFERENCES

- Almeida FT, Pacheco-Pereira C, Flores-Mir C, Le LH, Jaremko JL, Major PW. Diagnostic ultrasound assessment of temporomandibular joints: a systematic review and meta-analysis. *Dentomaxillofac Radiol.* 2019;48(2):20180144.
- Neff A, McLeod N, Spijkervet F, Riechmann M, Vieth U, Kolk A, et al. The ESTMJS (European Society of Temporomandibular Joint Surgeons) consensus and evidence-based recommendations on management of condylar dislocation. *J Clin Med.* 2021;10(21):5068.
- Baba IA, Najmuddin M, Shah AF, Yousuf A. TMJ imaging: a review. *Int J Contemp Med Res.* 2016;3(8):2253-56.
- Gharavi SM, Qiao Y, Faghiehimehr A, Vossen J. Imaging of the temporomandibular joint. *Diagnostics (Basel).* 2022;12(4):1006.
- Talmaceanu D, Lenghel LM, Bolog N, Hedesiu M, Buduru S, Rotar H, et al. Imaging modalities for temporomandibular joint disorders: an update. *Clujul Med.* 2018;91(3):280-7.
- Xiong X, Ye Z, Tang H, Wei Y, Nie L, Wei X, et al. MRI of



- temporomandibular joint disorders: recent advances and future directions. *J Magn Reson Imaging*. 2021;54(4):1039–52.
7. Maranini B, Ciancio G, Mandrioli S, Galiè M, Govoni M. The role of ultrasound in temporomandibular joint disorders: an update and future perspectives. *Front Med (Lausanne)*. 2022;9:926573.
  8. Kundu H, Basavaraj P, Kote S, Singla A, Singh S. Assessment of tmj disorders using ultrasonography as a diagnostic tool: a review. *J Clin Diagn Res*. 2013;7(12):3116–20.
  9. Giozet AF, Iwaki LCV, Grossmann E, Previdelli ITS, Pinto GNS, Iwaki Filho L. Correlation between clinical variables and magnetic resonance imaging findings in symptomatic patients with chronic temporomandibular articular disc displacement with reduction: a retrospective analytical study. *Cranio*. 2019;37(6):374–82.
  10. Yang Z, Wang M, Ma Y, Lai Q, Tong D, Zhang F, et al. Magnetic resonance imaging (MRI) evaluation for anterior disc displacement of the temporomandibular joint. *Med Sci Monit*. 2017;23:712–8.
  11. Talmaceanu D, Lenghel LM, Bolog N, Buduru S, Leucuta D, Rotar H. High-resolution ultrasound imaging compared to magnetic resonance imaging for temporomandibular joint disorders: an in vivo study. *Eur J Radiol*. 2020;132:109291.
  12. Chalkoo AH, Ahmad MB, Naikoo FA. Magnetic resonance imaging and ultrasonography in the diagnosis of temporomandibular joint internal derangements: a comparative study. *J Indian Acad Oral Med Rad*. 2015;27:198–202.
  13. Habashi H, Eran A, Blumenfeld I, Gaitini D. Dynamic high-resolution sonography compared to magnetic resonance imaging for diagnosis of temporomandibular joint disk displacement. *J Ultrasound Med*. 2015;34(1):75–82.
  14. Talmaceanu D, Lenghel LM, Bolog N, Popa Stanila R, Buduru S, Leucuta DC, et al. High-resolution ultrasonography in assessing temporomandibular joint disc position. *Med Ultrason*. 2018;1(1):64–70.
  15. Refaat MM, Yousef MI, Torky AA, Sarow ML. Ultrasonography compared to magnetic resonance imaging for the diagnosis of the temporomandibular joint disc displacement. *Benha J Appl Sci*. 2021;6(6 Part 1):133–40.