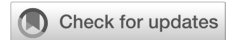

## Multiple vaginal stones secondary to an ectopic ureter in an adult female patient: a case report

Muhammad Adi Satrio Lazuardi,<sup>1</sup> Andrie Rhomdhon Kurniawan,<sup>2</sup> Pradana Nurhadi,<sup>1</sup> Besut Daryanto<sup>1</sup>



pISSN: 0853-1773 • eISSN: 2252-8083  
<https://doi.org/10.13181/mji.cr.236388>  
**Med J Indones.** 2022;31:266–8

**Received:** August 08, 2022  
**Accepted:** February 27, 2023  
**Published online:** March 10, 2023

### Authors' affiliations:

<sup>1</sup>Department of Urology, Faculty of Medicine, Universitas Brawijaya, Saiful Anwar General Hospital, Malang, Indonesia, <sup>2</sup>Kanjuruhan General Hospital, Malang, Indonesia

### Corresponding author:

Besut Daryanto  
 Department of Urology, Faculty of Medicine, Universitas Brawijaya, Saiful Anwar General Hospital, Jalan Jaksa Agung Suprpto No. 2, Malang, East Java 65112, Indonesia  
 Tel/Fax: +62-341-333030  
 E-mail: urobess.fk@ub.ac.id

### ABSTRACT

Vaginal stone is a rare case with low incidence. Ectopic ureter insertion into the vagina is one of the congenital abnormalities that may lead to vaginal stone formation. True incontinence persisting until adulthood might indicate an ectopic ureter, often associated with a complete duplex renal system. We reported an adult female that came with a chief complaint of true incontinence since she was young. However, it was left untreated due to limited healthcare facilities in her area and low socioeconomic status. The computed tomography examination revealed a right complete duplex renal system, with upper moiety inserted into the vagina, and multiple vaginal stones. Thus, stone removal and ureteroneocystostomy procedure were performed. No further complaints or complications were recorded after the hospital discharge.

**KEYWORDS** ectopic ureter, ureteroneocystostomy, vaginal stone

Vaginal stones are a rare condition that can be misdiagnosed as other diseases.<sup>1,2</sup> The overall incidence is unclear because most cases are only reported as case studies. In 1900, Halban was the first to report a case of vaginal stone that developed into a giant vaginal cystocele.<sup>1</sup>

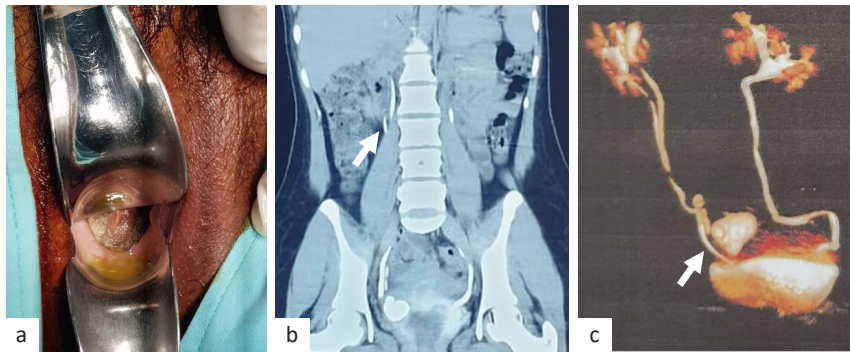
Vaginal stones can be classified into primary or secondary based on their etiology.<sup>2</sup> Primary vaginal stones result from stagnant urine within the vagina, while secondary vaginal stones are caused by a nidus from the deposition of inorganic salts around foreign bodies in the vagina.<sup>3</sup> They are commonly caused by congenital genitourinary abnormalities, such as an ectopic ureter, trauma, and urethrovaginal fistula secondary to scarring after gynecologic surgeries.<sup>3</sup>

Ectopic ureter is often associated with a duplex renal system, which can be classified into a complete and incomplete double system ureter. Ectopic ureter insertion into the vagina can form vaginal stones due

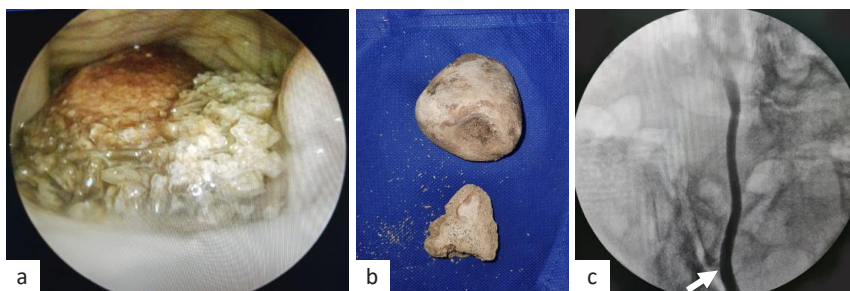
to urinary stasis and repeated infection.<sup>1,3</sup> In this report, we presented a case of multiple giant vaginal stones due to an ectopic ureter associated with a duplex renal system in an adult female patient.

## CASE REPORT

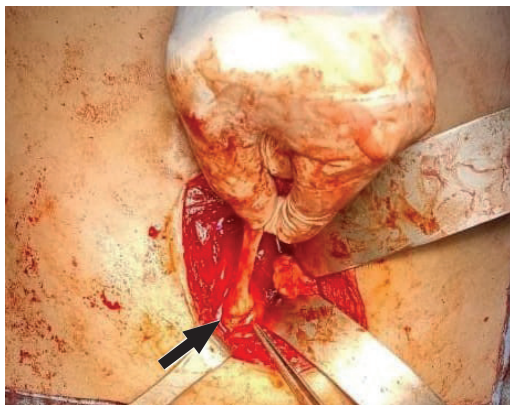
A 30-year-old female came with a chief complaint of true incontinence since an early age. At first, she considered it a normal event, and she only wore diapers during her daily activities. She also complained of repeated lower urinary tract symptoms (LUTS) that sometimes persisted for 1–2 months and vaginal pain. When she was 13 years old, she went to primary health care and was diagnosed with a neuro-urogenital problem without further examination. It was left untreated due to limited healthcare facilities in her area and low socioeconomic status. She had been married for 2 years prior, had no children, and had no medical



**Figure 1.** Clinical findings. (a) Vaginal stones on direct observation of the vagina; (b) abdominal CT scan with contrast showing a complete duplex renal system (white arrow); (c) the 3D image of abdominal CT scan showing a complete duplex renal system (white arrow). CT=computed tomography



**Figure 2.** Findings during surgery. (a) Vaginal stones on colposcopy examination; (b) extracted multiple giant vaginal stones; (c) retrograde ureterography of the upper and lower moieties (white arrow)



**Figure 3.** Ureteroneocystostomy using Lich-Gregoir technique (arrow). The ureter was dissected from the bladder and then passed through a submucosal tunnel, across a more lateral and cranial portion of the bladder, and finally sutured to the new mucosal insertion point

history. She sought therapy from a urologist because of the ongoing incontinence that was accompanied by a pain sensation during sexual intercourse.

Her physical examination showed a normal vulva and urine flowing from the vagina. The brown substances in her vagina had a hard texture, stone-like, and were visible on direct observation, measured approximately

50 x 30 and 30 x 20 mm in size. The culture of the urine sample collected during admission revealed *Proteus mirabilis*. Urinalysis showed leucocytes 219 per high-power field [HPF] (normal: <5 HPF) and erythrocytes 27 per HPF (normal: <5 HPF), while another laboratory finding was normal. Computed tomography (CT) scan examination and 3D images revealed a complete duplex renal system, with upper moiety inserted into the vagina (Figure 1).

Colposcopy examination revealed vaginal stones and ureteral orifice in the vagina. Two stones were found stuck and overlapping each other, near the edge of the right ectopic ureteral orifice. Thus, a stone removal procedure was performed. Cystoscopy and retrograde ureterography followed by ureteroscopy procedure were performed twice through transvaginal and transurethral approaches, which revealed a complete duplex renal system with distal ureteral stenosis in the upper moiety and proximal ureteral stenosis in the lower moiety. It was followed by lysis of adhesion and insertion of a double J (DJ) stent in both ureters (Figure 2).

Ureteroneocystostomy was performed using the Lich-Gregoir technique, followed by a DJ stent

insertion in the upper and lower moieties (Figure 3). Until 2 months of postoperative follow-ups, no signs of any dysuria and urine leakage were found.

## DISCUSSION

Vaginal stones are extremely rare, and only one case has been reported in Indonesia.<sup>1</sup> Urinary incontinence in adulthood is often associated with an overreactive bladder, urinary tract infection (UTI), and ectopic ureter.<sup>1,2</sup> Ectopic ureter into the vagina can cause stagnant urine inside the vagina; the normally acidic vagina becomes alkaline, which promotes bacterial infections that produce urease, such as *Klebsiella* and *Proteus*, and aids in the formation of triphosphate stones. Although the risk factor for vaginal stones has not been accurately defined, avoiding recurrent UTIs, sufficient treatment of urinary incontinence, and early assessment of the anatomic deformity of the genitourinary system can prevent the development of vaginal stones.<sup>2-4</sup>

Vaginal stones develop slowly and are only detected when they are large enough to show clinical manifestation.<sup>2</sup> True incontinence is one of the most clinical manifestations found in all primary vaginal stone cases, which presents from the early stage of the disease. Every urogenital stone can cause LUTS, including frequency, urgency, and dysuria.<sup>5,6</sup> Moreover, vaginal stones cause vaginal pain and pain during sexual intercourse. Early diagnosis should be made as this disease may lead to functional and physiological complications.<sup>7,8</sup> In this case, the patient presented with repeated LUTS that sometimes persisted for 1–2 months, vaginal pain, and pain sensation during sexual intercourse that greatly affected her sex life. During her childhood, she used to get mocked to the point where she refused to go to school, and she still avoids seeing her childhood friends for fear of getting mocked.

A complete physical examination of the urogenital system in patients with urogenital symptoms is important to clinically diagnose vaginal stones. Moreover, a radiology examination should be done to confirm the etiology of the disease.<sup>9</sup> In this study, an abdominal CT scan with contrast showed a complete duplex renal system with an ectopic upper moiety insertion into the vagina (Figure 1).

Primary vaginal stones are caused by urinary deposition that can be resulted from congenital anatomical abnormalities or fistula formation after gynecologic surgery.<sup>10,11</sup> Therefore, surgery is the best

treatment for primary vaginal stone cases in resolving incontinence and preventing further complications.<sup>11,12</sup> In this study, ureteroneocystostomy was performed using the Lich-Gregoir technique because it was easier to perform than other techniques with a comparable success rate.<sup>13</sup>

In conclusion, vaginal stone due to an ectopic ureter and complete double system is a rare case and can lead to functional and psychological complications. A thorough physical examination is essential to make the diagnosis, and a radiology examination is mandatory to confirm the etiology. Surgery shows a promising result in resolving incontinence and preventing further complications.

### Conflict of Interest

The authors affirm no conflict of interest in this study.

### Acknowledgment

None.

### Funding Sources

None.

## REFERENCES

- Saxena RK, Deepika S, Tewari V. Colpolithiasis: a mini review. *Indian J Obstet Gynecol Res.* 2019;6(4):420–30.
- Wei D, Xie Y, Niu X. Vaginal stones caused by urethrovaginal fistula: a case report. *Medicine (Baltimore).* 2019;98(47):e18003.
- Noegroho BS, Adi K, Salima S, Paulina, Mustafa A, Bahagianto AF. Giant vaginal stone as a complication of long-term urethrovaginal fistula: a case report. *Urol Case Rep.* 2020;34:101491.
- Griffiths KM, Towers GD, Yaklic JL. Vaginal urinary calculi formation secondary to vaginal mesh exposure with urinary incontinence. *Case Rep Obstet Gynecol.* 2017;2017:8710315.
- Aronson SL, Hovius MC, Janszen EWM. Large primary vaginal stone in a woman with multiple sclerosis. *BMJ Case Rep.* 2020;13(10):e235103.
- Pincus JB, Sand PK. Vaginal calculus in a patient with a mid-urethral sling mesh exposure. *Int J Gynaecol Obstet.* 2020;151(3):456–7.
- Fedrigon D, Bretschneider CE, Muncey W, Stern K. Removal of large primary vaginal calculus using the nephroscope and endoscopic ultrasonic lithotrite: a case report. *J Endourol Case Rep.* 2020;6(2):92–5.
- Xu Q, Zou Y. Primary vaginal calculus in a woman with urogenital sinus anomaly: a case report. *BMC Urol.* 2020;20:142.
- Zhang J, Luo DY, Shen H. Surgical treatment for huge vaginal stone secondary to vaginal mesh exposure with stress urinary incontinence. *Int Urol Nephrol.* 2021;53:1599–601.
- Castellan P, Nicolai M, De Francesco P, Di Tizio L, Castellucci R, Bada M, et al. Primary vaginal calculus in a woman with disability: case report and literature review. *J Endourol Case Rep.* 2017;3(1):182–5.
- Zilberlicht A, Feiner B, Haya N, Auslender R, Abramov Y. Surgical removal of a large vaginal calculus formed after a tension-free vaginal tape procedure. *Int Urogynecol J.* 2016;27(11):1771–2.
- Miller NL. Primary vaginal stones. *Obstet Gynecol.* 1973;41(3):459–60.
- Zhu X, Wang J, Zhu H, Huang L, Chen C, Wang L, et al. Lich-Gregoir vesico-ureteral reimplantation for duplex kidney anomalies in the pediatric population: a retrospective cohort study between laparoscopic and open surgery. *Transl Pediatr.* 2021;10(1):26–32.