

July 2019

## Evaluation of the frequency of mucous retention cysts in the maxillary sinus in a Turkish population using cone-beam computed tomography

Nihat Lacin

*Department of Oral and Maxillofacial Surgery, Faculty of Dentistry, Izmir Katip Celebi University, Turkey,*  
nihat.lacin@hotmail.com

Birkan Tatar

*Department of Oral and Maxillofacial Surgery, Faculty of Dentistry, Izmir Katip Celebi University, Turkey*

Follow this and additional works at: <https://scholarhub.ui.ac.id/mjhr>



Part of the [Medicine and Health Sciences Commons](#)

---

### Recommended Citation

Lacin N, Tatar B. Evaluation of the frequency of mucous retention cysts in the maxillary sinus in a Turkish population using cone-beam computed tomography. Makara J Health Res. 2019;23.

## Evaluation of the frequency of mucous retention cysts in the maxillary sinus in a Turkish population using cone-beam computed tomography

Nihat Lacin\*, Birkan Tatar

Department of Oral and Maxillofacial Surgery, Faculty of Dentistry, Izmir Katip Celebi University, 35620 Izmir, Turkey

\*E-mail: [nihat.lacin@hotmail.com](mailto:nihat.lacin@hotmail.com)

---

### Abstract

**Background:** Mucous retention cyst (MRC) of the maxillary sinus (MS) is an asymptomatic pathology generally found during routine radiographic examination. This study aimed to investigate the frequency of MRCs in the MS from a Turkish population using randomly selected cone-beam computed tomography (CBCT) images. **Methods:** CBCT images of randomly selected systemically healthy subjects (n = 300; of which 156 were men and 144 were women with a mean age of 40.18 [age range: 18–65 years]) were included in this retrospective study. The images were evaluated, and MRC was detected as a dome-shaped radiopaque lesion on the floor or walls of the MS. **Results:** MRC was detected in 30 (10%) of 300 patients via CBCT imaging; 14 patients had bilateral MRC and 16 had unilateral MRC. The cysts were detected on CBCT images obtained from 17 men and 13 women. No significant differences were observed in the incidence of MRC based on location (right or left side) and gender ( $p > 0.05$ ). **Conclusions:** CBCT is a useful tool that facilitates three-dimensional evaluation of pathologies, such as MRCs, in the MS.

*Keywords: cone-beam computed tomography, epidemiology, maxillary sinus, nonodontogenic cysts*

---

### Introduction

The maxillary sinus (MS) is a cavity located bilaterally in the body of the maxilla above the level of the alveolar bone.<sup>1</sup> It is the largest of all paranasal sinuses and is covered by a thin mucous membrane that adheres to the periosteum.<sup>2</sup> The functions of the MS include adding resonance to the voice, reducing the weight of the skull, as well as warming and moisturizing the inspired air.<sup>3</sup>

MS pathologies can be basically classified into congenital, inflammatory, odontogenic, traumatic, neoplastic, and iatrogenic types.<sup>4</sup> Mucous retention cysts (MRCs) are the most common lesions in the MS and are characterized by the retention of mucus secreted from the mucous glands of the sinus epithelial tissue.<sup>5,6</sup> MRCs are mostly asymptomatic, slow-growing lesions that affect patients of both genders and all ethnic groups across all ages.<sup>5,7</sup> Allergy, rhinitis, barotrauma, dental disease, inflammation, and chronic rhinosinusitis have been proposed the etiologic factors that predispose patients to MRC.<sup>8</sup> Disappearance or spontaneous regression of MRCs is observed in 16%–41% of cases; hence, patients with MRCs should undergo long-term follow-up with no specific treatment, other than those that provide symptomatic relief, if necessary.<sup>9</sup>

Radiographically, MRCs appear as well-defined, homogeneous, dome-shaped, radiopaque lesions (no cortical lining), which vary in size and extend through the lumen

of the MS.<sup>10</sup> The MRCs commonly emanate from the floor of the sinus and are unilaterally or bilaterally located.<sup>9</sup> Waters' view (occipitomental radiograph) is considered as the ideal conventional imaging method for the evaluation of the MS. However, the most inferior and posterior aspects of the sinus are not clearly visible due to the posterior teeth and the alveolar process.<sup>11</sup> Panoramic radiography is a tool used to conveniently detect MS pathologies; nonetheless, limitations, such as image overlay of the inferior nasal concha and nasal cavities on the MS region, may lead to false positive results.<sup>12</sup>

Cone-beam computed tomography (CBCT) reproduces the maxillofacial hard tissue structure as a three-dimensional (3D) image with negligible distortion and significantly lowers the dose of radiation compared with conventional computed tomography. The high-resolution CBCT images are extremely effective for detailed examinations of the maxillofacial region that are not possible with panoramic radiographs.<sup>13</sup> CBCT is an important tool for the evaluation and planning of treatment based on alterations in the MS.<sup>9,14</sup> The frequency of MRCs varies significantly according to geographical and climatic specificities and differences.<sup>15</sup> In the literature, the prevalence rates of MRCs in various populations significantly vary (1.4%–35.6%) with the different imaging methods used.<sup>8</sup> There is no information about the prevalence of MRCs in the Turkish population based on 3D radiographic analysis in sufficient sample volumes.

Thus, this study aimed to investigate the frequency of MRCs in the MS in a Turkish population using high-resolution CBCT images.

## Methods

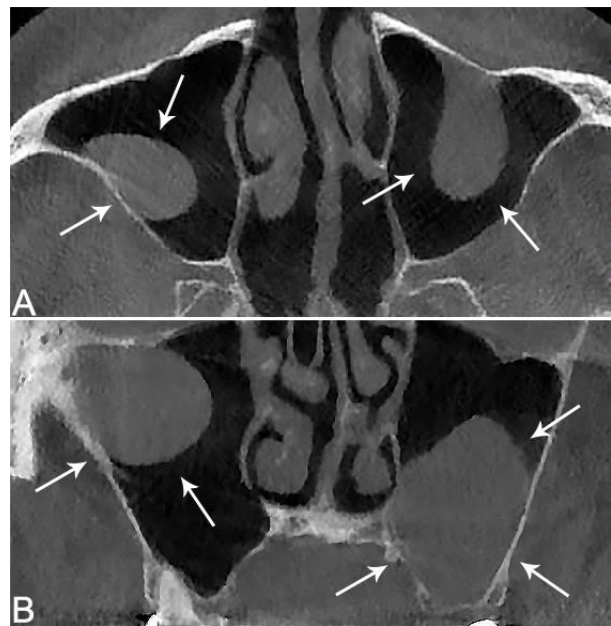
A retrospective study using CBCT images of randomly selected patients who were referred to Izmir Katip Celebi University, Izmir, Turkey was conducted in accordance with the Declaration of Helsinki. A written informed consent was obtained from the patients before radiographic evaluation, and the study was approved by the institutional review board of Izmir Katip Celebi Non-Interventional Clinical Studies (approval no. 99).

High-quality maxillary CBCT images of patients older than 18 years were selected. The CBCT images were obtained for diagnostic purposes as part of a comprehensive evaluation of periodontal or endodontic treatment prior to implant surgery, impacted tooth surgery, or orthodontic treatment. Patients whose radiographs did not include both the whole MS and artifacts that hindered the evaluation of the sinuses and those with a history of MS surgery, trauma, or pathologies in the anterior teeth were excluded from the study.

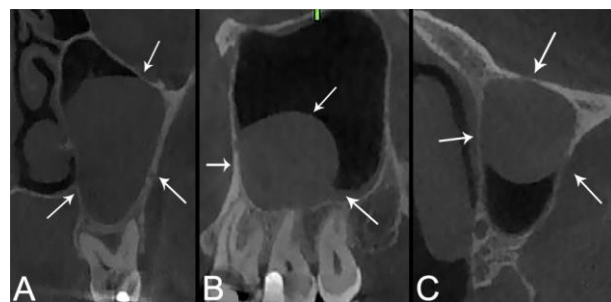
A total of 300 patients who underwent CBCT examinations between January 2013 and December 2018 were included in this study. The participants comprised 156 (52%) men and 144 (48%) women, with a mean age of 40.18 (range: 18–65) years. All scans were obtained using a NewTom 5G CBCT device (QR srl, Verona, Italy), operating at 110 kVp and 1–20 mA with a  $15 \times 12$  field of view and a voxel size of 0.2 mm in supine position. The images were obtained from the axial, coronal, and cross-sectional sides with 1-mm intervals.

The diagnostic criterion for an MRC was the detection of a dome-shaped radiopaque lesion on the floor or walls of the MS (Figure 1). As shown in Figure 2, the presence of an MRC was determined by examining the coronal, sagittal, and axial CBCT sections on the number needed to treat station (QR srl). In addition, gender and size were considered while analyzing the MRCs.

**Statistical Analysis.** Statistical analysis was performed using R version 3.2.3 (2015, R Foundation for Statistical Computing, Vienna, Austria). In the current study, the sample size was 300, and the chi-square power was calculated for two independent categorical variables: two level (male and female) and four levels (right sinus, left sinus, bilateral, absent). The power for medium effect size (as Cohen<sup>16</sup> indicated that the  $w$  values of 0.1, 0.3, and 0.5 represent small, medium, and large effect sizes, respectively) was 0.996, with a degree of freedom at 3 and a significance level of 0.05, which indicated that the power of the test was reliable.



**Figure 1.** Radiographic view of a mucous retention cyst. (A) Coronal. (B) Axial sections of a bilateral mucous retention cyst in a 57-year-old male patient



**Figure 2.** Various sections of the unilateral mucous retention cysts from different patients. (A) Coronal view from a 53-year-old male patient. (B) and (C) Sagittal and axial images from a 49-year-old female patient

The power for medium effect size (as Cohen<sup>16</sup> indicated that the  $w$  values of 0.1, 0.3, and 0.5 represent small, medium, and large effect sizes, respectively) was 0.996, with a degree of freedom at 3 and a significance level of 0.05, which indicated that the power of the test was reliable.

## Results

In the CBCT images, the MRC was detected in 30 (10%) of 300 patients (Table 1). Among them, 14 (4.7%) had bilateral MRCs, and 16 (5.33%) presented with unilateral MRCs. The cysts were detected in the images of 17 (10.89%) men and 13 (9.02%) women; the MRCs were found on the right side in seven patients and on the left side in nine patients (Table 1). The theoretical value of a number less than 5 was calculated as 50.0%; thus, the Pearson's chi-square test result was not reliable because this rate had exceeded 20%.

**Table 1.** Antibacterial activities of *Linum usitatissimum L.* against oral microorganisms controlled with zones of inhibition in millimeters using disc diffusion method (mean  $\pm$  SE)

Zone of inhibition	Male n (%)	Female n (%)	Total n (%)
Right	3 (1.9)	4 (2.8)	7 (2.3)
Left	5 (3.2)	4 (2.8)	9 (3.0)
Bilateral	9 (5.8)	5 (3.5)	14 (4.7)
Absent (-)	139 (89.1)	131 (91.0)	270 (90.0)
Total	156 (100.0)	144 (100.0)	300 (100.0)

According to the Exact test calculation, a  $p$  value = 0.799 indicated that the lack of significant relationship between MRC and gender.

## Discussion

MRCs are mucous-filled cysts that mostly develop when the seromucous glands of the mucosa in the MS are obstructed. MRCs are usually asymptomatic and seldom require treatment, and they are commonly diagnosed via routine radiographic examinations.<sup>5</sup> Clinically, MRCs may cause complaints when they obstruct the MS outflow.<sup>17</sup> Radiological imaging detection along with clinical examination is mandatory to define the characteristics, behavior, therapeutic protocol of MRCs and differential diagnose it from other pathologies, such as mucocele, polyp, sinusitis, neoplasm, and odontogenic cyst.<sup>9,18</sup> CBCT is a convenient tool for diagnosis and treatment planning related to MS diseases.<sup>19</sup> It is superior to panoramic imaging and other two-dimensional (2D) conventional methods for the evaluation of maxillo-facial anatomical structures.<sup>20</sup>

A study has shown significant differences in the diagnosis of MRC using CBCT and panoramic images.<sup>15</sup> Five out of 28 MRCs detected on CBCT sections had not been observed on panoramic radiographs in their study, which could be considered as a limitation of panoramic imaging as the entire length of MS is not displayed. The roof of the MS and minor changes in the superolateral regions cannot be viewed in detail using panoramic radiography.<sup>21</sup> A different study comparing CBCT with 2D panoramic images has indicated that CBCT remains the most effective radiological method for the evaluation of inflammatory changes in the MS.<sup>22</sup> A CBCT examination of the maxilla is mostly performed prior to a surgical sinus lift and augmentation process for dental implant placement in the maxillary posterior area. Incidental findings, such as thickening of sinus mucosa or MRC, might indicate an outflow obstruction, which can affect treatment planning.<sup>23</sup>

The presence of MRCs may differ based on gender, age, and ethnicity. Studies in a Brazilian population using panoramic radiographs have shown variations in the incidence of MRC ranging from 3.6% to 10.1%. Meanwhile, in another study that used CBCT, the

incidence was 21.4%.<sup>20</sup> In studies using panoramic imaging, the reported frequency of MRCs was between 5.1% and 14%, which may exhibit a large variability and might be correlated to technical radiologic factors, such as imaging method (2D or 3D), field of view applied, and aspect of the visualized MS.<sup>24</sup> In the present study, MRCs were found more frequently in men than in women. However, similar to the results of a previous study that used panoramic images of 173 orthodontic patients,<sup>23</sup> the difference was not statistically significant.

Sinus floor elevation is a commonly used technique to obtain vertical bone volume during maxillary implant placement. However, this technique provokes post-operative edema, which is similar to all surgical interventions; hence, the presence of a cystic lesion in the MS may increase the risk of blockage of the drainage from the sinus ostium leading to fluid accumulation in the MS and sinusitis.<sup>25</sup> The removal of an MRC by perforating the Schneiderian membrane before sinus floor elevation followed by bone augmentation after the repair of the perforation with a collagen membrane has been described previously.<sup>26</sup> Aspiration of the liquid content of the cyst before sinus augmentation has also been reported.<sup>27,28</sup> Meanwhile, in some studies, the augmentation procedures were not conducted due to additional risks.<sup>27,28</sup> Thus, the various recommendations for the management of MRCs prior to and during implant surgery showed that conservative methods, such as intentional puncture and aspiration of the cyst contents, can be performed along with bone augmentation and dental implant surgery during the same session in asymptomatic MRC cases.

This study had some limitations. The association between MRC and age was not investigated. Most of the participants in this study comprised people from western Turkey. Further studies must be conducted to explore the correlations between MRC and factors, such as age, climate, and systemic diseases, in a more diverse sample group of the Turkish population.

## Conclusions

MRCs are mainly asymptomatic, slow-growing lesions that do not require treatment in most cases. MRCs were found in 10% of the Turkish population in this study. No

differences were observed in the incidence of MRC based on gender or location (right or left side). CBCT is a useful tool that examines the anatomic features and pathologies of the maxilla.

## Funding

The study received no commercial funding.

## Conflict of Interest Statement

There are no conflicts of interest declared by any of the authors.

Received: February 26, 2019 Accepted: May 23, 2019

## References

- Vogiatzi T, Kloukos D, Scarfe WC, Bornstein MM. Incidence of anatomical variations and disease of the maxillary sinuses as identified by cone beam computed tomography: a systematic review. *Int J Oral Maxillofac Implants*. 2014;29:1301–14.
- Bal M, Berkiten G, Uyanık E. Mucous retention cysts of the paranasal sinuses. *Hippokratia*. 2014;18:379.
- van den Bergh JP, ten Bruggenkate CM, Disch FJ, Tuinzing DB. Anatomical aspects of sinus floor elevations. *Clin Oral Implants Res*. 2000;11:256–65.
- Rege ICC, Sousa TO, Leles CR, Mendonça EF. Occurrence of maxillary sinus abnormalities detected by cone beam CT in asymptomatic patients. *BMC Oral Health*. 2012;12:30.
- Yeung AWK, Tanaka R, Khong PL, von Arx T, Bornstein MM. Frequency, location, and association with dental pathology of mucous retention cysts in the maxillary sinus. A radiographic study using cone beam computed tomography (CBCT). *Clin Oral Invest*. 2018;22:1175–83.
- Albu S. Symptomatic maxillary sinus retention cysts: Should they be removed? *Laryngoscope*. 2010;120:1904–9.
- Veltrini V, Ferreira Júnior O, Oliveira DT. Mucosal cysts of the maxillary sinus: A literature review. *Med Oral*. 2001;6:180–8.
- Giotakis EI, Weber RK. Cysts of the maxillary sinus: a literature review. *Int Forum Allergy Rhinol*. 2013;3:766–71.
- Donizeth-Rodrigues C, Fonseca-Da Silveira M, Gonçalves-De Alencar AH, Garcia-Santos-Silva MA, Francisco-De-Mendonça E, Estrela C. Three-dimensional images contribute to the diagnosis of mucous retention cyst in maxillary sinus. *Med Oral Patol Oral Cir Bucal*. 2013;18:e151–7.
- Arslan İB, Uluyol S, Demirhan E, Kozcu SH, Pekçevik Y, Çukurova İ. Paranasal sinus anatomic variations accompanying maxillary sinus retention cysts: a radiological analysis. *Turk Arch Otorhinolaryngol*. 2017;55:162–5.
- Maestre-Ferrín L, Galán-Gil S, Carrillo-García C, PeñarochaDiago M. Radiographic findings in the maxillary sinus: comparison of panoramic radiography with computed tomography. *Int J Oral Maxillofac Implants*. 2011;26:341–6.
- Vandenberghe B, Jacobs R, Bosmans H. Modern dental imaging: a review of the current technology and clinical applications in dental practice. *Eur Radiol*. 2010;20:2637–55.
- Laçın N, Tatar B, Veli İ, Adıgüzel A. Evaluation of medial lingual foramen with cone-beam computed tomography in a Turkish adult population. *Int Dent Res*. 2018;8:139–43.
- Uner DD, Izol BS, Gorus Z. Correlation between buccal and alveolar bone widths at the central incisors according to cone-beam-computed tomography. *Niger J Clin Pract*. 2019;22:79–84.
- Vieira EM, De Moraes S, de Musis CR, Borges ÁH, Palma VC, da Silva Basilio L, et al. Frequency of maxillary sinus mucous retention cysts in a central Brazilian population. *J Dent*. 2015;16:169–74.
- Cohen, J. *Statistical power analysis for the behavioral sciences*. Hillsdale, N.J.: L. Erlbaum Associates; 1988.
- Bal M, Berkiten G, Uyanık E. Mucous retention cysts of the paranasal sinuses. *Hippokratia*. 2014;18:379.
- Moon IJ, Kim SW, Han DH, Shin JM, Rhee CS, Lee CH, et al. Mucosal cysts in the paranasal sinuses: long-term follow-up and clinical implications. *Am J Rhinol Allergy*. 2011;25:98–102.
- Maillet M, Bowles WR, McClanahan SL, John MT, Ahmad M. Cone-beam computed tomography evaluation of maxillary sinusitis. *J Endod*. 2011;37:753–7.
- Uner DD, Izol BS, Ipek F. The evaluation of the prevalence and localizations and of antral septa in people living in and around Diyarbakir using cone beam computed tomography. *J Oral Maxillofac Radiol*. 2018;6:3–8.
- Carmeli G, Artzi Z, Kozlovsky A, Segev Y, Landsberg R. Antral computerized tomography pre-operative evaluation: relationship between mucosal thickening and maxillary sinus function. *Clin Oral Impl Res*. 2011;22:78–82.
- Martínez-González JM, Barona-Dorado C, Arias-Irimia O, Martínez-Rodríguez N, Fernández-Domínguez M. Panoramic and tomographic implant studies: Role in the diagnosis of sinus disorders. *Med Oral Patol Oral Cir Bucal*. 2010;15:E6011–5.
- Bósio JA, Tanaka O, Rovigatti E, de Gruner SK. The incidence of maxillary sinus retention cysts in orthodontic patients. *World J Orthod*. 2009;10:e7–8.
- Yeung AWK, Tanaka R, Khong PL, von Arx T, Bornstein MM. Frequency, location, and association with dental pathology of mucous retention cysts in the maxillary sinus. A radiographic study using cone beam computed tomography (CBCT). *Clin Oral Invest*. 2018;22:1175–83.
- Lee JW, Yoo JY, Paek SJ, Park WJ, Choi EJ, Choi MG, et al. Correlations between anatomic variations of maxillary sinus ostium and postoperative complication after sinus lifting. *J Korean Assoc Oral Maxillofac Surg*. 2016;42:278–83.
- Pikos MA. Maxillary sinus membrane repair: update on technique for large and complete perforations. *Implant Dent*. 2008;17:24–31.
- Becker ST, Terheyden H, Steinriede A, Behrens E, Springer I, Wiltfang J. Prospective observation of 41 perforations of the Schneiderian membrane during sinus floor elevation. *Clin Oral Implants Res*. 2008;19:1285–9.
- Maiorana C, Beretta M, Benigni M, Cicciù M, Stoffella E, Grossi GB. Sinus lift procedure in presence of mucosal cyst: a clinical prospective study. *JACD*. 2012;4:54–60.