

Case Report

# Cervical pregnancy management by lauromacrogol combined with intrauterine visualization system and vacuum aspiration: two case studies

Xia-Qin Cai<sup>1</sup>, Ting-Ting Gao<sup>1</sup>, Bing Lu<sup>1</sup>, Qing Zhang<sup>1</sup>, Mei-Yuan Jin<sup>1</sup>, Hui-Jie Cheng<sup>2,\*</sup>

<sup>1</sup>Tongde Hospital of Zhejiang Province, 310000 Hangzhou, Zhejiang, China

<sup>2</sup>Wencheng County Hospital of Traditional Chinese Medicine, 325000 Wenzhou, Zhejiang, China

\*Correspondence: [wczyy@zjw.gov.cn](mailto:wczyy@zjw.gov.cn) (Hui-Jie Cheng)

Academic Editor: Michael H. Dahan

Submitted: 7 November 2020 Revised: 21 December 2020 Accepted: 19 January 2021 Published: 15 April 2022

## Abstract

**Background:** Timely and effective intervention can avoid the need for hysterectomy in cervical pregnancy. This study reported 2 cervical pregnancy cases treated with lauromacrogol combined with intrauterine visualization system and vacuum aspiration under direct vision and negative pressure suction. **Cases:** A 33-year-old (para 0-0-2-0) and 26-year-old females (para 1-0-1-1) were admitted to our hospital for amenorrhoea followed by vaginal bleeding, with previous history of laparoscopic salpingectomy for ectopic pregnancy, and cesarean section and hysteroscopic resection of retained placenta after induced abortion, respectively. Both patients were treated with lauromacrogol combined with intrauterine visualization system and vacuum aspiration along with Foley catheter compression. Both surgeries were completed in one go. The effect was significant, safe, feasible, with no massive vaginal bleeding or complications. The serum hCG decreased rapidly, and the length of hospital stay was short. **Conclusions:** This combined treatment method has a definitive effect, and the application can be promoted clinically.

**Keywords:** Cervical pregnancy; Lauromacrogol; Intrauterine visualization system; Vacuum aspiration

## 1. Introduction

Cervical pregnancy is an ectopic pregnancy in which the fertilized ovum is implanted in the cervical canal below the level of the internal os (internal orifice) before development. Being a relatively rare but dangerous form of ectopic pregnancy [1–3], it accounts for less than 1% of ectopic pregnancies, with an incidence rate between 1 in 1000 and 1 in 95000 pregnancies [4].

Though the etiology is unclear, the critical risk factors include previous ectopic pregnancy, previous cesarean delivery, and history of uterine or cervical surgery [5]. Failure to diagnose cervical pregnancy in the early stage, or if misdiagnosis and curettage is performed, can result in massive hemorrhage, which can be life-threatening. In recent years, early diagnosis of cervical pregnancy has been improved owing to an in-depth study and continuous improvement of ultrasound technology [6].

Anticipation of significant bleeding and a management plan to prevent or control bleeding can help avoid hysterectomy. A number of different approaches have been used to control bleeding in cervical ectopic pregnancies. These include cervical electric aspiration [7], Zea technique [8], balloon treatment [9–12], uterine artery embolization (UAE) [13,14], UAE and potassium chloride (KCL) injection [15], prophylactic suture ligation [16], cervical suture [17], cervical artery suture and vasopressin [18], systemic methotrexate (MTX) and cervical cerclage [19], MTX and intracervical injection of vasopressin [20], and local injection

of MTX and KCL [21] or diluted vasopressin [22]. In most cases successful treatment of cervical pregnancies may be achieved through a combination of systemic or local MTX application and means of local hemostasis [23,24]. The associated complications in the management of cervical pregnancies may include infections, uterine infarction, sciatic nerve injury, and necrosis of the bladder or rectum [23].

Previous study showed that conservative measures to manage bleeding in early diagnosed cervical pregnancy can be initiated using cervical artery sutures and cervical vasoconstricting agent vasopressin [18]. It is a feasible method, however, additional UAE or MTX might be considered in cases of persistence serum hCG levels [18,22].

Lauromacrogol is a sclerosing agent and has been shown to be a safe and useful therapy for caesarean scar pregnancies [25,26]. Lauromacrogol injection can produce significant regression of endometrial foci in rat model of endometriosis [27]. Besides, it has been shown to be an effective and safe treatment for gastric varices [28], purely cystic and predominantly cystic thyroid nodules [29] and nodular thyroid disease without causing significant perithyroidal adhesion formation and functional differences [30]. However, its effectiveness in cervical pregnancy has not been explored yet.

Between September 2018 and April 2020, a total of 156 cases of ectopic pregnancy, including 5 cases of caesarean scar pregnancy, and 2 cases of cervical pregnancy,



were successfully treated at our hospital (Tongde Hospital of Zhejiang Province, Hangzhou, China). Therefore, in this study, we will present 2 cases with cervical pregnancy treated with lauromacrogol combined with intrauterine visualization system and vacuum aspiration (Gynovision [Jin-Shan Science & Technology, Chongqing, China]) along with Foley catheter compression.

## 2. Procedure

The routine blood and urine, coagulation function, liver and kidney function, and electrocardiogram (ECG) in both cases were normal before the surgery. Informed consent was obtained from both patients. A fully preoperative preparation was performed, and the blood was prepared. There were no obvious surgical contraindications.

The patients were placed in a lithotomy position and were fully disinfected before the surgery. Under a B-mode ultrasound guidance, a 9-gauge puncture needle was used to insert the gestational sac area from the cervix. A total of 10 mL lauromacrogol was slowly injected at multiple points. Under ultrasound, it was noted that the sac became smaller, ring-shaped, or flaky strengthening state. Color Doppler flow imaging (CDFI) showed that the blood flow signal around the gestational sac was weakened. After the intervention, the patient was shifted to the ward for rest.

On the following day, the embryo sac was removed under a direct intrauterine visualization system. Before surgery, the venous channel was opened so that if there was massive bleeding during the operation, timely and rapid fluid infusion and blood transfusion could be done. Cervical dilation was routinely performed. The visual system was aimed at the gestational sac, and negative pressure suction was performed. After the surgery, the cervix was injected with 10 U of oxytocin, and a Foley balloon was used to compress the wound to stop bleeding. The aspirate was sent for pathological examination, and the amount of vaginal bleeding was observed within 24 h. The serum hCG was reexamined a day after the surgery, and the level was decreased. The patient was discharged after little or no bleeding. No massive vaginal bleeding or other complications were observed. The obtained tissue was sent for pathological examination. Blood, including the serum hCG was reviewed in the follow-up period and B-mode ultrasound was performed.

## 3. Case presentation

### 3.1 Case 1

A 33-year-old female was admitted to our hospital on April 2, 2020, with a complaint of amenorrhoea for 40 days, followed by vaginal bleeding for 4 days. The patient's medical history indicated laparoscopic right salpingectomy for ectopic pregnancy in 2016 (para 0-0-2-0). The menstrual history suggested the last menstrual period to be February 23, 2020, followed by amenorrhoea for 33 days.

On March 26, 2020, the serum human chorionic gonadotropin (serum hCG) was 4502 mIU/mL.

On March 31, the patient experienced heavy menstrual bleeding lasting for 3 days with no abdominal pain. On the same day, serum hCG level was 5732 mIU/mL, a B-mode ultrasound indicated an abnormal echo in the uterus (a dark area about  $0.9 \times 0.5$  cm in size seen at a distance of 4.4 cm from the fundus), and the presence of fluid was also observed in the recto-uterine pouch (2.7 cm). The patient request to be discharged from the hospital.

On April 2, 2020, the patient was admitted to our hospital. The differential diagnosis was early pregnancy, threatened abortion, and incomplete abortion. The patient was a young woman, unmarried, and had no children. The purpose of management was to preserve the patient's fertility and reduce complications such as adhesions of the cervical and uterine cavity and cervical stenosis. The patient had less bleeding, quick recovery, and short hospital stay, which provided good conditions for the next pregnancy. It could also save money.

On April 3, vaginal bleeding was decreased, and the serum hCG was 9402 mIU/mL. On the same day, a routine blood test showed white blood cells (WBC) count of  $3.77 \times 10E12/L$  and a hemoglobin (Hb) value of 115 g/L.

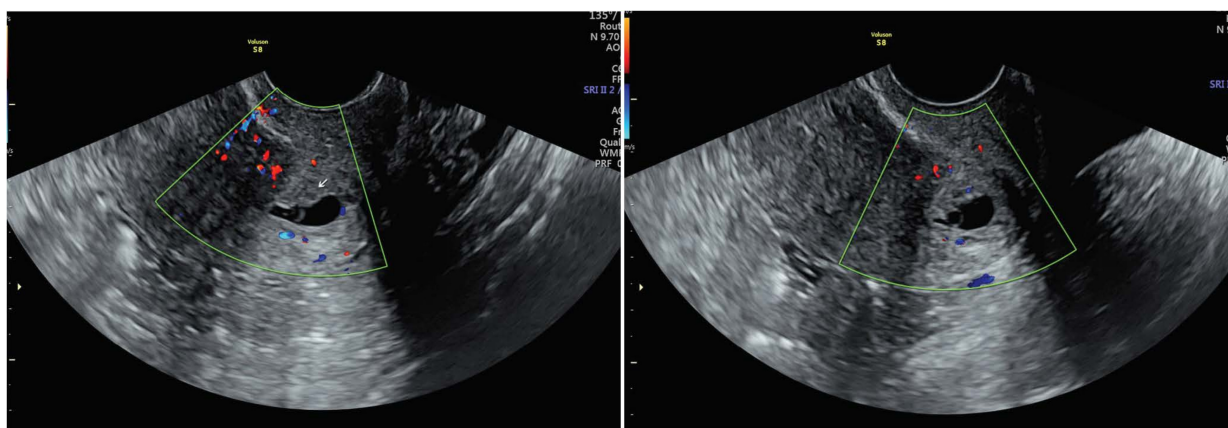
On April 4, the serum hCG was 11666.8 mIU/mL, and a repeat B-mode ultrasound revealed a normal uterine size with endometrium of 0.6 cm. There was no gestational sac in the uterus or lower uterine segment. The cervix had a gestational sac echo of  $1.4 \times 0.6 \times 1.5$  cm. The yolk sac, punctate germ, and heart tube pulsation were seen inside the posterior cervix. The fluid in the recto-uterine pouch was 1.3 cm. These findings indicated cervical pregnancy (Fig. 1). A gynecological examination, which is a routine examination for vaginal bleeding after pregnancy, was performed. It is necessary to rule out bleeding from cervical lesions, incarceration of incomplete abortion in the cervix, or threatened abortion. Careful examination indicated a slightly enlarged and soft cervix, normal uterine size, and no tenderness.

On April 4, under the guidance of B-mode ultrasound, 2 mL of KCL was injected into the gestational sac, and 75 mg of MTX was injected into the cervix. There was less vaginal bleeding after the intervention. The ultrasound scan showed no significant changes in the gestational sac. Observation was recommended.

On April 6, the repeated serum hCG value was 13735 mIU/mL. A routine blood test revealed the following values: WBC,  $3.74 \times 10E12/L$ ; Hb, 110 g/L. The remaining parameters were normal. The high serum hCG values indicated treatment failure.

On April 7, lauromacrogol was injected into the edge of the gestational sac with the guidance of B-mode ultrasound.

On April 8, at 15:00 h, intrauterine visualization and vacuum aspiration were performed under direct vision and negative pressure suction. After the surgery, a Foley bal-



**Fig. 1. Case 1.** Cervical enlargement was noted. Gestational sac size of about  $1.4 \times 0.6 \times 1.5$  cm was found in the cervix, and the heart tube pulsation and punctate germ were seen inside. Cervical pregnancy was diagnosed.

loon was used to compress and stop bleeding. After 6 h, a small amount of light blood fluid was noted in the balloon, and half the amount of the liquid in the balloon was released.

On the second day morning, the Foley catheter was removed. After the operation, B-ultrasound review showed that the cervix was normal in size, and no pregnancy was seen. The patient was followed up for serum hCG on April 9 (4588 mIU/mL), April 15 (335 mIU/mL), and April 22 (6 mIU/L).

### 3.2 Case 2

A 26-year-old female was admitted to our hospital on March 30, 2020, complaining of amenorrhoea for 40 days, followed by vaginal bleeding for 2 days. The medical history indicated a cesarean section in 2015. In 2018, hysteroscopy was performed for removal of residual products of conception after an induced abortion (para 1-0-1-1). The menstrual history suggested the last menstrual period of February 20, 2020, with normal volume and characteristics.

On March 29, the amount of vaginal bleeding after activity was less. On the second day, the amount of vaginal bleeding increased, and it was more than the normal menstruation.

On March 30, the patient was admitted to our hospital. B-mode ultrasound revealed the anterior uterine size; the separable uterine cavity was about 0.22 cm. The cervix had a gestational sac echo of  $1.4 \times 1.0 \times 0.6$ ; the yolk sac was visible inside, and there was a small amount of obvious germ tissue. No obvious primitive cardiovascular fluctuation was noted. The cervical canal was not significantly dilated, and the size of the bilateral ovaries was normal. There was no obvious abnormality in the echo. The anechoic dark area behind the uterus was 1.3 cm thick (Fig. 2). A gynecological examination revealed that the cervix was enlarged, the uterine size was normal, and there was no tenderness.

On March 31, serum hCG was  $>10000$  mIU/L. On the same day, under B-mode ultrasound guidance, lauromacro-

gol was injected into the edge of the gestational sac.

On April 1, intrauterine visualization and vacuum aspiration were performed under direct vision and negative pressure suction. After the surgery, a Foley balloon was used to compress and stop bleeding. After 4 h, a small amount of light bloody liquid was noted in the balloon, and half the amount of liquid in the balloon was released. After 2 h of observation, there was no obvious bleeding in the vagina, and the Foley catheter was removed.

On the next day, a B-ultrasound review after the operation showed that the cervix was normal in size, and no pregnancy was seen. The patient was followed up for serum hCG on April 2 (7468 mIU/L), April 8 (549 mIU/L), and April 15 (9 mIU/L).

## 4. Discussion

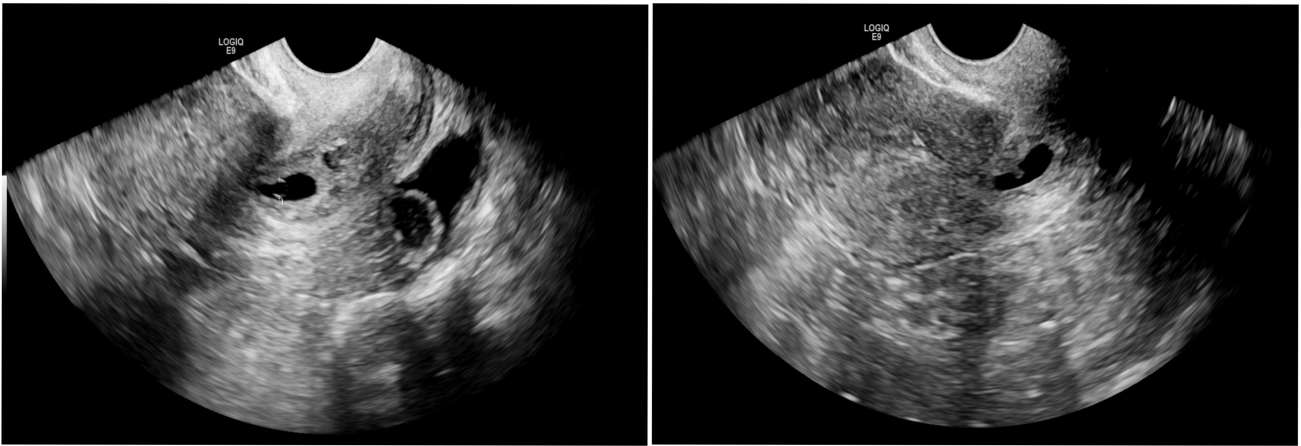
The main symptom of cervical pregnancy is sudden vaginal bleeding or bloody discharge, and the amount of bleeding generally ranges from low to heavy or intermittent massive vaginal bleeding [31]. The purpose of treating cervical pregnancy is to remove the related pregnancy material and control the bleeding of the cervical wound. Both the patients in this study had a relatively shorter pregnancy duration, and the general condition was good at admission.

### 4.1 Causes of cervical pregnancy

The causes may be related to endometrial damage, abnormal uterine environment, rapid transport of fertilized ovum into the endocervical canal, or delayed development.

### 4.2 Diagnostic criteria

The diagnostic criteria include the history of amenorrhoea, painless vaginal bleeding, gynecological examination revealing a normal uterine size, texture that is not soft, pendulous cervix, with or without bluish-purple color, extensible outer cervix, and thin edge, and increased serum hCG. The maximum level of hCG to be considered for the treatment will be determined based on the patient's specific



**Fig. 2. Case 2.** Cervical enlargement was noted. Gestational sac size of about  $1.4 \times 1.0 \times 0.6$  cm was found in the cervix, and the heart tube pulsation and punctate germ were seen inside. Cervical pregnancy was diagnosed.

condition. The current highest hCG level does not exceed 14,000 mIU/mL.

The diagnostic criteria for ultrasound examination include an empty uterine cavity, large cervical canal, visible gestational sac in the cervical canal below the internal os of the cervix, abundant blood flow signals around the gestational sac, occasional heart tube pulsation, closure of the internal os of the cervix [32], and absence of any pregnancy material in the uterine cavity on fractional curettage.

#### 4.3 Reasons for MTX treatment failure

The reasons could be attributed to a gestational age of more than 9 weeks, administration of serum hCG  $>10000$  U/L, and the presence of an ultrasound fetal heart [33,34].

#### 4.4 Different treatment methods in cervical pregnancy and their advantages

There are several treatment methods, and the conventional treatment methods include total hysterectomy, a combination of Mifepristone and MTX, a combination of MTX and hysteroscopy, curettage, and uterine artery embolization. At present, it is confirmed that a combination of drug treatment and intrauterine visualization systems, and vacuum aspiration is an effective treatment. With the advancement of diagnosis and treatment technology, it is possible to employ a conservative treatment to preserve the uterus and fertility in cervical pregnancy [35]. Early gestational trophoblasts do not invade very deep into the cervical wall, and conservative treatment is often very successful. The key to success lies in early diagnosis and early treatment [36,37].

While capturing the nutrition of the embryo, drug treatment also reduces the blood supply to the pregnancy site, thereby avoiding massive vaginal bleeding and causing minimal damage to the patient. One-time intrauterine visualization and vacuum aspiration allow for a clear view of the gestational sac implantation position, and a very accurate

one-time local suction can completely draw the embryo, rendering the treatment complete and thorough. The duration of hospitalization was short. Serum hCG decreased rapidly, and a longer duration of hospital stay for observation was not required. Intraoperative hemorrhage that may occur due to lack of cervical muscle tissue, more muscle fibers, and direct negative pressure vacuum aspiration can be avoided, and the systemic and local side effects of MTX can be reduced. MTX is a chemotherapeutic drug associated with great toxic side effects [33,34] and can cause elevated liver enzymes, bone marrow suppression, and even death.

Hysteroscope electrotony directly damages the cervical fibrous tissue, which easily adheres, causing amenorrhea and abdominal pain. The complications of UAE include postoperative pain, pelvic infection, local tissue necrosis of the bladder and rectum, and amenorrhoea. The incidence rate varies from about 5.7% for intraprocedural complications, 37.3% for minor complications and about 5% for major complications within the first year after UAE [38]. It requires expensive digital imaging technology and involves a high cost, and the most serious complication is pulmonary embolism, which is rare but life-threatening [26]. It may cause uterine endometrium damage and intrauterine ovarian injury, affecting the patient's fertility function to varying degrees [39–41].

In recent years, the clinical application of lauromacrogol in treating esophageal and gastric varices and cesarean uterine scar pregnancy [25,26,34,42] has achieved its therapeutic purposes. Hence, it was chosen in the trial for cervical pregnancy. Before application, the patients and their families were well informed, and signed informed consent was obtained. The limitation of the study is there are relatively few cases at present. Despite this, it is found that compared with other methods, the effect of lauromacrogol is definite and significant, safe and feasible, lower cost, and with fewer side effects. Moreover, the serum hCG



decreased rapidly, the length of hospital stay was short, and patients' recovery was quick. Thus, this method can be generalized within a clinical trial. Hospitals where B-ultrasound and visualization system are available can perform the procedure. Multicenter studies can be carried out if sufficient data are gathered.

Lauromacrogol is a sclerosing foam agent which mainly causes a small area of vascular sclerosis, oppression, and blockage at the local injection site but does not enter the uterine arteriovenous, distant vessels, and ovarian vessels, thereby avoiding damage to the ovaries and allowing the uterus and ovaries to obtain sufficient blood supply [25,43]. Combining this medication with intrauterine visualization system and vacuum aspiration has a definitive therapeutic effect, and the application can be promoted clinically.

### Author contributions

XC, BL, QZ and HC performed the literature search. BL, QZ and HC organized the data. XC wrote the manuscript. TG and MJ provided the clinical supervision. All authors read and approved the final manuscript.

### Ethics approval and consent to participate

This study was approved by the Ethics Committee of Tongde Hospital of Zhejiang Province (KTSC2020311), the patients and their families were well informed and signed informed consent was obtained.

### Acknowledgment

We would like to express our gratitude to all those who helped us during the writing of this manuscript. Thanks to all the peer reviewers for their opinions and suggestions.

### Funding

This work was supported by Zhejiang Public Welfare Technology Research Plan (Grant No. LGF20H040003).

### Conflict of interest

The authors declare no conflict of interest.

### References

- [1] Dziejcz JM, Patel PV. Cervical ectopic pregnancy: a rare site of implantation. *The Journal of Emergency Medicine*. 2019; 56: e123–e125.
- [2] Fylstra DL. Cervical pregnancy: 13 cases treated with suction curettage and balloon tamponade. *American Journal of Obstetrics and Gynecology*. 2014; 210: 581.e1–581.e5.
- [3] Giarenis I, Shenoy J, Morris E. Cervical ectopic pregnancy after endometrial ablation: a case report. *Archives of Gynecology and Obstetrics*. 2008; 277: 567–569.
- [4] Jurkovic D, Hillaby K, Woelfer B, Lawrence A, Salim R, Elson CJ. First-trimester diagnosis and management of pregnancies implanted into the lower uterine segment Cesarean section scar. *Ultrasound in Obstetrics & Gynecology*. 2003; 21: 220–227.
- [5] Hosni MM, Herath RP, Mumtaz R. Diagnostic and therapeutic dilemmas of cervical ectopic pregnancy. *Obstetrical & Gynecological Survey*. 2014; 69: 261–276.
- [6] Winder S, Reid S, Condous G. Ultrasound diagnosis of ectopic pregnancy. *Australasian Journal of Ultrasound in Medicine*. 2011; 14: 29–33.
- [7] Drezett J, Marques D, Ottoboni R, Dzik A, Cavagna M. Cervical ectopic pregnancy after in vitro fertilization: case report successfully treated with cervical electric aspiration. *JBRA Assisted Reproduction*. 2019; 23: 434–438.
- [8] Castillo-Luna R, Zea-Prado F, Torres-Valdez E. Vaginal impingement of uterine arteries (Zea technique) prior to cervical curettage in cervical ectopic pregnancy: three case report and literature review. *Ginecologia y Obstetricia de Mexico*. 2015; 83: 648–655. (In Spanish)
- [9] Bakri YN, Amri A, Abdul Jabbar F. Tamponade-balloon for obstetrical bleeding. *International Journal of Gynaecology and Obstetrics*. 2001; 74: 139–142.
- [10] Saeng-anan U, Sreshthaputra O, Sukpan K, Tongsong T. Cervical pregnancy with massive bleeding after treatment with methotrexate. *BMJ Case Reports*. 2013; 2013: bcr2013200440.
- [11] Wu C, Li Y, Ye W, Ma W, Zhao D. Cook Cervical Ripening Balloon successfully prevents excessive hemorrhage combined with ultrasound-guided suction curettage in the treatment of cesarean scar pregnancy. *The Journal of Obstetrics and Gynaecology Research*. 2017; 43: 1043–1047.
- [12] Zambrano N, Reilly J, Moretti M, Lakhi N. Double balloon cervical ripening catheter for control of massive hemorrhage in a cervical ectopic pregnancy. *Case Report in Obstetrics and Gynecology*. 2017; 2017: 9396075.
- [13] Hirakawa M, Tajima T, Yoshimitsu K, Irie H, Ishigami K, Yahata H, *et al.* Uterine artery embolization along with the administration of methotrexate for cervical ectopic pregnancy: technical and clinical outcomes. *American Journal of Roentgenology*. 2009; 192: 1601–1607.
- [14] Xu B, Wang Y, Zhang Y, Wang S, Yang L, Dai S. Angiographic uterine artery embolization followed by immediate curettage: an efficient treatment for controlling heavy bleeding and avoiding recurrent bleeding in cervical pregnancy. *The Journal of Obstetrics and Gynaecology Research*. 2007; 33: 190–194.
- [15] Lee C, Sacks J, Wong M, Cura M, Shaw C. Uterine artery embolization and potassium chloride injection for treatment of cervical pregnancy. *Journal of Vascular and Interventional Radiology*. 2017; 28: 1756–1758.
- [16] Bianchi P, Salvatori MM, Torcia F, Cozza G, Mossa B. Cervical pregnancy. *Fertility and Sterility*. 2011; 95: 2123.e3–2123.e4.
- [17] Jurkovic D, Ben-Nagi J, Ofilli-Yebovi D, Sawyer E, Helmy S, Yazbek J. Efficacy of Shirodkar cervical suture in securing hemostasis following surgical evacuation of Cesarean scar ectopic pregnancy. *Ultrasound in Obstetrics & Gynecology*. 2007; 30: 95–100.
- [18] Davis LB, Lathi RB, Milki AA, Dahan MH. Transvaginal ligation of the cervical branches of the uterine artery and injection of vasopressin in a cervical pregnancy as an initial step to controlling hemorrhage: a case report. *The Journal of Reproductive Medicine*. 2008; 53: 365–368.
- [19] Trojano G, Colafoglio G, Saliani N, Lanzillotti G, Cicinelli E. Successful management of a cervical twin pregnancy: neoadjuvant systemic methotrexate and prophylactic high cervical cerclage before curettage. *Fertility and Sterility*. 2009; 91: 935.e17–935.e19.
- [20] Hsieh B, Lin Y, Huang L, Chang J, Seow K, Pan H, *et al.* Cervical pregnancy after in vitro fertilization and embryo transfer successfully treated with methotrexate and intracervical injection of vasopressin. *Acta Obstetrica et Gynecologica Scandinavica*. 2004; 83: 112–114.
- [21] Júnior JE, Musiello RB, Araujo Júnior E, Souza E, Fava JL, Guerzet EA, *et al.* Conservative management of cervical preg-

- nancy with embryonic heart activity by ultrasound-guided local injection: an eight case series. *The Journal of Maternal-Fetal & Neonatal Medicine*. 2014; 27: 1378–1381.
- [22] Ishikawa H, Unno Y, Omoto A, Shozu M. Local injection of diluted vasopressin followed by suction curettage for cervical ectopic pregnancy. *European Journal of Obstetrics & Gynecology and Reproductive Biology*. 2016; 207: 173–177.
- [23] Hoellen F, Diedrich K, Dittmer C, Kelling K, Bohlmann MK. Therapeutic management of cervical ectopic pregnancy. *Expert Review of Obstetrics & Gynecology*. 2011; 6: 85–92.
- [24] Murji A, Garbedian K, Thomas J, Cruickshank B. Conservative management of cervical ectopic pregnancy. *Journal of Obstetrics and Gynaecology Canada*. 2015; 37: 1016–1020.
- [25] Chai Z, Yu L, Liu M, Zhu T, Qi F. Evaluation of the efficacy of ultrasound-guided local lauromacrogol injection combined with aspiration for cesarean scar pregnancy: a novel treatment. *Gynecologic and Obstetric Investigation*. 2018; 83: 306–312.
- [26] Wei S, Li D, Zhang Z, Sun W, Jia C. Type II caesarean scar pregnancy management by ultrasound-guided local lauromacrogol injection in combination with suction curettage. *Medicine*. 2020; 99: e19743.
- [27] Liu W, Wang L, Guo C. The effects of lauromacrogol injection into rat endometrial cysts: a preliminary experimental study. *Archives of Gynecology and Obstetrics*. 2016; 294: 555–559.
- [28] Luo X, Ma H, Yu J, Zhao Y, Wang X, Yang L. Efficacy and safety of balloon-occluded retrograde transvenous obliteration of gastric varices with lauromacrogol foam sclerotherapy: initial experience. *Abdominal Radiology*. 2018; 43: 1820–1824.
- [29] Dong Y, Zhou J, Liu Z, Luo T, Zhan W. Efficacy assessment of ultrasound guided lauromacrogol injection for ablation of benign cystic and predominantly cystic thyroid nodules. *Frontiers in Pharmacology*. 2019; 10: 478.
- [30] Idiz UO, Aysan E, Can I, Buyukpinarbasili N, Yardimci EY, Bektasoglu H. The effects of lauromacrogol on thyroid tissue in rabbits. Is this a safe option for the treatment of nodular thyroid disease? *Annali Italiani di Chirurgia*. 2016; 87: 192–197.
- [31] Galvão I A, Gonçalves D, Moreira M, Gonçalves J, Braga J. Cervical pregnancy: different clinical scenarios leading to its diagnosis. *Nascer E Crescer - Birth and growth medical journal*. 2017; 26: 129–132.
- [32] Correia L, Simões M, Luz R, Silva A, Barros C. Cervical ectopic pregnancy: ultrasound diagnosis and conservative management. *Acta Obstetrica e Ginecologica Portuguesa*. 2014; 8: 84–87.
- [33] Bachman EA, Barnhart K. Medical management of ectopic pregnancy. *Clinical Obstetrics & Gynecology*. 2012; 55: 440–447.
- [34] Li M, Zhang Y, Ru R, Wang Q, Xu J, Xu D. Contrast-enhanced ultrasound-assisted lauromacrogol sclerosing therapy as a novel method for treatment of cesarean scar pregnancy. *International Journal of Clinical and Experimental Medicine*. 2017; 10: 4780–4786.
- [35] Singh S. Diagnosis and management of cervical ectopic pregnancy. *Journal of Human Reproductive Sciences*. 2013; 6: 273–276.
- [36] Kirk E, Condous G, Haider Z, Syed A, Ojha K, Bourne T. The conservative management of cervical ectopic pregnancies. *Ultrasound in Obstetrics & Gynecology*. 2006; 27: 430–437.
- [37] Vela G, Tulandi T. Cervical pregnancy: the importance of early diagnosis and treatment. *Journal of Minimally Invasive Gynecology*. 2007; 14: 481–484.
- [38] Fonseca MCM, Castro R, Machado M, Conte T, Girao MJBC. Uterine artery embolization and surgical methods for the treatment of symptomatic uterine leiomyomas: a systemic review and meta-analysis followed by indirect treatment comparison. *Clinical Therapeutics*. 2017; 39: 1438–1455.e2.
- [39] Czuczwar P, Stepniak A, Wrona W, Woźniak S, Milart P, Paszkowski T. The influence of uterine artery embolisation on ovarian reserve, fertility, and pregnancy outcomes—a review of literature. *Przeegląd Menopauzalny*. 2016; 15: 205–209.
- [40] Kanter G, Packard L, Sit AS. Placenta accreta in a patient with a history of uterine artery embolization for postpartum hemorrhage. *Journal of Perinatology*. 2013; 33: 482–483.
- [41] Mara M, Fucikova Z, Kuzel D, Maskova J, Dunder P, Zizka Z. Hysteroscopy after uterine fibroid embolization in women of fertile age. *The Journal of Obstetrics and Gynaecology Research*. 2007; 33: 316–324.
- [42] Ramadan A, Jovanovska RP, Trajkovska M, Andreevski V, Calovska V, Serafimoski V, *et al.* Comparison of argon plasma coagulation and injection therapy with adrenalin and polidocanol in the management of bleeding angiodysplasia in upper gastrointestinal tract. *Prilozi (Makedonska Akademija Na Naukite i Umetnostite. Oddelenie Za Medicinski Nauki)*. 2018; 39: 63–68.
- [43] Xu X, Liu G, He L, Wang C, Zhao X. Effect and safety of ultrasound-guided injection of poly-alcohol on patients with scar pregnancy. *Chinese Journal of Biochemical and Pharmaceutics*. 2017; 37: 165–167.