





Original Research

# Accuracy of office hysteroscopy in the diagnosis of chronic endometritis

Mohamed Elmahdy Abdel Moneim<sup>1,\*</sup>, Amany Abdelbary Abdel Latif<sup>2</sup>,  
Marwa Said Shehata<sup>1</sup>, Ibrahim Abdel Latif Ghanem<sup>1</sup>

<sup>1</sup>Department of Obstetrics and Gynecology, Faculty of Medicine, Alexandria University, 21521 Alexandria, Egypt

<sup>2</sup>Department of Pathology, Faculty of Medicine, Alexandria University, 21521 Alexandria, Egypt

\*Correspondence: [mahdy\\_moh@yahoo.com](mailto:mahdy_moh@yahoo.com) (Mohamed Elmahdy Abdel Moneim)

Academic Editor: Raffaele Tinelli

Submitted: 10 July 2021 Revised: 9 September 2021 Accepted: 10 September 2021 Published: 11 February 2022

## Abstract

**Background:** To test the accuracy of office hysteroscopy in the diagnosis of chronic endometritis (CE) as compared to histopathological diagnosis. **Methods:** This prospective cohort study was conducted in a private hospital from July 2018 to January 2020. 220 infertile women were scheduled for first attempt of intracytoplasmic sperm injection (ICSI). Patients ranging in age from 20–40 with history of primary infertility scheduled for ICSI for the first time were included, while patients with chronic diseases, severe vaginal bleeding, previous failed ICSI, polycystic ovary syndrome (PCOS), or endometriosis were excluded. All patients received postmenstrual office hysteroscopy to rule out the presence of CE; at the same setting, endometrial biopsy was taken and sent for histopathological examination. **Results:** 174 cases (79.1%) were diagnosed as CE at hysteroscopy, while 162 (73.6%) cases were positive at histopathology. 99.4% of the cases presented with hyperaemia, followed by oedema in 74.7% and micro-polypi in 58.6% of cases with CE. There was a significant difference between the hysteroscopic and the histopathologic diagnosis of CE ( $p < 0.001$ ). The sensitivity, specificity, and positive and negative predictive values of hysteroscopy were 93.83%, 62.07%, 87.36% and 78.26% respectively. **Conclusions:** Office hysteroscopic evaluation is relatively accurate on its own but can be further confirmed by CD138 staining.

**Keywords:** ICSI; Office hysteroscopy; Chronic endometritis; CD138; Plasma cells

## 1. Introduction

Uterine factor infertility accounts for approximately 10–15% of infertile couples. Uterine anomalies may be either congenital or acquired [1]. Congenital uterine malformations vary from subtle anomalies such as arcuate uterus to a major anomaly such as Mullerian agenesis. Different classifications for uterine anomalies have been published such as those by the American Fertility Society (1988), European Society of Human Reproduction and Embryology (ESHRE) and the European Society of Gynaecologic Endoscopy (ESGE) in 2013, along with modifications such as American Society of Reproductive Medicine (ASRM) (2016) and Congenital Uterine Malformation by Experts (CUME) classification for arcuate and T-shaped uterus [2–6]. Acquired causes include myometrial lesions as myomas, adenomyosis, adenomyoma and sarcomas. Endometrium may be the cause of infertility as in cases of endometrial polyps, endometrial hyperplasia, chronic endometritis, and endometrial carcinoma. Specific entities in the acquired causes of uterine disease include intrauterine adhesions, abnormal caesarean scar, and scar niche [1].

Chronic endometritis (CE) is a chronic inflammation of the endometrium caused by bacterial infection of the cavity. The most common organisms responsible for this pathology are *Enterococcus faecalis*, *Enterobacteriaceae*, *Gardnerella vaginalis*, *Streptococci*, *Staphylococcus* species and *Mycoplasma*. Sexually transmitted infections,

such as *Chlamydia trachomatis*, *Ureaplasma urealyticum*, and gonorrhoeae are potential causes of the infection [7,8].

CE is asymptomatic in most cases, although it may present with pelvic pain, abnormal uterine bleeding, dyspareunia, and vaginal discharge [9]. While its actual prevalence in the general population is difficult to calculate, researchers estimate it as ranging from 0.8 to 19% [10]. Although CE is asymptomatic, it may account for lower pregnancy rates from both natural and *in vitro* fertilization conceptions; further, it may lead to poor obstetric outcome and neonatal complications [11–17]. CE has been diagnosed in 2.8–39% of women suffering from infertility [14,18,19]. However, prevalence may be as high as 60% in patients with recurrent pregnancy loss or 66% in patients with repeated implantation failure [20]. Diagnosis is difficult due to lack of specific symptoms as well as diagnostic ultrasound findings. Histopathology is diagnostic for CE by the presence of plasma cells in the endometrial stroma. Histopathology often has false positive results when the biopsy is taken in the late luteal or during menstruation [9].

Hysteroscopy is a diagnostic tool for CE [8,20]. Hysteroscopic diagnosis depends on subjective findings observed such as stromal oedema, focal or diffuse hyperaemia, and/or the presence of micropolypi [20]. Treatment of CE may improve *in vitro* fertilization (IVF) success in women with recurrent implantation failure. Endometrial biopsy is recommended to confirm CE diagnosis before initiating IVF cycle [21].



The uterine cavity can be assessed through different techniques such as 3D transvaginal sonography, hysterosalpingogram, and hysteroscopy [22]. Hysterosalpingogram has low specificity, as well as high false-negative and false-positive rates [23]. Anomalies of the uterine cavity can be diagnosed by 3D ultrasound, a tool that exceeds diagnostic hysteroscopy, demonstrating accuracy as high as 90% in diagnosing uterine cavity abnormalities [24,25]. Hysteroscopy enables visual assessment of the cervical canal and uterine cavity for any pathology such as intrauterine adhesions, polyps, grade zero myomas, chronic endometritis, or congenital uterine anomalies that may affect implantation. Hysteroscopy is also a good therapeutic tool in most conditions, while hysteroscopic guided biopsy is more informative about endometrial pathology [26,27]. Two prospective and randomized controlled trials (RCTs) showed improvement in the outcome of assisted reproductive techniques (ART) cycles following office hysteroscopy [28,29] despite lack of definitive pathological diagnosis [30]. On the other hand, a large, randomized study (INSIGHT) found no improvement in the live birth rate after office hysteroscopy before first IVF attempt in cases with normal transvaginal ultrasound [31]. Another study (TROPHY) found no improvement even in cases of previous ART failure [32].

The aim of this study was to test the accuracy of office hysteroscopy in the diagnosis of chronic endometritis as compared to histopathological diagnosis.

## 2. Methods and materials

### 2.1 Study design

Prospective cohort study.

### 2.2 Settings

The study was conducted at a private hospital from July 2018 to January 2020.

### 2.3 Sample size

220 infertile women scheduled for first attempt of intracytoplasmic sperm injection (ICSI).

### 2.4 Participants

We included patients (aged 20–40) with history of primary infertility scheduled for first ICSI. Those with chronic general diseases (immunological, cardiac, D.M, hepatic), severe vaginal bleeding, previous failed ICSI, PCOS women, and endometriosis were excluded.

### 2.5 Methods

This study was approved by the Ethics Committee, Faculty of Medicine, Alexandria University (number: 0304338). The study was conducted in accordance with the Code of Ethics of the World Medical Association (Declaration of Helsinki) for experiments involving humans. The manuscript is in line with the Recommendations for the

Conduct, Reporting, Editing and Publication of Scholarly Work in Medical Journals. Written informed consent for participation in the study and publication of their clinical details and/or clinical images was obtained from each patient. A copy of the consent form is available for review by the Editor of this journal.

All women were subjected to complete history-taking and general examination, vaginal speculum examination, routine laboratory investigations and transvaginal ultrasound. Office hysteroscopy was done by Trophoscope (Storz)®, Tuttlingen, Germany 30° 1.9 mm through vaginoscopic technique. Timing of the procedure was immediately postmenstrual. Distension media used was normal saline. Examination of the cervical canal was performed to exclude cervicitis or any pathology. Uterine cavity was assessed by examining the shape and endometrial pattern, while excluding pathologies. Chronic endometritis was diagnosed by appearance of stromal oedema, focal or diffuse endometrial hyperaemia, and endometrial micropolypi [20].

An endometrial biopsy using a Novak's curette was taken at the time of hysteroscopy and sent for histopathologic examination to confirm the diagnosis. The specimen was preserved in formalin 10%. Specimens were stained with haematoxylin and eosin and then examined for plasma cells. Immunohistochemistry (IHC) was performed for syndecan-1 (CD138) for cases with presence of plasma cells using streptavidin-biotin peroxidase technique. Patients with positive chronic endometritis were treated with doxycycline 100 mg twice daily for 14 days. Endometrial biopsy was taken after one month and sent for histopathologic examination to confirm resolution of the condition before start of ART cycle.

## 3. Statistical analysis of the data [33]

Data were entered and analysed using IBM SPSS software package version 21.0, by SPSS Inc. Chicago, IL, USA [34]. Qualitative data were described using numbers and percentages. Quantitative data were described using range (minimum and maximum), mean, standard deviation and median. Significance of the obtained results was judged at the 5% level.

### 3.1 Chi-square test

For categorical variables, in comparing different groups.

### 3.2 Fisher's exact or Monte Carlo correction

Correction for chi-square when more than 20% of the cells have expected count less than 5.

### 3.3 F-test (ANOVA)

For normally quantitative variables. The test compares between more than two groups. Additionally, Post Hoc test (LSD) was used for pairwise comparisons.

### 3.4 Mann Whitney test

For abnormally quantitative variables, to compare between two study groups.

## 4. Results

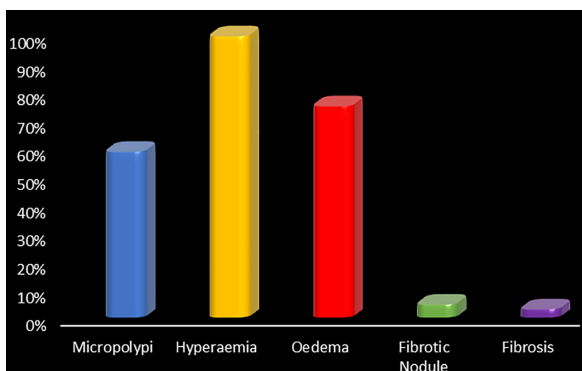
The study was conducted on 220 women with complaints of primary infertility scheduled for the first attempt of ICSI. There was no drop out as the two procedures (office hysteroscopy and endometrial biopsy) were done in the same setting. Patient age ranged from 20–40 years, mean  $29.99 \pm SD 5.10$  years. 174 cases (79.1%) were diagnosed as CE at hysteroscopy (Table 1), while 162 (73.6%) cases were positive at histopathology (Table 2). Fig. 1 shows hyperaemia which was found in 99.4% of the cases of CE, followed by oedema which was present in 74.7% of cases. Micropolyps were found in 58.6% of cases with CE. Fibrotic nodules and fibrosis or filmy adhesions were seen in only 4.6% and 2.9% of cases with CE, respectively. The different hysteroscopic findings are shown in Fig. 2. The sensitivity, specificity, and positive and negative predictive values of hysteroscopy were 93.83%, 62.07%, 87.36% and 78.26%, respectively (Table 3).

**Table 1. Distribution of the studied cases according to hysteroscopic findings.**

| Hysteroscopic findings          | No  | %    |
|---------------------------------|-----|------|
| Negative                        | 46  | 20.9 |
| Positive (chronic endometritis) | 174 | 79.1 |

**Table 2. Distribution of the studied cases according to histopathological findings.**

| Histopathological findings      | No  | %    |
|---------------------------------|-----|------|
| Negative                        | 58  | 26.4 |
| Positive (chronic endometritis) | 162 | 73.6 |



**Fig. 1. Distribution of the hysteroscopic findings in cases of chronic endometritis (n = 220).**

IHC staining of the specimen for cases diagnosed as CE by histopathology showed that 16% of cases were negative for CD138 and 31.5% showed few CD138 cells while 52.5% showed considerable concentration of CD138 (Table 3). Repeating the endometrial biopsy after treatment showed that 22 cases (13.6%) still demonstrated chronic endometritis and 140 cases (86.4%) resolved (Table 3). The distribution of the studied cases according to IHC results is shown in (Table 4). It also shows the result of endometrial biopsy after treatment of endometritis. It was normal in 86.4% of treated cases and 13.6% in persistent cases.

## 5. Discussion

Chronic endometritis is a pathology that is hardly diagnosed via non-invasive approaches. TVS and MRI cannot confirm the diagnosis, while CE can be suspected only in patients with uterine synechia, hydrometra or pyometra. CE is asymptomatic in many cases or may cause mild symptoms such as vaginal spotting, bleeding and vague pelvic pain. The causative pathogen was found to be non-gonococcal, non-chlamydial infections [35].

Cicinelli *et al.* [35] established diagnostic criteria for CE using hysteroscopy. Fluid hysteroscopy is more sensitive than CO<sub>2</sub> hysteroscopy in the detection of CE.; saline does not affect endometrial vascularity and helps endometrial micropolyps to float. The authors' diagnostic criteria for CE included: oedema of endometrial stroma, focal or diffuse endometrial hyperaemia, and micropolyps (<1 mm in size). Stromal oedema plus hyperaemia is a predictor of inflammation. Micropolyps are small, vascularized ingrowths that are covered by inflamed endometrium, and it shows accumulation of inflammatory cells (lymphocytes, plasma cells, or eosinophilic granulocytes) and stromal oedema; there may be an expression of an active inflammatory process of the endometrium and of massive release of interleukins and certain growth factors [36].

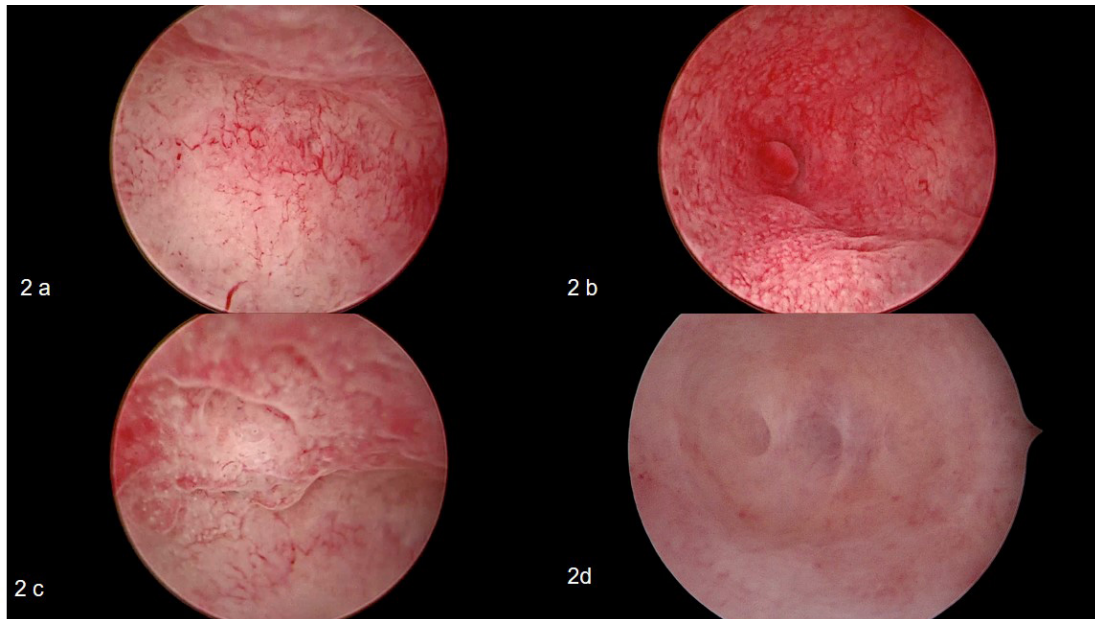
Hysteroscopy has the advantage of direct inspection of the uterine cavity and the detection of signs of inflammation; it may serve as a first choice for diagnosis as it can be done as an outpatient procedure [37]. Unsuspected uterine pathologies have been diagnosed in 11 while 45% of women received hysteroscopy before IVF [38]. Reports have concluded that hysteroscopy in the cycle preceding IVF could be helpful for patients with recurrent implantation failure (RIF) [39]. One of the pathologies that cannot be diagnosed with ultrasound and HSG is chronic endometritis. The gold standard for CE diagnosis is the presence of plasma cells in the endometrial stroma [40]. However, leukocytes that may be found in the endometrium, especially in the luteal phase, must be taken into consideration. Additional research has confirmed that fluid hysteroscopy can diagnose CE reliably based on the presence of diagnostic signs such as micropolyps, stromal oedema and focal or diffuse hyperaemia [7,35].

**Table 3. Relation between hysteroscopic and histopathologic findings (n = 220).**

| Hysteroscopic findings | Histopathologic findings |      |                    |      | Sensitivity | Specificity | PPV   | NPV   |
|------------------------|--------------------------|------|--------------------|------|-------------|-------------|-------|-------|
|                        | Negative (n = 58)        |      | Positive (n = 162) |      |             |             |       |       |
|                        | No                       | %    | No                 | %    |             |             |       |       |
| Negative               | 36                       | 62.1 | 10                 | 6.2  | 93.83       | 62.07       | 87.36 | 78.26 |
| Positive               | 22                       | 37.9 | 152                | 93.8 |             |             |       |       |

$\chi^2$ ,  $p$ :  $\chi^2$  and  $p$  values for Chi square test.

\* Statistically significant at  $p \leq 0.05$ .



**Fig. 2. Different appearance of chronic endometritis during office hysteroscopy.** (a) hypervascularity, (b) micropolyp near right ostia, (c) endometrial oedema and hyperaemia, and (d) endometrial filmy adhesions separated by fluid gush.

**Table 4. Distribution of the studied cases according to IHC and result after treatment (n = 162).**

|                        | Histopathology (n = 162) |      |
|------------------------|--------------------------|------|
|                        | No                       | %    |
| IHC                    |                          |      |
| Few                    | 51                       | 31.5 |
| Negative               | 26                       | 16.0 |
| Considerable           | 85                       | 52.5 |
| Result after treatment |                          |      |
| Normal endometrium     | 140                      | 86.4 |
| Chronic endometritis   | 22                       | 13.6 |

The current study was conducted on 220 patients suffering from infertility, selected from a private infertility clinic. Patient age was 20–40 years, mean  $\pm$  SD  $29.99 \pm 5.10$  years. 174 cases (79.1%) were diagnosed as CE at hysteroscopy, and 162 (73.6%) were positive at histopathology. Following treatment of 162 CE cases, 140 cases (86.4%) resolved, while 22 cases (13.6%) still

showing chronic endometritis. The prevalence of chronic endometritis at hysteroscopy was based on the presence of hyperaemia, oedema and, micropolyps. The criteria on histopathology was based on the presence of plasma cells. The sensitivity, specificity, and positive and negative predictive values of hysteroscopy were 93.83%, 62.07%, 87.36% and 78.26%, respectively.

These results are in line with those of Gebauer *et al.* [37] who found presence of micropolyps in 51 patients in their study group (83 patients) by hysteroscopy. Polyps were diagnosed by endometrial curettage alone in only 43% of these cases. Our results were also supported by Garuti *et al.* [41] who found that hysteroscopy had a high accuracy for the diagnosis of micropolyps (95.3% sensitivity, 95.4% specificity, 98.9% NPV, and 81.7% PPV). The results of the present study demonstrate that diagnosis of absence of inflammation at hysteroscopy is very reliable, while the detection of endometrial hyperaemia, oedema and micropolyps strongly suggests the presence of CE. Our study carries acceptable negative predictive value (78.26%) and a high positive predictive value (87.36%).

Cicinelli *et al.* [35] found that 88.6% of patients with positive findings at hysteroscopy were histologically positive for CE, but in our study, 93.48% of them were positive histologically. Our results disagree with those of other researchers who concluded that hysteroscopy is not useful for screening chronic endometritis in asymptomatic infertile women. The rationale for their conclusion assumed that incidence of chronic endometritis in the population is 10%, such that a negative predictive value of 89.1% added no additional tools for risk assessment for CE. However, these researchers used CO<sub>2</sub> and not fluid hysteroscopy; furthermore, the prevalence of chronic endometritis in 10% of infertile women is significantly lower than that reported by most authors [14].

Micropolypi characterized by the presence of inflammatory cells and stromal oedema are likely the expression of an active inflammatory reaction and release of interleukins and certain growth factors [36]. Micropolyps were demonstrated in 58.5% of cases with CE. Other researchers demonstrate that there is a clear correlation between different signs of CE at hysteroscopy and severity of inflammation at histopathology. Our research reveals that there is a good correlation between hysteroscopic and histological evaluation of CE. Previous studies demonstrate that the presence of micropolyps is a reliable sign of inflammation and that this sign has a high positive predictive value [35]. The presence of micropolyps is proportionate to the severity of inflammation, to the severity of mucosal injury and to an abnormal stimulus in the endometrium. Leucocytic infiltration in chronic endometritis is not only a quantitative but also a qualitative variation in infiltration by leucocytes. It exists as an abnormal distribution of endometrial lymphocyte [42].

Micropolypi are minute in size; detection of these minor lesions is easier when saline is used for distention as it allows the micropolyps to float. On the contrary, when using CO<sub>2</sub>, micropolypi are flattened against the endometrial surface. The continuous washing of the uterine cavity keeps the subject visually clear in the presence of mucus or bleeding that are frequently present with endometrial inflammation [43]. Moreover, CO<sub>2</sub> provokes an abrupt distention of the endometrial cavity and induces dilatation of capillaries. Petechiae and micro-haemorrhages may therefore occur within the endometrium, rendering diagnosis of endometritis less reliable [43].

Limitations of this study are that CE is a subtle pathology during hysteroscopic examination, and thus requires time to identify such cases. Some hysteroscopic pictures such as hyperaemia and oedema may be present in other pathologies like endometrial hyperplasia which may be seen in PCOS patients seeking fertility.

## 6. Conclusions

Office hysteroscopic evaluation is relatively accurate on its own but can be further confirmed by CD138 staining.

## Author contributions

MA did the hysteroscopic examination and took the endometrial biopsy, and analysed and interpreted the patient data regarding the studied parameters. IG and MS contributed in the recruitment of the cases, as well as follow-up and data analysis. AA was responsible for histopathologic examination of the biopsies. MA and MS contributed in writing the manuscript. All authors read and approved the final manuscript and agree for publication.

## Ethics approval and consent to participate

This study was approved from the Ethics committee, faculty of medicine, Alexandria university (number 0304338). Informed consent was taken from all women recruited in the study, that they accept to go through the study and they agree publishing the medical data and the hysteroscopic images in medical journals.

## Acknowledgment

The authors wish to acknowledge the gynaecology outpatient clinic staff for their assistance.

## Funding

This research received no external funding.

## Conflict of interest

The authors declare no conflict of interest.

## References

- [1] Hur C, Rehmer J, Flyckt R, Falcone T. Uterine Factor Infertility: a Clinical Review. *Clinical Obstetrics & Gynecology*. 2019; 62: 257–270.
- [2] The American Fertility Society classifications of adnexal adhesions, distal tubal occlusion, tubal occlusion secondary to tubal ligation, tubal pregnancies, müllerian anomalies and intrauterine adhesions. *Fertility and Sterility*. 1988; 49: 944–955.
- [3] Grimbizis GF, Gordts S, Di Spiezo Sardo A, Brucker S, De Angelis C, Gergolet M, *et al.* The ESHRE/ESGE consensus on the classification of female genital tract congenital anomalies. *Human Reproduction*. 2013; 28: 2032–2044.
- [4] Pfeifer S, Butts S, Dumesic D, Gracia C, Vernon M, Fossum G, *et al.* Uterine septum: a guideline. *Fertility and Sterility*. 2016; 106: 530–540.
- [5] Ludwin A, Martins WP, Nastri CO, Ludwin I, Coelho Neto MA, Leitão VM, *et al.* Congenital Uterine Malformation by Experts (CUME): better criteria for distinguishing between normal/arcuate and septate uterus? *Ultrasound in Obstetrics & Gynecology*. 2018; 51: 101–109.
- [6] Ludwin A, Coelho Neto MA, Ludwin I, Nastri CO, Costa W, Acien M, *et al.* Congenital Uterine Malformation by Experts (CUME): diagnostic criteria for T-shaped uterus. *Ultrasound in Obstetrics & Gynecology*. 2020; 55: 815–829.
- [7] Cicinelli E, De Ziegler D, Nicoletti R, Colafiglio G, Saliani N, Resta L, *et al.* Chronic endometritis: correlation among hysteroscopic, histologic, and bacteriologic findings in a prospective trial with 2190 consecutive office hysteroscopies. *Fertility and Sterility*. 2008; 89: 677–684.
- [8] Cicinelli E, De Ziegler D, Nicoletti R, Tinelli R, Saliani N, Resta L, *et al.* Poor Reliability of Vaginal and Endocervical Cultures

- for Evaluating Microbiology of Endometrial Cavity in Women with Chronic Endometritis. *Gynecologic and Obstetric Investigation*. 2009; 68: 108–115.
- [9] Greenwood SM, Moran JJ. Chronic endometritis: morphologic and clinical observations. *Obstetrics and Gynecology*. 1981; 58: 176–184.
- [10] Farooki MA. Epidemiology and pathology of chronic endometritis. *International Surgery*. 1967; 48: 566–573.
- [11] Romero R, Mazor M. Infection and preterm labor. *Clinical Obstetrics and Gynecology*. 1988; 31: 553–584.
- [12] Taylor S, Frydman R. Hysteroscopy and sperm infection. *Contraception, Fertilite, Sexualite*. 1996; 24: 549–551. (In French)
- [13] Gravett MG, Hitti J, Hess DL, Eschenbach DA. Intrauterine infection and preterm delivery: evidence for activation of the fetal hypothalamic-pituitary-adrenal axis. *American Journal of Obstetrics and Gynecology*. 2000; 182: 1404–1413.
- [14] Féghali J, Bakar J, Mayenga JM, Ségard L, Hamou J, Driguez P, *et al*. Systematic hysteroscopy prior to in vitro fertilization. *Gynecologie, Obstetrique & Fertilite*. 2003; 31: 127–131.
- [15] Espinoza J, Erez O, Romero R. Preconceptional antibiotic treatment to prevent preterm birth in women with a previous preterm delivery. *American Journal of Obstetrics and Gynecology*. 2006; 194: 630–637.
- [16] Knudtson EJ, Shellhaas C, Stephens JA, Senokozlieff M, Ye H, Iams JD. The association of chronic endometritis with preterm birth. *American Journal of Obstetrics and Gynecology*. 2007; 196: 337.e1–337.e4.
- [17] Kitaya K, Matsubayashi H, Yamaguchi K, Nishiyama R, Takaya Y, Ishikawa T, *et al*. Chronic Endometritis: Potential Cause of Infertility and Obstetric and Neonatal Complications. *American Journal of Reproductive Immunology*. 2015; 75: 13–22.
- [18] Polisseni F, Bambirra EA, Camargos AF. Detection of chronic endometritis by diagnostic hysteroscopy in asymptomatic infertile patients. *Gynecologic and Obstetric Investigation*. 2003; 55: 205–210.
- [19] Oliveira FG, Abdelmassih VG, Diamond MP, Dozortsev D, Nagy ZP, Abdelmassih R. Uterine cavity findings and hysteroscopic interventions in patients undergoing in vitro fertilization-embryo transfer who repeatedly cannot conceive. *Fertility and Sterility*. 2003; 80: 1371–1375.
- [20] Cicinelli E, Matteo M, Tinelli R, Lepera A, Alfonso R, Indraccolo U, *et al*. Prevalence of chronic endometritis in repeated unexplained implantation failure and the IVF success rate after antibiotic therapy. *Human Reproduction*. 2015; 30: 323–330.
- [21] Vitagliano A, Saccardi C, Noventa M, Di Spiezio Sardo A, Sacccone G, Cicinelli E, *et al*. Effects of chronic endometritis therapy on in vitro fertilization outcome in women with repeated implantation failure: a systematic review and meta-analysis. *Fertility and Sterility*. 2018; 110: 103–112.e1.
- [22] Phillips CH, Benson CB, Ginsburg ES, Frates MC. Comparison of uterine and tubal pathology identified by transvaginal sonography, hysterosalpingography, and hysteroscopy in female patients with infertility. *Fertility Research and Practice*. 2015; 1: 20.
- [23] Taşkın EA, Berker B, Ozmen B, Sönmezer M, Atabekoğlu C. Comparison of hysterosalpingography and hysteroscopy in the evaluation of the uterine cavity in patients undergoing assisted reproductive techniques. *Fertility and Sterility*. 2011; 96: 349–352.e2.
- [24] Grigore M, Pristavu A, Iordache F, Gafitanu D, Ursulescu C. Comparative Study of Hysteroscopy and 3D Ultrasound for Diagnosing Uterine Cavity Abnormalities. *Revista Medico-Chirurgicala a Societatii De Medici Si Naturalisti Din Iasi*. 2016; 120: 866–873.
- [25] Saravelos SH, Jayaprakasan K, Ojha K, Li T. Assessment of the uterus with three-dimensional ultrasound in women undergoing ART. *Human Reproduction Update*. 2017; 23: 188–210.
- [26] El-Toukhy T, Sunkara SK, Coomarasamy A, Grace J, Khalaf Y. Outpatient hysteroscopy and subsequent IVF cycle outcome: a systematic review and meta-analysis. *Reproductive BioMedicine Online*. 2008; 16: 712–719.
- [27] Gao M, Sun Y, Xie H, Fang S, Zhao X. Hysteroscopy prior to repeat embryo transfer may improve pregnancy outcomes for asymptomatic women with repeated implantation failure. *The Journal of Obstetrics and Gynaecology Research*. 2015; 41: 1569–1576.
- [28] Demiroglu A, Gurgan T. Effect of treatment of intrauterine pathologies with office hysteroscopy in patients with recurrent IVF failure. *Reproductive Biomedicine Online*. 2004; 8: 590–594.
- [29] Rama Raju GA, Shashi Kumari G, Krishna KM, Prakash GJ, Madan K. Assessment of uterine cavity by hysteroscopy in assisted reproduction programme and its influence on pregnancy outcome. *Archives of Gynecology and Obstetrics*. 2006; 274: 160–164.
- [30] Shawki HE, Elmorsy M, Eissa MK. Routine office hysteroscopy prior to ICSI and its impact on assisted reproduction program outcome: a randomized controlled trial. *Middle East Fertility Society Journal*. 2012; 17: 14–21.
- [31] Smit JG, Kasius JC, Eijkemans MJC, Koks CAM, van Golde R, Nap AW, *et al*. Hysteroscopy before in-vitro fertilisation (in-SIGHT): a multicentre, randomised controlled trial. *The Lancet*. 2016; 387: 2622–2629.
- [32] El-Toukhy T, Campo R, Khalaf Y, Tabanelli C, Gianaroli L, Gordts SS, *et al*. Hysteroscopy in recurrent in-vitro fertilisation failure (TROPHY): a multicentre, randomised controlled trial. *The Lancet*. 2016; 387: 2614–2621.
- [33] Kim JJ, Choi YM, Chae SJ, Hwang KR, Yoon SH, Kim MJ, *et al*. Vitamin D deficiency in women with polycystic ovary syndrome. *Clinical and Experimental Reproductive Medicine*. 2014; 41: 80–85.
- [34] Hahn S, Haselhorst U, Tan S, Quadbeck B, Schmidt M, Roesler S, *et al*. Low serum 25-hydroxyvitamin D concentrations are associated with insulin resistance and obesity in women with polycystic ovary syndrome. *Experimental and Clinical Endocrinology & Diabetes*. 2006; 114: 577–583.
- [35] Cicinelli E, Resta L, Nicoletti R, Tartagni M, Marinaccio M, Bulletti C, *et al*. Detection of chronic endometritis at fluid hysteroscopy. *Journal of Minimally Invasive Gynecology*. 2007; 12: 514–518.
- [36] Romero R, Espinoza J, Mazor M. Can endometrial infection/inflammation explain implantation failure, spontaneous abortion, and preterm birth after in vitro fertilization? *Fertility and Sterility*. 2004; 82: 799–804.
- [37] Gebauer G, Hafner A, Siebzehrübl E, Lang N. Role of hysteroscopy in detection and extraction of endometrial polyps: results of a prospective study. *American Journal of Obstetrics and Gynecology*. 2001; 184: 59–63.
- [38] Fatemi HM, Kasius JC, Timmermans A, van Disseldorp J, Fauser BC, Devroey P, *et al*. Prevalence of unsuspected uterine cavity abnormalities diagnosed by office hysteroscopy prior to in vitro fertilization. *Human Reproduction*. 2010; 25: 1959–1965.
- [39] Fatemi HM, Popovic-Todorovic B. Implantation in assisted reproduction: a look at endometrial receptivity. *Reproductive BioMedicine Online*. 2013; 27: 530–538.
- [40] Kasius JC, Fatemi HM, Bourgain C, Sie-Go DMDS, Eijkemans RJC, Fauser BC, *et al*. The impact of chronic endometritis on reproductive outcome. *Fertility and Sterility*. 2011; 96: 1451–1456.
- [41] Garuti G, Sambruni I, Colonnelli M, Luerti M. Accuracy of hysteroscopy in predicting histopathology of endometrium in 1500

women. *The Journal of the American Association of Gynecologic Laparoscopists*. 2001; 8: 207–213.

- [42] Matteo M, Cicinelli E, Greco P, Massenzio F, Baldini D, Falagario T, *et al.* Abnormal pattern of lymphocyte subpopulations in the endometrium of infertile women with chronic endometritis. *American Journal of Reproductive Immunology*. 2009; 61:

322–329.

- [43] Cicinelli E, Parisi C, Galantino P, Pinto V, Barba B, Schonauer S. Reliability, feasibility and safety of mini-hysteroscopy with vaginoscopic approach: experience with 6000 cases. *Fertility and Sterility*. 2003; 80: 199–202.