

Oophoropexy to prevent adnexal torsion recurrence in children

Jian-Sheng Wei^{1,*}, Min-Yan Zhang¹, Shen Liu¹, Kang Li¹, Jun-Jie Fu¹, Peng Lin¹

¹Department of Pediatric Urology, Fuzhou Children's Hospital, 350001 Fuzhou, Fujian, China

*Correspondence: fjetyylwfb@126.com (Jian-Sheng Wei)

DOI:10.31083/j.ceog4805175

This is an open access article under the CC BY 4.0 license (<https://creativecommons.org/licenses/by/4.0/>).

Submitted: 11 January 2021 Revised: 06 February 2021 Accepted: 02 March 2021 Published: 15 October 2021

Background: Adnexal torsion in Children is a rare event, and oophoropexy for the prevention of adnexal torsion in children is still controversial. The aim of this study was to analyze how retorsion can be prevented. **Method:** We performed a retrospective review of hospital charts of all patients aged 0–18 years with a diagnosis of adnexal torsion at the fuzhou Children's Hospital at Fujian province, from august 2014 to august 2019. **Result:** In total, 10 patients were included in the study. The average age of the patients was 5.5 years (range: 2 months–10 years). Clinical presentation: included pain (n = 9), vomiting (n = 3), and abdominal mass (n = 1). Surgical procedures included: laparoscopy (LP): cystectomy with detorsion (n = 5); cyst aspiration with detorsion (n = 1), and detorsion with oophoropexy (n = 2). One case underwent salpingo-oophorectomy LP (n = 1), which was converted to open laparotomy Sappingo-oophorectomy. Recurrence occurred in two cases. Case 5 had recurrent adnexal torsion after oophoropexy with absorbable suture. The second episode was treated with oophoropexy with non-absorbable suture and multiple points fixed. During the operation, the right ovarian ligament was longer, and hypermobile. Case 6 had recurrent cyst aspiration and the second episode was treated with cystectomy with oophoropexy. During the operation, the ovarian ligament was hypermobile. Follow-up: ultrasound showed normal ipsilateral adnexal, and no ovarian atrophy in eight patients. **Conclusion:** The recurrence of ovarian torsion in children may be caused by ovarian etiology and abnormal ovarian ligaments. Oophoropexy can prevent ovarian retorsion with non-absorbable sutures and multiple points fixed.

Keywords

Adnexal torsion; Children; Oophoropexy; Recurrence

1. Introduction

Adnexal torsion (AT) involves the twisting of all adnexal components (fallopian tube and ovary) causing an impairment of blood flow. AT has a reported prevalence of 2.7% and incidence of 4.9 per 100,000 women <20 years old [1, 2]. The diagnosis of AT should be considered in women presenting with acute abdominal pain [2]. Early diagnosis and treatment are important, especially during childhood, as torsion can otherwise result in organ loss, adverse effects on pubertal development, and infertility. In the last decade, conservative management has been accepted by most scholars [3]. Increasing rates of ovarian conservation are invariably asso-

ciated with the risk of recurrent torsion. This risk can be further stratified according to the patient's menarchal status and underlying adnexal pathology. These features highlight the need to prevent further torsion events of the ipsilateral and contralateral adnexa in women at risk of recurrent torsion [4]. Prophylactic oophoropexy is still controversial regarding the indications and preferred surgical technique [5], because of the lack of relevant literature. In this study, the indications and technical details of oophoropexy were assessed in pediatric patients.

2. Materials and methods

We performed a retrospective review of hospital charts of all patients aged 2 months–18 years with a diagnosis of ovarian torsion at Fuzhou Children's Hospital in Fujian Province from August 2014 to August 2019. Patients were excluded if they were >18 years old or had an ovarian lesion but not torsion. A total of 10 patients were included. Patients were identified by their indication for surgery in the surgical database. Patient demographics, clinical presentation, diagnostic imaging, surgical procedure, pathology, second surgical procedure, and follow-up were reviewed (Table 1). We performed surgical intervention using the Pfannenstiel approach in case 1. Initially, the torsed ovary was detorsed. After necrosis was established, oophorectomy was performed. The other 9 patients underwent laparoscopy, except for case 9, which was converted to open laparotomy, the tumor was large and borderless intraoperatively, oophorectomy was performed. Laparoscopic procedure: the first trocar was introduced through a small transumbilical incision under direct visual control. Two 5-mm trocars were introduced through a lateral rectus incision or in each iliac flank, the torted ovary was detorsed initially, cystectomy (Fig. 1) with/or oophoropexy was performed according to the intraoperative situation. All patients were followed up by ultrasound at three months postoperatively and yearly thereafter. Follow-up included clinical symptoms; the bilateral ovary size and blood supply by Doppler ultrasound. This study was approved by the Institutional Ethics Committee of Fuzhou children's Hospital in Fujian Province (FCHFJ-2020-24).

Table 1. Case characteristics.

Case #	Age (years)	Clinical presentation	Diagnostic imaging	Surgical procedure	Pathology	Second surgical procedure	Follow-up(years)
1	0.2	Vomiting irritability distension	US: L (5.3 × 4.0 cm), ascites (-), color Doppler blood flow (-)	OP, Sappingo-oophorectomy	Ovarian cyst with hemorrhagic necrosis	-	3 y, US: normal contralateral ovary
2	2.3	Pain, vomiting	US: L (4.2 × 3.5 cm), ascites (+), color Doppler blood flow (-)	LP, cystectomy with detorsion	Mature teratoma	-	6 y, US: normal
3	5	Right lower quadrant pain	US: R (5.5 × 4.8 cm), ascites (+), color Doppler blood flow (+), CT: enlarged ovary, cyst	LP, cystectomy with detorsion	Simple ovarian cyst	-	5 y, US: normal
4	5.3	Right lower quadrant pain	US: R (5.4 × 4.0 cm), ascites (-), color Doppler blood flow (-)	LP, cystectomy with detorsion	Mature teratoma	-	4 y, US: normal
5	8	Right lower quadrant pain, vomiting	US: Right enlarged ovary, ascites (+), color Doppler blood flow (-), CT: enlarged ovary	LP, detorsion with oophoropexy (non-absorbable sutures and multi-point fixation to the back of the uterus)	-	LP, detorsion with oophoropexy (non-absorbable sutures and multi-point fixation to the back of the uterus)	1.3 y, US: normal
6	10	Right lower quadrant pain	US: Right enlarged ovary, ascites (+), color Doppler blood flow (-), CT: enlarged ovary	LP, detorsion with oophoropexy (non-absorbable sutures and multi-point fixation to the back of the uterus)	-	-	2 y, US: normal
7	7	Pain	US: R (4 × 6 cm), ascites (+), color Doppler blood flow (+)	LP, detorsion with aspiration cyst	Second episode: simple ovarian cyst	LP, cystectomy with detorsion and oophoropexy (non-absorbable sutures and multi-point fixation to the back of the uterus)	2 y, US: ipsilateral ovary smaller than the contralateral one, but blood flow normal
8	5.5	Pain, vomiting	US: L (7.2 × 5.4 cm), ascites (-), color Doppler blood flow (-)	LP, cyst aspiration with cystectomy and detorsion	Mature teratoma	-	5 y, US: normal
9	9	Pain, abdominal mass	US: R (10.0 × 7.3 cm), ascites (-), color Doppler blood flow (+), CT: ovarian mass	LP converted to OP, Sappingo-oophorectomy	Mature teratoma with hemorrhagic necrosis	-	2 y, US: normal contralateral ovary
10	3.4	Pain	US: R (5.5 × 4.5 cm), ascites (-), color Doppler blood flow (-)	LP, cystectomy with detorsion	Mature teratoma	-	2 y, US: normal

(-), absent; (+), detection; LP, laparoscopy; OP, Open laparotomy; US, ultrasonography.

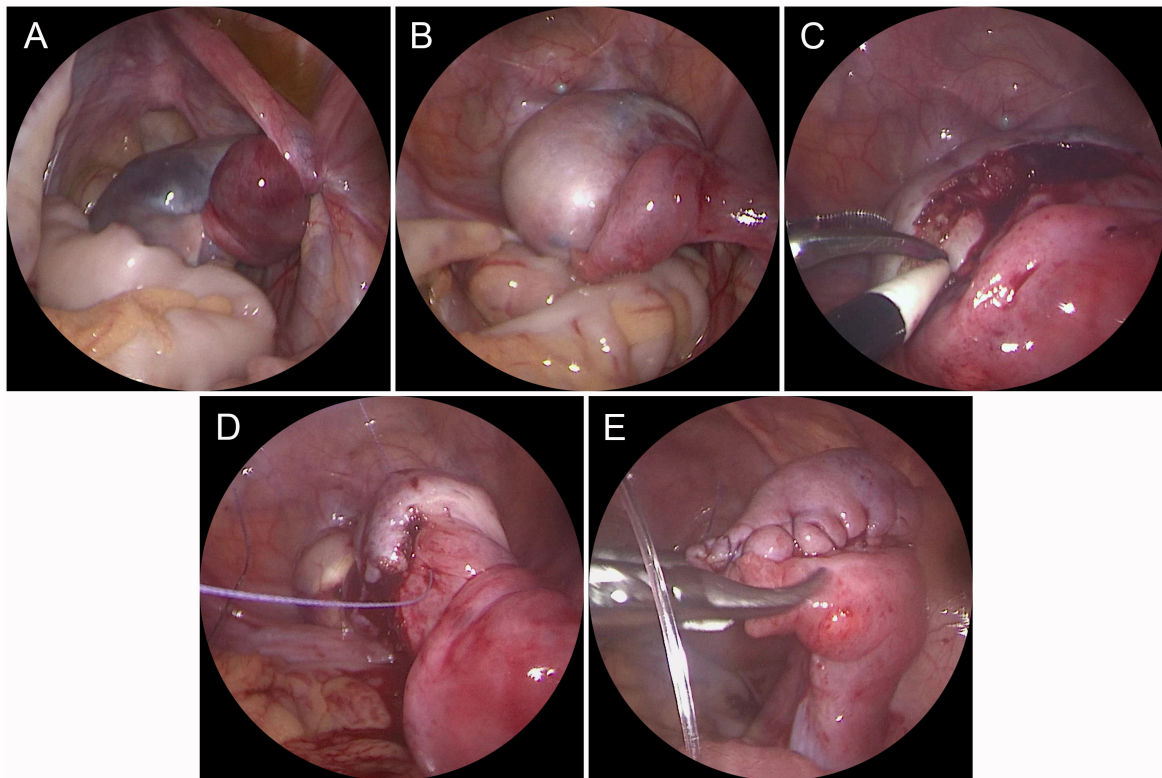


Fig. 1. Case 10 surgical procedure. (A) Right ovarian torsion (720°), the ovarian appearance blue-black. (B) After retorsion, the ovarian turn red, a mass at one pole of the ovarian. (C) The ovarian parenchyma was incised and the tumor was removed. (D) The ovarian sutured with 4-0 absorbable suture. (E) The appearance of the ovary after suture.

3. Results

Ten pediatric patients with AT were enrolled in this study. The mean (range) age of patients was 5.5 (0.2–10) years. All patients had a premenarchal status, and two patients experienced recurrent torsion. Clinical presentation included pain ($n = 9$), vomiting ($n = 3$), and abdominal mass ($n = 1$). Patients were divided into four groups based on their first surgical procedure: cystectomy with detorsion ($n = 5$); cyst aspiration with detorsion ($n = 1$); detorsion with oophoropexy ($n = 2$); and salpingo-oophorectomy ($n = 2$) (Table 1).

Overall, two patients had recurrence. Case 5 was a 10-year-old female with premenarchal status. Her first surgical procedure involved LP, detorsion with oophoropexy, and single-points fixation to the back of the uterus using absorbable sutures (Fig. 2A). No postoperative complications were observed and she was discharged four days postoperatively. Six months later, the patient complained of acute lower quadrant pain after mountain-climbing. Her parents brought the child to our attention again. Pre-operative ultrasound showed an enlarged right ovary, and color Doppler ultrasound did not detect a vascular signal. Therefore, the patient underwent an emergency laparoscopy. A 360° right twisted ovary was found (Fig. 2B). After detorsion, the right ovary was hypermobile with elongated ligaments (Fig. 2C). Laparoscopic ovarian detorsion and right ovarian fixation of multiple points to the back of the uterus with non-absorbable

sutures were performed (Fig. 2D). After oophoropexy, right ovarian fixation was good (Fig. 2E). Case 6 was another case of ovarian torsion without mass, and non-absorbable sutures and multiple fixed points were used in the first surgical oophoropexy. The postoperative period was uneventful. After two years of follow-up, no recurrence was noted.

Case 7 was a seven-year-old female who complained of acute right lower quadrant pain. Ultrasound showed a right adnexal mass ($4.0 \text{ cm} \times 6.0 \text{ cm}$). The patient underwent an emergency laparoscopy. Her first surgical procedure involved detorsion with cyst aspiration, because the cyst had no obvious boundary. The postoperative period was uneventful, and she was discharged four days postoperatively. However, about two months later, she presented with recurrence. Ultrasound showed an adnexal cyst mass larger than before, and color Doppler ultrasound did not detect vascular signals. The patient's second surgical procedure was cystectomy with detorsion and oophoropexy, using 4-0 non-absorbable sutures and multi-point fixation to the back of the uterus. The postoperative period was uneventful. After two years of follow-up, no recurrence was observed, and the ipsilateral ovarian size was smaller than the contralateral one, but blood flow on color Doppler ultrasound was normal.

The average follow-up was 54.3 months. Ultrasound showed normal ipsilateral adnexal, and no ovarian atrophy was observed in eight patients.

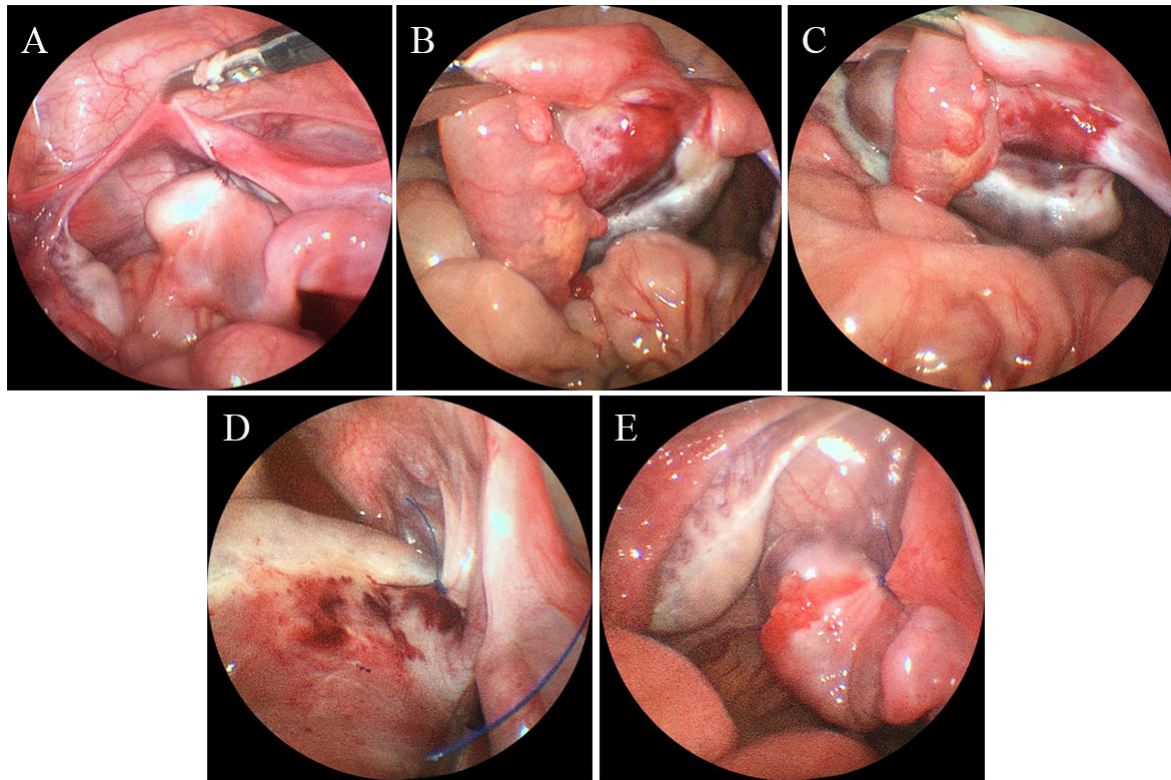


Fig. 2. Case 5 surgical procedure. (A) Ovarian fixation to the back of the uterus using absorbable sutures and single-point fixation. (B) The same patient underwent a second surgery due to ovarian torsion (360°). The ovarian appearance was blue-black. (C) After detorsion, the right ovarian ligament was hypermobile and elongated. (D) Ovarian fixation to the back of the uterus using non-absorbable sutures and multiple points fixed. (E) After oophoropexy, right ovarian fixation was good.

4. Discussion

In the present study, 10 children were enrolled, and the proportion of ovaries preserved reached 80%. A total of three children underwent oophoropexy. There were two cases of normal ovarian appearance and oophoropexy performed in the first operation. Recurrence occurred in case 5. In the second operation, we observed the original fixed sutures disappear and considered recurrence to be due to absorbable suture use and single-point fixation. Therefore, for case 6, we performed oophoropexy with non-absorbable sutures and multi-point fixation for the second operation. The postoperative effect was good, and there was no recurrence. Therefore, we suggest that oophoropexy should be performed with non-absorbable sutures and multi-point fixation in the first operation for children with normal ovarian appearance.

Many articles have shown that oophoropexy is beneficial in preventing ovarian torsion. Yaniv [6] concluded that longer ovarian ligaments may correlate with the development of ovarian torsion, similar to what we observed during surgery. Bertozzi *et al.* [7] suggested that oophoropexy should be performed at the first episode of torsion to eliminate the possibility of recurrence, which is consistent with our point of view. The guidelines [2] recommend that oophoropexy be considered in situations where the ovarian ligaments are congenitally long, patients have repeat torsion,

or when no obvious cause for the torsion can be found; however, the technical details of oophoropexy in pediatric population was no mentioned. Lucchetti *et al.* [8] also stated that oophoropexy should be performed with permanent sutures because absorbable sutures may completely disappear without any residual scar, which was observed in our study in case 5. Fuchs *et al.* [4] reported one case of torsion recurrence 14 months after suturing of the ovary to the lateral pelvic sidewall with an absorbable suture. He stated that non-absorbable sutures can be used regardless which technique is chosen; however, multi-point fixation was not discussed. From the mechanical perspective, the fixation of ≥ 3 points can make the object is more firmly fixed and not easy to twist. Our findings support this point of view, as the children who underwent multi-point fixation in our study achieved good results after surgery.

In the present study, five patients (50%) had an ovarian mass, similar to previous reports [9]. All masses were larger than 5 cm and benign (5 teratomas and 3 simple cysts). Oltmann *et al.* [10] demonstrated a strong association of torsion with pelvic masses larger than 5 cm. The mechanism of torsion in women and girls with benign ovarian masses is likely related to the increased size and weight of the involved ovary [11]. Tsafirir [12] conducted an 11-year retrospective analysis of 216 cases of ovarian torsion and found that performing

cyst drainage or cystectomy significantly reduced the chance of retorsion by 50% and 75%, respectively. In case 7 of our series, recurrence was observed two months after cyst aspiration and successfully treated with a second laparoscopy cystectomy, which confirms that removal of the etiology is effective in preventing ovarian torsion recurrence. However, it is often difficult to determine whether there is a discrete cyst, because the ovary is edematous, some authors have suggested delaying cystectomy for 6–8 weeks after edema resolution [13, 14]. Therefore, we think close postoperative monitoring is particularly important. Childress [1] also suggested that surveillance ultrasounds should be performed every three months after surgery and then every 6 months to a year for long-term surveillance.

The study's limitations include its retrospective design and the small number of AT cases because of its low morbidity. In the future, a multicenter study will be more useful in improving the awareness regarding AT.

5. Conclusions

The results of the current study indicated that the two main risk factors for AT were ovarian pathology and elongation and hypermobility of the ovarian ligament. Therefore, reductions in pathological indications and performing oophoropexy with non-absorbable sutures and multi-point fixation to restore normal appearance can help prevent retorsion.

Author contributions

JW: project design, data acquisition and analysis, and manuscript writing. PL: project design, data analysis, and manuscript editing. MZ: data acquisition and analysis. SL: data acquisition and analysis. KL: data acquisition and analysis. JF: data acquisition and analysis. All authors contributed to editorial changes in the manuscript. All authors read and approved the final manuscript.

Ethics approval and consent to participate

This study was approved by the Ethics Committee of the Fuzhou Children's Hospital in Fujian Province and was performed in accordance with the principles laid down in the Declaration of Helsinki (FCHFJ-2020-24). Preoperative informed consent was signed in all cases.

Acknowledgment

The authors are grateful to the staff of Fuzhou Children's Hospital in Fujian Province, who were responsible for the management of patients included in the study.

Funding

Sponsored by the key Clinical Specialty Discipline Construction Program of Fuzhou, Fujian, China (2018-56).

Conflict of interest

The authors declare no conflict of interest.

References

- [1] Childress KJ, Dietrich JE. Pediatric ovarian torsion. *Surgical Clinics of North America*. 2017; 97: 209–221.
- [2] Kives S, Gascon S, Dubuc É, Van Eyk N. No. 341-diagnosis and management of adnexal torsion in children, adolescents, and adults. *Journal of Obstetrics and Gynaecology Canada*. 2017; 39: 82–90.
- [3] Celik A, Ergün O, Aldemir H, Ozcan C, Ozok G, Erdener A, *et al*. Long-term results of conservative management of adnexal torsion in children. *Journal of Pediatric Surgery*. 2005; 40: 704–708.
- [4] Fuchs N, Smorgick N, Tovbin Y, Ben Ami I, Maymon R, Halperin R, *et al*. Oophoropexy to prevent adnexal torsion: how, when, and for whom? *Journal of Minimally Invasive Gynecology*. 2010; 17: 205–208.
- [5] Mehmetoğlu F. How can the risk of ovarian retorsion be reduced? *Journal of Medical Case Reports*. 2018; 12: 200.
- [6] Tamir Yaniv R, Schonmann R, Agizim R, Sharvit M, Haikin Herzberger E, Daykan Y, *et al*. Correlation between the length of ovarian ligament and ovarian torsion: a prospective study. *Gynecologic and Obstetric Investigation*. 2019; 84: 45–49.
- [7] Bertozzi M, Esposito C, Vella C, Briganti V, Zampieri N, Codrich D, *et al*. Pediatric ovarian torsion and its recurrence: a multicenter study. *Journal of Pediatric and Adolescent Gynecology*. 2017; 30: 413–417.
- [8] Lucchetti MC, Orazi C, Lais A, Capitanucci ML, Caione P, Bakhsh H. Asynchronous bilateral ovarian torsion: three cases, three lessons. *Case Reports in Pediatrics*. 2017; 2017: 6145467.
- [9] Geimanaite L, Trainavicius K. Ovarian torsion in children: management and outcomes. *Journal of Pediatric Surgery*. 2013; 48: 1946–1953.
- [10] Oltmann SC, Fischer A, Barber R, Huang R, Hicks B, Garcia N. Cannot exclude torsion—a 15-year review. *Journal of Pediatric Surgery*. 2009; 44: 1212–1217.
- [11] Adeyemi-Fowode O, McCracken KA, Todd NJ. Adnexal torsion. *Journal of Pediatric and Adolescent Gynecology*. 2018; 31: 333–338.
- [12] Tsafir Z, Hasson J, Levin I, Solomon E, Lessing JB, Azem F. Adnexal torsion: cystectomy and ovarian fixation are equally important in preventing recurrence. *European Journal of Obstetrics, Gynecology, and Reproductive Biology*. 2012; 162: 203–205.
- [13] Oelsner G. Minimal surgery for the twisted ischaemic adnexa can preserve ovarian function. *Human Reproduction*. 2003; 18: 2599–2602.
- [14] Karpelowsky JS, Hei ERL, Matthews K. Laparoscopic resection of benign ovarian tumours in children with gonadal preservation. *Pediatric Surgery International*. 2009; 25: 251–254.