

Transumbilical single-hole laparoscopic treatment of cesarean scar pregnancy by uterine artery pre-ligation: a report of 4 cases

Xin Du^{1,2,*}, Qian Zou¹, Yu-Lan Liu¹

¹Department of Gynecology, Maternal and Child Health Hospital of Hubei Province, Tongji Medical College, Huazhong University of Science and Technology, 430070 Wuhan, Hubei, China

²Hubei Provincial Key Laboratory of Occupational Hazard Identification and Control, Wuhan University of Science and Technology, 430065 Wuhan, Hubei, China

*Correspondence: dongxin@hbfy.com (Xin Du)

DOI: [10.31083/j.ceog4805167](https://doi.org/10.31083/j.ceog4805167)

This is an open access article under the CC BY 4.0 license (<https://creativecommons.org/licenses/by/4.0/>).

Submitted: 15 November 2020 Revised: 24 December 2020 Accepted: 14 January 2021 Published: 15 October 2021

Background: To explore the safety and feasibility of transumbilical single-hole laparoscopic treatment of cesarean scar pregnancy (CSP) by uterine artery pre-ligation. **Methods:** Four cases with type II or III CSP were collected. Under transumbilical single-hole laparoscope, an active knot was first made around the uterine artery. If excessive bleeding occurred, the active knot was tightened to control intraoperative bleeding. Excessive bleeding was defined as more than 50 mL of bleeding within 2 min that failed to respond to electrocoagulation. **Results:** The active knot was tightened in two of the four cases. Overall, the mean intraoperative bleeding was 175.00 ± 155.456 mL, mean operation duration was 171.00 ± 17.455 min, mean postoperative hospitalization was 4.50 ± 0.577 days, and the mean time required for postoperative serum β -HCG to return to normal level was 27.50 ± 5.196 days. Menstruation recovered in 40.25 ± 16.112 days after operation, while postoperative menstrual volume was less in one case and otherwise normal. **Conclusions:** For the treatment of type II or III CSP, transumbilical single-hole laparoscope combined with uterine artery pre-ligation can accurately control and reduce intraoperative bleeding in place of uterine artery embolization. This treatment regimen is safe and may obtain better abdominal appearance.

Keywords

Cesarean scar pregnancy; Single-hole laparoscope; Uterine artery pre-ligation

1. Introduction

Cesarean scar pregnancy (CSP), one of the serious long-term complications that can result after cesarean section, refers to the implantation of fertilized eggs at the previous cesarean scar. As a pregnancy progresses, the gestational sac may implant in scar tissue, which in turn is likely to form dangerous placenta previa or even penetrate the uterus, causing uterine rupture. Once CSP is identified, termination of pregnancy should be performed as soon as possible. The methods for termination of pregnancy vary according to different types of CSP and serum β -HCG levels [1]. For high-risk CSP, termination of pregnancy requires hemostatic pretreatment. After uterine artery embolization (UAE), uterine curettage or laparoscopic resection of lesions are used for treatment of Type II or III CSP [2]. The uterine incision may be repaired

after laparoscopic resection of CSP. Preoperative UAE is expensive, and for some patients may prove unnecessary. UAE followed by uterine curettage or laparoscopic operation exposes patients to pain twice. A great challenge for gynecologists lies in choosing the most appropriate treatment to reduce pain for patients with type II or III CSP. Some scholars have performed laparoscopic resection of CSP combined with uterine artery pre-ligation [3]. However, there are no reports in the literature of single-hole laparoscopic resection of CSP carried out after accurate hemostasis by tightening the active knot around the uterine artery. Here, we reported four cases of single-hole laparoscopic resection of CSP combined with uterine artery pre-ligation.

2. Materials and methods

2.1 Patients

We collected four cases of CSP wherein patients underwent single-hole laparoscopic resection of lesion after uterine artery pre-ligation at the Hubei Maternal and Child Health Hospital between July 2019 and October 2019. All study methods were approved by the Institutional Review Board and Ethics Committee of Hubei Maternal and Child Health Hospital. In all cases, written informed consent to participate in this study was provided. According to the mean, age was 30.00 ± 3.464 years, gestational age was 50.75 ± 6.397 days, gravidity was 3.50 ± 0.577 , parity was 1.25 ± 0.500 , frequency of cesarean section was 1.25 ± 0.500 and preoperative serum β -HCG was 71392.50 ± 71341.612 mIU/mL. As for prior cesarean section, three patients had one and the remaining patient had two. There was no prior history of CSP. Two patients received preoperative uterine curettage without UAE. In one of these cases, uterine curettage was stopped due to excessive bleeding (Table 1). CSP is divided into three types including type I (intrauterine gestational sac survival), type II (gestational sac implanting in the muscular layer of caesarean scar) and type III (abnormal mass or trophoblastic disease) [4].

Table 1. General data and different surgical indicators of four cases with cesarean scar pregnancy.

serial number	1	2	3	4
Ages (years)	27	35	29	29
Gravidity and parity history	G4P2	G3P1	G3P1	G4P1
Number of cesarean sections	2	1	1	1
Time from last menstruation (days)	56	50	55	42
Curettage before laparoscopy	Yes	No	No	Yes
β -HCG level before laparoscopy (mIU/mL)	163579	7947	91170	22874
Time of β -HCG returning to normal (days)	35	26	26	23
diameter of the gestational sac (cm)	4.5 × 4.3 × 3.4	4.5 × 3.5 × 3.8	2.5 × 2.0 × 1.7	3.5 × 1.2 × 1.2
Tighten the uterine artery ligation line	Yes	No	Yes	No
operation time (m)	192	167	175	150
Intraoperative bleeding volume (mL)	400	50	150	150
Postoperative hospital stay (days)	5	4	5	4
Recovery time of menstruation (days)	40	27	31	63
Postoperative menstrual volume	normal	normal	normal	decrease

2.2 Transumbilical single-hole laparoscopic resection of CSP after uterine artery pre-ligation

After general anesthesia, patients remained in a lithotomy position. A mini-laparotomy incision was made in the umbilicus. A disposable single-hole port platform was placed in the abdominal cavity through the incision, and the abdominal cavity was distended with CO₂ gas. Anterior lobes of the right and left broad ligament were opened using an ultrasound knife along the line parallel to the right and left round ligaments, respectively. The two round ligaments were suspended in the middle of the abdominal wall using a 2-0 absorbable thread to expose the field of Douglas Pouch (Fig. 1). After identification of sacral promontory, careful dissection was performed medial to the infundibulopelvic ligament. The peritoneum bilateral to the incision was sutured and suspended to the abdominal wall, permitting exposure of retroperitoneal space.

The terminal branch of the internal iliac artery was separated and exposed followed by retrograde search of the uterine artery and ureter. After the uterine artery was found, an active knot was made around the uterine artery using 7th silk string (Figs. 2,3) followed by removal of suspension line around the round ligaments. One milligram of pituitrin was slowly injected into the myometrium followed by opening the bladder uterus reflex peritoneum using an ultrasound knife (Fig. 4). The space between the bladder and cervix was fully separated to expose the pregnancy scar lesion.

The lesion was removed by ultrasound knife (Fig. 5) and the specimen was removed vaginally via the cervix. Note: if the gestational sac is larger, uterine curettage should be performed preoperatively. After removing all gestational tissue, the cesarean scar was trimmed. The cervix was manipulated by the tenaculum feasibly to supply a proper angle when suturing the cervix and the body of the uterus. The thread was introduced to the abdominal cavity by piercing the abdominal wall, which could immobilize the cut of the cesarean scar for ease of operation.

If intraoperative bleeding is more than 50 mL within two minutes and cannot be controlled by electrocoagulation, the

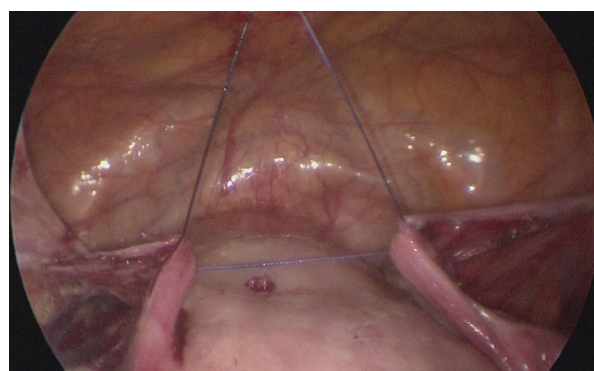


Fig. 1. The suture of round ligament to manipulate the uterus accordingly.

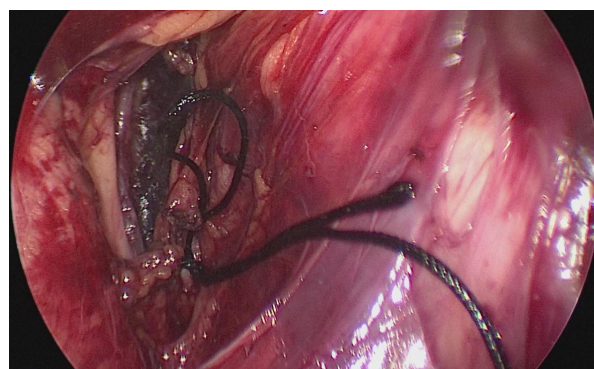


Fig. 2. Active knot on the uterine artery with 7th silk string.

active knot should be properly tightened. If the bleeding is less than 50 mL, it is not necessary to tighten the active knot. After continuous suture of uterine incision and vesical peritoneal reflection (Fig. 6), the active knot thread was removal followed by navelplasty.

2.3 Follow-up observation

The duration between the operation and serum β -HCG levels returning to normal, the duration from operation to menstrual onset, and postoperative menstrual volume were recorded.

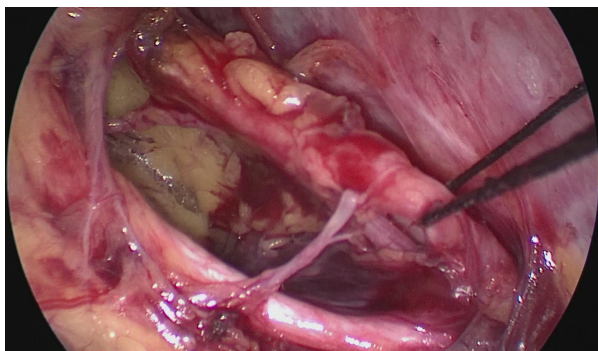


Fig. 3. Traction of 7th silk string on the uterine artery.

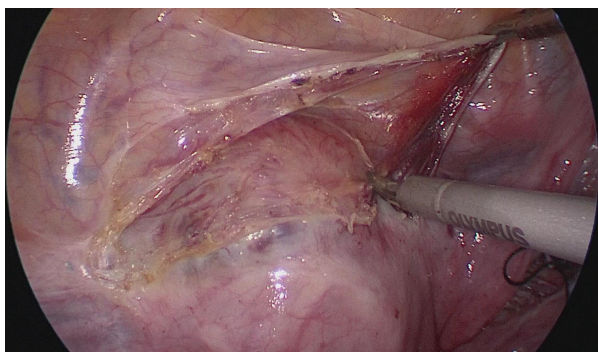


Fig. 4. Dissection of the bladder uterus reflex peritoneum.

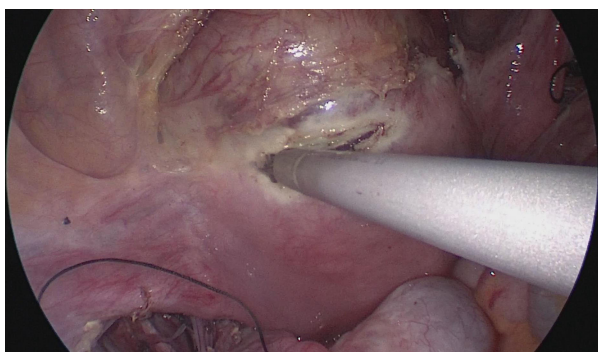


Fig. 5. Incision of low part of uterus where the CSP lies.

3. Outcomes

The active knot was tightened in two of the four cases. Overall, the mean intraoperative bleeding was 175.00 ± 155.456 mL, mean operation duration was 171.00 ± 17.455 min, mean postoperative hospitalization duration was 4.50 ± 0.577 days and the mean time for postoperative serum β -HCG levels to return to normal was 27.50 ± 5.196 days. Menstruation recovered in 40.25 ± 16.112 days after operation, and postoperative menstrual volume was less in one case and normal in the remaining cases (Table 1).

4. Discussion

Criteria for CSP excessive bleeding vary, with some maintaining it is more than 200 mL, and others, more than 500 mL. According to the literature, high-risk factors for CSP ex-

cessive bleeding include serum HCG >20000 mIU/mL, gestational age >8 weeks, maximum diameter of scar pregnancy lesion ≥ 5 cm, myometrial thickness ≤ 0.15 cm, and marked trophoblast invasion [5, 6]. Based on these risk factors, we speculate that the patients in this study had high risk of excessive bleeding because three had HCG >20000 mIU/mL (preoperative mean serum β -HCG: 71392.50 ± 71341.612 mIU/mL), one was in the eighth gestational week, and vaginal color Doppler indicated type II or III CSP. In fact, two cases required tightening of the active knot so as to obtain better hemostatic effect. In these cases, HCG levels were 163579 mIU/mL and 91170 mIU/mL, respectively, suggesting that serum HCG level is strongly associated with the risk of CSP excessive bleeding.

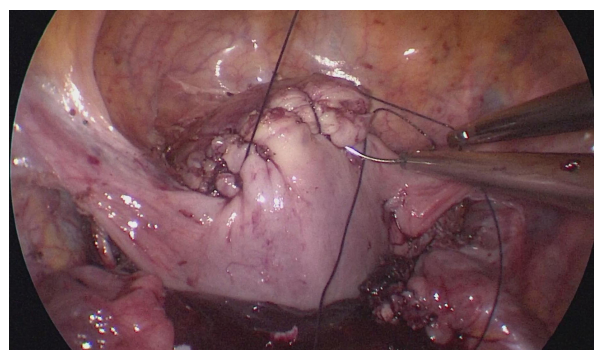


Fig. 6. Continuous suture of uterine incision.

UAE is generally used in preoperative hemostatic pretreatment of CSP [2]. Compared with direct uterine curettage, post-UAE uterine curettage can reduce the risk of excessive bleeding from 28% to 4%, and is more safe and effective than the post-drug treatment uterine curettage. In the post-UAE uterine curettage, the total incidence of complications was 10.4%. Main complications included pelvic pain (25%), fever or infection (18%), nausea and/or vomiting (8%), limb pain (4%) and other [1, 5, 6]. UAE is relatively expensive and may lead to a decline in ovarian reserve function and/or re-pregnancy complications such as fetal growth restriction, premature delivery, placental abruption or placenta increta [7, 8]. In some cases with serum HCG >5000 mIU/mL or even >20000 mIU/mL, intraoperative administration of pituitrin can obtain a very good hemostatic effect without requiring UAE. Accordingly, UAE is not necessary for every patient.

At present, however, no technique exists that can determine whether there will be excessive bleeding in surgical CSP. Since CSP has a rich blood supply, once excessive bleeding occurs, it increases the risks of urinary tract injury and/or permanent ligation of the uterine artery. For patients with fertility requirements, permanent ligation of the uterine artery has potentially adverse effects on subsequent pregnancy and ovarian function. Therefore, intraoperative uterine artery pre-ligation can accurately control bleeding by temporarily blocking uterine artery blood supply according

to intraoperative blood loss. Uterine artery pre-ligation can avoid long-term uterine artery blood supply interruption and protect female reproductive function.

Single-hole laparoscopy has been widely used in the treatment of benign gynecological diseases. Only some hospitals and doctors are technically advanced in single-hole laparoscopic treatment of malignant tumors [7]. In the case of benign gynecological diseases, the technical difficulty for single-hole laparoscopic treatment of CSP is higher. Laparoscopic treatment of CSP by uterine artery pre-ligation has been reported in China [1]. However, laparoscope may produce more scars, affecting abdominal appearance. Transumbilical single-hole laparoscopic treatment is similar to scar-free surgery which allows the abdomen to maintain its normal appearance.

To date, there have been no reports on transumbilical single-hole laparoscopic treatment of CSP by uterine artery pre-ligation. Under the single-hole laparoscope, it is challenging to locate the inception of uterine artery since the surgical field is small after opening the anterior lobe of broad ligament. To address this obstacle, we suspended the two round ligaments in the middle of the abdominal wall to expose the field of vision after opening the anterior lobes of the bilateral broad ligaments. When looking for the uterine artery, the terminal branch of the internal iliac artery was first found followed by retrograde search of the uterine artery, an easier pathway for doctors, based on malignant tumor surgery. For doctors lacking experience of this modality in malignant tumor surgery, the operation should be carried out step by step.

In this study, two patients received temporary uterine artery blood supply interruption. Compared with their counterparts, it appears that the higher the level of serum HCG, the greater the risk of intraoperative excessive bleeding. The number of cases here is too small to obtain HCG cutoff values for intraoperative excessive bleeding. In future clinical practice, we will collect more cases to analyze the relationships of intraoperative excessive bleeding with gestational age, size of gestational sac, CSP type and serum HCG level to provide a reference for the selection of more proper hemostatic pre-treatment.

5. Conclusions

Transumbilical single-hole laparoscopic treatment of CSP by uterine artery pre-ligation can accurately control and reduce intraoperative bleeding and retain normal abdominal appearance. As a treatment regimen, it is safe and cost effective.

Author contributions

XD and YLL designed the study. QZ reviewed the literature and wrote the initial draft. XD critically revised the manuscript. All authors approved the final version.

Ethics approval and consent to participate

This study was approved by the Medical ethics committee of Maternal and Child Health Hospital of Hubei Province

(project no. [2020]IEC,NO.LW053) on 31 August 2020. Informed consent was obtained from all subjects involved in the study.

Acknowledgment

We would like to express our gratitude to all those who helped us during the writing of this manuscript.

Funding

This study was supported by Health commission of Hubei Province scientific research project (WJ2019H190).

Conflict of interest

The authors declare no conflict of interests.

References

- [1] Family Planning Section, Gynecology and Obstetrics Branch, Chinese Medical Association. Expert consensus on diagnosis and treatment of uterine scar pregnancy after cesarean section. *Zhonghua Fu Chan Ke Za Zhi*. 2016; 51: 5–9. (In Chinese)
- [2] Wang BY, Shuai W, Wang HY. Observation on the clinical effect of interventional treatment for cesarean scar pregnancy. *Chinese Journal of Reproduction and Contraception*. 2013; 33: 137–140.
- [3] Huang L, Zhao L, Shi H. Clinical efficacy of combined hysteroscopic and laparoscopic surgery and reversible ligation of the uterine artery for excision and repair of uterine scar in patients with type ii and iii cesarean scar pregnancy. *Medical Science Monitor*. 2020; 26: e924076.
- [4] Yang X. Typing and treatment of cesarean scar pregnancy. *Chinese Journal of Clinical Obstetrics and Gynecology*. 2012; 13: 401–403.
- [5] Maheux-Lacroix S, Li F, Bujold E, Nesbitt-Hawes E, Deans R, Abbott J. Cesarean scar pregnancies: a systematic review of treatment options. *Journal of Minimally Invasive Gynecology*. 2017; 24: 915–925.
- [6] Ma Y, Shao M, Shao X. Analysis of risk factors for intraoperative hemorrhage of cesarean scar pregnancy. *Medicine*. 2017; 96: e7327.
- [7] Expert Technical Cooperation Group on Gynecological Single Hole Laparoscopic surgery (including NOTES), Gynecology and Obstetrics Branch, Chinese Medical Doctor Association. Exploration, development and present situation of gynecologic single hole laparoscopic and NOTES surgery in Chinese mainland. *Chinese Journal of Laparoscopic Surgery*. 2018; 11: 1–3. (In Chinese)
- [8] Liu G, Wu J, Cao J, Xue Y, Dai C, Xu J, *et al*. Comparison of three treatment strategies for cesarean scar pregnancy. *Archives of Gynecology and Obstetrics*. 2017; 296: 383–389.