

Uterine cervical carcinosarcoma; very rare and aggressive behavior; literature review

Özer Birge^{1,*}, Mehmet Sait Bakır¹, Ceyda Karadağ¹, Can Dinc¹, Tayup Simsek¹

¹Akdeniz University, Department of Gynecology Obstetrics, Division of Gynecologic Oncology, 07010 Antalya, Turkey

*Correspondence: ozbirge@gmail.com (Özer Birge)

DOI:10.31083/j.ceog.2021.02.2219

This is an open access article under the CC BY 4.0 license (<https://creativecommons.org/licenses/by/4.0/>).

Submitted: 12 July 2020 Revised: 29 September 2020 Accepted: 15 October 2020 Published: 15 April 2021

Background: Carcinosarcoma is a rare malignancy of the female reproductive system, consisting of carcinomatous and sarcomatous components. It originates from the paramesonephric and mesonephric duct residues and is also called malignant mixed Mullerian tumor. **Case Presentation:** A 58-year-old post-menopausal woman, gravida 2, parity 2, who had no known diseases and no previous surgery presented to another clinic with pelvic pain that had been persisting for about a year and vaginal bleeding for the past month. There was continuous bleeding that was not associated with coitus, and cervical biopsy was reported as carcinosarcoma of heterologous type (the epithelial part was serous carcinoma and the mesenchymal part was chondrosarcoma); the patient was referred to our clinic and underwent evaluation. **Conclusion:** Effective follow-up is very important considering the aggressive clinical picture of carcinosarcoma cases. It should be kept in mind that metastasis may occur, especially in cases with hypercalcemia and deterioration of the general condition.

Keywords

Carcinosarcoma; Uterine cervix; Paramesonephric; Mesonephric; Hypercalcemia

1. Background

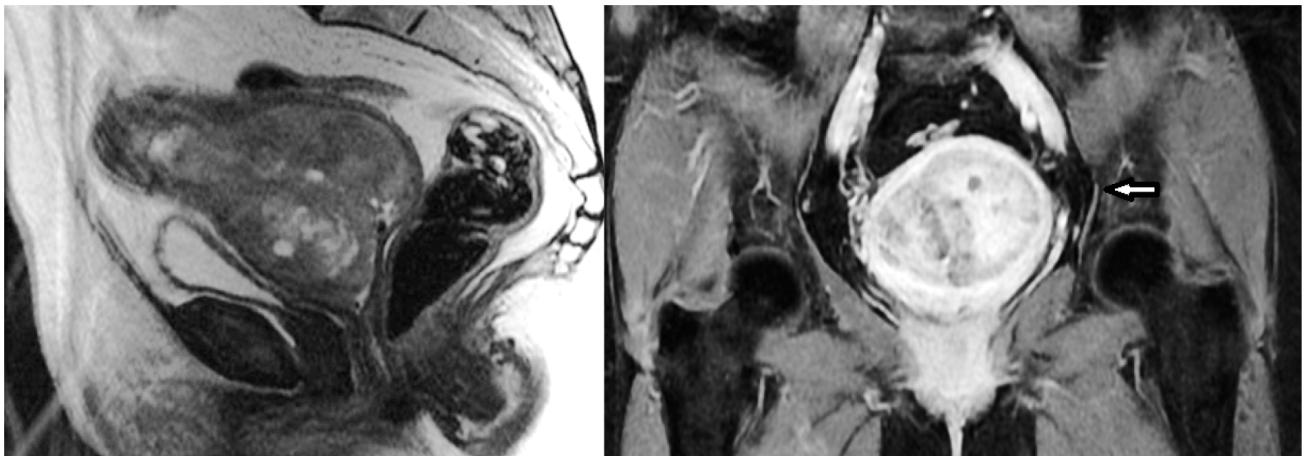
Carcinosarcoma is a rare malignancy of the female reproductive system, comprising carcinomatous and sarcomatous components. It originates from the paramesonephric and mesonephric duct residues and is also called malignant mixed Mullerian tumor [1]. Although the uterine corpus is the most common localization, carcinosarcomas may originate from the uterus, cervix, ovary, fallopian tube, vagina, peritoneal surfaces and all tissues of mesonephric origin [2]. Cervical carcinosarcomas are rare and fewer than 70 cases have been reported in the English literature [1]. While most cervical carcinosarcomas have homologous mesenchymal components, the presence of a heterologous mesenchymal component is limited to eleven cases in the literature [3]. We also aimed to present and discuss the case of the twelfth cervical carcinosarcoma with heterologous component that had been operated in our clinic, along with the literature. Carcinosarcoma is an aggressive tumor and its recurrence occurs in a short time after treatment. When the literature was investigated, it was found that most of the cases were at an early stage, as in our case [4-7]. It was also observed that one case relapsed as early as 11 months after treatment and it was re-

ported that the other two cases died within 7 months (Table 1).

2. Case presentation

A 58-year-old post-menopausal woman, gravida 2, parity 2, who had no known diseases and no previous surgery presented to another clinic with pelvic pain that had been persisting for about a year and vaginal bleeding for the past month. There was continuous bleeding that was not associated with coitus, and cervical biopsy was reported as carcinosarcoma of heterologous type (the epithelial part was serous carcinoma and the mesenchymal part was chondrosarcoma); the patient was referred to our clinic and evaluated. It was learnt that the cervical cytological examination of the case had never been performed. In the speculum examination, there was a large cervix according to age with multiparous and hemorrhage, in addition to erosion. In the bimanual examination, the parameters were free of tumor, and a mass with a smooth surface was detected. On transvaginal ultrasonography, a solid mass of 9 × 6 cm was observed in the cervical region. Furthermore, a cystic lesion on the left adnexa consistent with a dermoid cyst of 5 cm was observed. On the magnetic resonance examination, the endometrium double wall thickness was 7 mm and there was a mass lesion of 9 × 6 cm located in the cervix that extended towards the endometrium and the myometrium, which was evaluated to be consistent with invasion into the parametrial tissue. A mass lesion of approximately 6 cm with a 3 × 2 cm nodular appearance in the left ovary was evaluated to be consistent with a mature cystic teratoma. Furthermore, several lymph nodes were observed in the left parametrial area (Fig. 1A,B). The patient had no known comorbid disease and no family history of cancer.

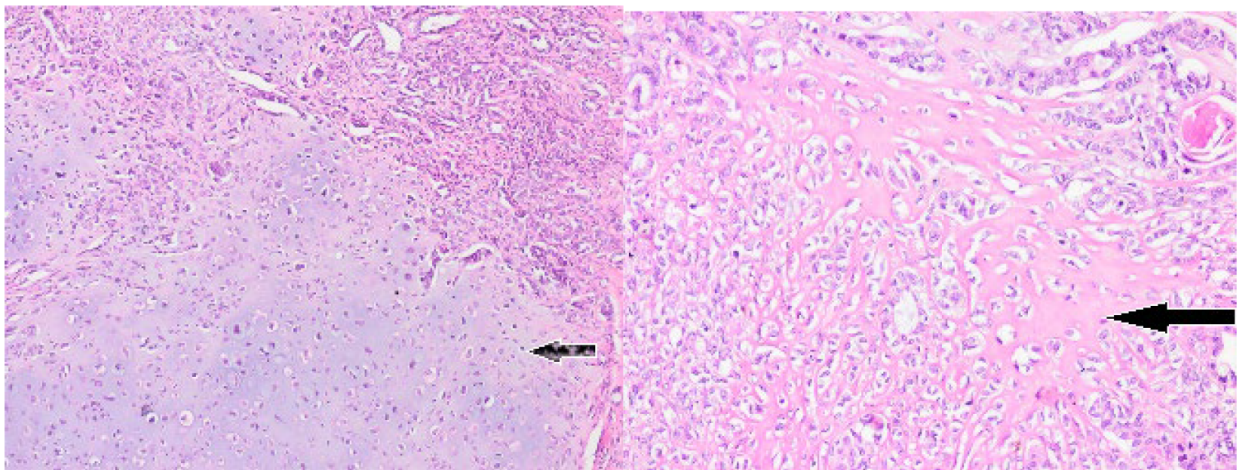
The operation was completed by performing type 2 radical hysterectomy, bilateral salpingo-oophorectomy, bilateral pelvic and paraaortic lymph node dissection and omentum biopsies. The final pathology of the case was reported to be of cervical origin; the epithelial part was serous carcinoma and the mesenchymal part was chondrosarcoma and osteosarcoma with heterologous component carcinosarcoma (Fig. 2). The left ovarian mass was reported to be a ma-



A

B

Fig. 1. Uterine cervical mass on magnetic resonance examination (sagittal and coronal section).



A

B

Fig. 2. Chondrosarcoma and osteosarcoma with heterologous component carcinosarcoma on pathological examination (H&E × 40). (A) Chondrosarcoma and osteosarcoma with heterologous component carcinosarcoma on pathological examination. Heterologous chondrosarcomatous component composed of chondrocytes with atypical, enlarged, variably shaped and sized, hyperchromatic nuclei embedded in a blue-gray chondroid matrix. (B) Heterologous osteosarcomatous component composed of osteoblasts with enlarged, hyperchromatic, atypical nuclei embedded in thin, lace-like osteoid (H&E × 40).

ture cystic teratoma. The largest size of the tumor was 10 cm; it did not extend to the vagina; there was no tumor at the vaginal surgical margin, the omentum was benign, the lymph nodes and the cytology were negative, but the tumor was reported to have lymphovascular invasion. In the multidisciplinary meeting, 4 cycles of chemotherapy (carboplatin-paclitaxel) and 28 days of external radiotherapy (28 days ERT) were planned. The patient's CT, which was performed during the routine controls approximately 14 months after the last dose of chemotherapy, demonstrated opacities suggesting recurrence in the lung parenchyma, which were evalu-

ated by PET/CT. Positron emission tomography (PET/CT) demonstrated multiple metastatic nodules (SUVmax: 19.3) of approximately 2.5 cm in both lungs. In addition, a necrotic hypermetabolic mass (SUVmax: 14, metastatic lymph nodes) and lytic metastatic lesion on the right side of L4 vertebral corpus (SUVmax: 16) were displayed in the left paraaortic region. Treatment with 3 cycles of cisplatin-doxorubicin was begun. PET/CT was performed after the third cycle. Upon observation of a partial response compared to the pre-treatment findings lung metastatic nodule (SUVmax: 19,3→6,8), paraaortic metastatic lymph node [(SUVmax:

Table 1. Cervical carcinosarcomas in the literature and the new case.

Patient number	Age	Stage (FIGO)	Recurrence	Death	Follow-up/overall survival (month)
1 ⁴	65	1b	NO	NO	23
2 ⁵	37	1b	YES	NO	11
3 ⁵	40	1b	NO	NO	28
4 ⁵	73	1b	NO	NO	36
5 ⁶	39	1b	NS	YES	74
6 ⁷	54	2a	NS	YES	7
7 ⁷	54	1b	NO	NO	13
8 ⁷	62	4b	YES	NO	36
9 ¹	63	2a	NO	NO	10
10 ¹⁹	59	3b	NO	NO	4
11 ²⁰	64	2a	NS	YES	7
12 (new case)	58	1b3 (FIGO 2018)	YES	NO	20

NS, not state.

14→8,3), L4 vertebra corpus lytic metastatic lesion SUVmax: 16→6.2)], 3 more cycles of cisplatin-doxorubicin chemotherapy were begun. The patient's chemotherapy is still continuing.

3. Discussion

These tumors, defined as malignant mixed Mullerian or mesodermal tumors, have mixed histological findings of sarcoma and carcinoma. The tumor is thought to originate from totipotent mesenchymal stromal cells [8–11]. The carcinomatous part is mostly glandular and the sarcomatous part may resemble the normal uterine stroma (homologous component) or non-genital tissues such as cartilage, fat, bone and smooth muscle tissue (heterologous component). Nowadays, these mixed tumors are considered to be monoclonal cell-derived malignancies that exhibit sarcomatous metaplasia, unlike the mixture of carcinoma and sarcoma [12–14].

With regard to risk factors, clinical symptoms and recurrence rates in particular, these tumors have similar features to high-grade endometrium cancer [13, 14]. Carcinosarcomas are seen in 3% of uterine malignancies, but in particular, most are of uterine corpus origin; those of cervical origin are very rare, but their prognosis is much worse [15]. The clinical prognosis is determined by the carcinomatous component, which is most frequently high-grade serous carcinoma [14, 16]. Almost all carcinosarcomas are seen after menopause and the median age of the patients is 62. It is more common in the black population and comorbidities such as obesity, diabetes and hypertension often accompany the disorder. 7–37% of the cases have a history of pelvic radiation [12, 15]. Carcinosarcomas generally have a soft and polypoid structure that quickly fills the area of origin and includes necrosis and bleeding areas. It can invade all tissues at various degrees. Areas in which the spread of the tumor is most frequently observed include the pelvis, lymph nodes, peritoneal cavity, lungs and the liver, and it can spread to all areas of the body. This aggressive metastatic pattern explains the poor prognosis. In the literature, it has been reported that these cases are most common in the post-menopausal period

and that the most common clinical presentation is vaginal bleeding [17, 18]. Our case was also in the post-menopausal period and the reason for presentation was vaginal bleeding that had been continuing for one month. Furthermore, similar to patients presenting with acute abdominal findings due to tumor rupture in the literature [19], there was persisting pelvic and abdominal pain in our case, and it was observed that there had been several emergency presentations and that treatments had been given considering urinary tract infection. In postmenopausal period in particular, it is important to evaluate the cases that describe vaginal bleeding and pelvic pain for carcinoma etiology. The prognosis of carcinosarcoma is much better when it is detected at an early stage. However, in this case, due to advanced age, large mass and lymphovascular invasion, recurrence occurred in multiple areas at the 14th month, and the chemotherapy of the case continues. A case with post-menopausal vaginal bleeding and a cervical polyp was reported as carcinosarcoma developing from the cervical polyp base as a result of histopathological examination [20].

Surgery is the main treatment in all carcinosarcomas. Total extrafascial hysterectomy and bilateral salpingo-oophorectomy constitute the standard surgical procedure [3]. As with other gynecological malignancies, cytology and multiple biopsies from suspicious locations are part of the surgical staging. Cytoreduction, lymphadenectomy, omentectomy and fertility sparing surgery are controversial issues. There are studies showing that adjuvant radiotherapy reduces the local recurrence, especially in early stage carcinosarcoma, but its effects on survival are not clear [21]. Many different studies have found that radiotherapy has no effect on survival in genital carcinosarcomas [22, 23]. The effect of adjuvant RT in early stage carcinosarcoma cases was investigated in a prospective study of EORTC (European Organization for Research and Treatment of Cancer Gynecological Cancer Group Study) with other uterine sarcomas. Adjuvant radiotherapy was found to be useful in local control of the disease when the analysis was performed for patients with

carcinosarcomas, but the same benefit was not determined for disease-free survival or overall survival [24]. Our patient was given 28 days of radiotherapy treatment, but multiple relapses were detected in the lungs and bones at the end of the treatment; therefore, it is difficult to say anything about the effect of radiotherapy on disease-free survival. When the literature is investigated, the information on adjuvant chemotherapy in carcinosarcoma is controversial; most of the data are based on non-randomized-controlled studies and there is no clear chemotherapeutic agent combination. Furthermore, the effects of these combinations on disease free survival and overall survival are not clear [20]. In our case, the combination of 4 cycles of carboplatin + paclitaxel was used in adjuvant therapy, and upon detection of multiple relapses, the chemotherapy regime of the patient was switched to cisplatin + doxorubicin, which has been featured in some studies [25]. The radiotherapy option can be used in patients who cannot be operated due to concomitant disease, poor performance and advanced age, and hormonal treatment options can be applied in patients with extensive metastatic disease [26, 27]. In the case of Ribeiro B *et al.*, despite carboplatin + paclitaxel chemotherapy with external radiotherapy after radical surgery, widespread bone metastases were detected on the PET-CT (positron emission tomography) performed due to the presence of weakness and hypercalcemia at the 5th month control. Chemotherapy treatment was continued, but cases with progression passed away. When the eleven cases in the literature were examined, recurrence occurred at the eleventh month in one case and at the thirty-sixth month in the other case [20]. In our case, deterioration in the general condition was observed at the 14th month after chemotherapy. Electrolyte disorder (hypercalcemia) due to nutritional problem was found in the examinations performed and medically treated. The chemotherapeutic agents were changed after PET-CT detected multiple metastatic lesions in the lungs and bones.

4. Conclusions

Effective follow-up is very important considering the aggressive clinical picture in carcinosarcoma cases. It should be kept in mind that metastasis may occur, especially in cases with hypercalcemia and poor general condition. When the literature is investigated, it is seen that our case is the twelfth carcinosarcoma case of cervical origin with heterologous component. Prognostic factors are still uncertain in cervical carcinosarcomas and due to its rarity, there is no consensus for the optimal treatment. However, considering the general aggressive behavior of carcinosarcomas, the choice should be towards aggressive surgical treatment.

Author contributions

OB, MSB, CK, CD and TS assembled, analyzed and interpreted the patient data. All authors contributed to writing the manuscript. All authors read and approved the final manuscript.

Ethics approval and consent to participate

The patient gave her informed consent for redaction and publication of the case report. The report was approved by Hospital Akdeniz University's Ethics Committee for publication. Written informed consent was obtained from the patient for publication of this case report and any accompanying images. A copy of the written consent is available for review by the Editor-in-Chief of this journal.

Acknowledgment

We thank the patient and her family for allowing us to share her details and thank all the staff of Nyala Sudan Turkey Training and Research Hospital and Akdeniz University Hospital.

Funding

This research received no external funding.

Conflict of interest

The authors declare no conflict of interest.

Availability of data and material

The authors agree to make the raw data and materials described in our manuscript freely available.

References

- [1] Meguro S, Yasuda M, Shimizu M, Kurosaki A, Fujiwara K. Mesonephric adenocarcinoma with a sarcomatous component, a notable subtype of cervical carcinosarcoma: a case report and review of the literature. *Diagnostic Pathology*. 2013; 8: 756.
- [2] Semczuk A, Ignatov A, Obrzut B, Reventos J, Rechberger T. Role of p53 pathway alterations in uterine carcinosarcomas (malignant mixed Müllerian tumors). *Oncology*. 2014; 87: 193–204.
- [3] Kadota K, Haba R, Ishikawa M, Kushida Y, Katsuki N, Hayashi T, *et al.* Uterine cervical carcinosarcoma with heterologous mesenchymal component: a case report and review of the literature. *Archives of Gynecology and Obstetrics*. 2009; 280: 839–843.
- [4] Bloch T, Roth LM, Stehman FB, Hull MT, Schwenk GR. Osteosarcoma of the uterine cervix associated with hyperplastic and atypical mesonephric rests. *Cancer*. 1988; 62: 1594–1600.
- [5] Clement PB, Young RH, Keh P, Östör AG, Scully RE. A report of eight cases, including four with a malignant spindle cell component. *The American Journal of Surgical Pathology*. 1995; 19: 1158–1171.
- [6] Kang JS, Kim T, Lee HK, Lim NI, Park MH. Primary carcinosarcoma of the uterine cervix. *Obstetrics & Gynecology Science*. 1994; 37: 1872–1879.
- [7] Bagué S, Rodríguez IM, Prat J. Malignant mesonephric tumors of the female genital tract. *The American Journal of Surgical Pathology*. 2004; 28: 601–607.
- [8] Munakata S, Iwai E, Tanaka T, Nakamura M, Kanda T. Malignant müllerian mixed tumor of the uterine cervix with a small cell neuroendocrine carcinoma component. *Case Reports in Pathology*. 2013; 2013.
- [9] Shim JJ, Shim JC, Lee HK, Lee KE, Lee GJ, Kim HK, *et al.* Malignant mixed müllerian tumor arising from the uterine cervix: a case report. *Journal of the Korean Society of Radiology*. 2012; 67: 263.
- [10] Gupta N, Dudding N, Smith JH. Eight cases of malignant mixed müllerian tumor (carcinosarcoma) of the uterus: findings in SurePath cervical cytology. *Diagnostic Cytopathology*. 2014; 42: 165.

- [11] Agarwal M, Pradhan S. Malignant mixed mullerian tumor of cervix. *Annals of Woman and Child Health*. 2016; 2: 1.
- [12] Lurain JR. Uterine cancer (pp. 1343–1401). In: Berek JS. *Berek & Novak's Gynecology*. 14th ed. Baltimore: Lippincott Williams & Wilkins. 2007.
- [13] McCluggage WG. Malignant biphasic uterine tumours: carcinosarcomas or metaplastic carcinomas? *Journal of Clinical Pathology*. 2002; 55: 321–325.
- [14] Crum C, Lee KR. *Diagnostic gynecologic and obstetric pathology*. 3 ed. Amsterdam: Elsevier Saunders. 2017.
- [15] Abell MR, Ramirez JA. Sarcomas and carcinosarcomas of the uterine cervix. *Cancer*. 1973; 31: 1176–1192.
- [16] Silverberg SG, Major FJ, Blessing JA, Fetter B, Askin FB, Liao S, *et al*. Carcinosarcoma (Malignant Mixed Mesodermal Tumor) of the Uterus. *International Journal of Gynecological Pathology*. 1990; 9: 1–19.
- [17] Tseng C, Chen C, Chen S, Chi C. Tumor rupture as an initial manifestation of malignant mesonephric mixed tumor: a case report and review of the literature. *International Journal of Clinical and Experimental Pathology*. 2014; 7: 1212–1217.
- [18] Kim M, Lee C, Choi H, Ko J, Kang G, Chun K. Carcinosarcoma of the uterine cervix arising from Müllerian ducts. *Obstetrics & Gynecology Science*. 2015; 58: 251–255.
- [19] Tseng C, Chen C, Chen S, Chi C. Tumor rupture as an initial manifestation of malignant mesonephric mixed tumor: a case report and review of the literature. *International Journal of Clinical and Experimental Pathology*. 2014; 7: 1212–1217.
- [20] Ribeiro B, Silva R, Dias R, Patrício V. Carcinosarcoma of the uterine cervix: a rare pathological finding originating from mesonephric remnants. *BMJ Case Reports*. 2019; 12: e227050.
- [21] Sampath S, Schultheiss TE, Ryu JK, Wong JYC. The role of adjuvant radiation in uterine sarcomas. *International Journal of Radiation Oncology · Biology · Physics*. 2010; 76: 728–734.
- [22] Gerszten K, Faul C, Kounelis S, Huang Q, Kelley J, Jones MW. The impact of adjuvant radiotherapy on carcinosarcoma of the uterus. *Gynecologic Oncology*. 1998; 68: 8–13.
- [23] Wright JD, Seshan VE, Shah M, Schiff PB, Burke WM, Cohen CJ, *et al*. The role of radiation in improving survival for early-stage carcinosarcoma and leiomyosarcoma. *American Journal of Obstetrics and Gynecology*. 2008; 199: 536.e1–536.e8.
- [24] Reed NS, Mangioni C, Malmström H, Scarfone G, Poveda A, Pecorelli S, *et al*. Phase III randomised study to evaluate the role of adjuvant pelvic radiotherapy in the treatment of uterine sarcomas stages I and II: an European Organisation for Research and Treatment of Cancer Gynaecological Cancer Group Study (protocol 55874). *European Journal of Cancer*. 2008; 44: 808–818.
- [25] Galaal K, Godfrey K, Naik R, Kucukmetin A, Bryant A. Adjuvant radiotherapy and/or chemotherapy after surgery for uterine carcinosarcoma. *Cochrane Database of Systematic Reviews*. 2011; CD006812.
- [26] Gonzalez Bosquet J, Terstriep SA, Cliby WA, Brown-Jones M, Kaur JS, Podratz KC, *et al*. The impact of multi-modal therapy on survival for uterine carcinosarcomas. *Gynecologic Oncology*. 2010; 116: 419–423.
- [27] Spano JP, Soria JC, Kambouchner M, Piperno-Neuman S, Morin F, Morere JF, *et al*. Long-term survival of patients given hormonal therapy for metastatic endometrial stromal sarcoma. *Medical Oncology*. 2003; 20: 87–93.