

Hemoperitoneum caused by bleeding of adenomyosis: a case report

Su-Xian Zhang¹, Lu Wu¹, You-Fang Hou¹, Bo Yan¹, Shao-Yan Yang¹, Li-Hua Yang^{1,*}, Qing-Hua Zhao^{1,*}

¹Department of Gynaecology, The Second Affiliated Hospital of Kunming Medical University, 650101 Yunnan, China

*Correspondence: 13759481789@163.com (Li-Hua Yang); jiansongwang@126.com (Qing-Hua Zhao)

DOI:10.31083/j.ceog.2021.02.2119

This is an open access article under the CC BY-NC 4.0 license (<https://creativecommons.org/licenses/by-nc/4.0/>).

Submitted: 18 April 2020 Revised: 20 July 2020 Accepted: 28 July 2020 Published: 15 April 2021

Rationale: Adenomyosis is a disease in which the endometrial tissues (glands and stroma) extend into the myometrium. It usually occurs in parous women aged 35 to 50 years old. The common symptoms include secondary severe dysmenorrhea and menorrhagia. Hemoperitoneum is extremely rare and easily overlooked. **Patient concerns:** A 46-year-old woman had adenomyosis and hemoperitoneum caused by bleeding of adenomyosis. **Diagnoses:** Adenomyosis and hemoperitoneum. **Interventions:** Hysterectomy with unilateral adnexectomy and subcutaneous injection of GnRH- α every 28 days for 3 times. **Outcomes:** The patient recovered well after the operation and was asymptomatic for 3 months after the operation. **Lessons:** We reported a case of adenomyosis in a parous woman. This patient received surgery because hemoperitoneum caused by bleeding of adenomyosis. It was important to timely diagnose and treat.

Keywords

Adenomyosis; Bleeding; Hemoperitoneum; Surgery

1. Introduction

Adenomyosis (AD), a common gynecological disease, is caused by the invasion of endometrial glands and stroma into the myometrium to form diffuse or localized lesions [1]. AD mostly occurs in women over 40 years old. However, in recent years, the onset age gradually becomes younger, which may be related to increasing cesarean section and artificial abortion, etc. [2]. Transvaginal ultrasound and magnetic resonance imaging (MRI) are helpful for diagnosis of AD. Moreover, histopathological examination is needed to confirm the diagnosis. At present, gonadotropin releasing hormone (GHRH) agonist and levonorgestrel intrauterine sustained-release system are common treatment methods for AD [3, 4]. The conservative operation methods include uterine artery embolization (UAE), focal resection and high intensity focused ultrasound (HIFU) [5, 6].

Patients with AD may have abnormal uterine bleeding, dysmenorrhea or infertility. However, one third of them are often asymptomatic [7]. The most common symptoms are increasingly secondary severe dysmenorrhea and menorrhagia [8]. Hemoperitoneum is very rare and easy to be overlooked. In this case report, we described a rare case of AD and endometriosis cyst accompanied by hemoperitoneum.

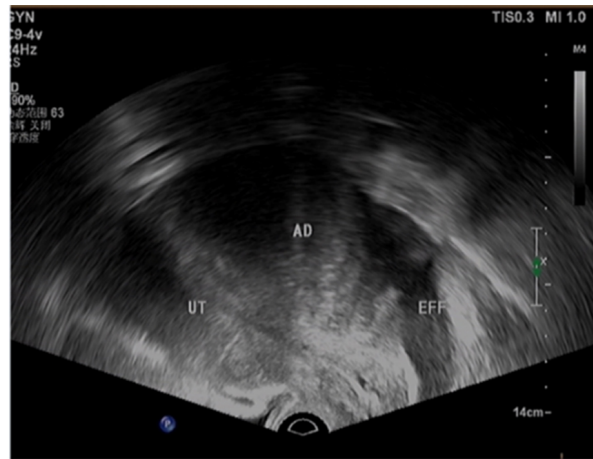
2. Case report

The patient signed informed consent. The study was conducted in accordance with the Declaration of Helsinki, and the protocol was approved by the Ethics Committee. A 46-year-old woman suffered from irregular vaginal bleeding for about 6 months. Moreover, she had abdominal pain, nausea and vomiting for about 3 days, and dizziness for about 1 day. She had regular menstruation with amount of about 100 mL and period of 5–6 days/28–30 days. In particular, she had dysmenorrhea, and the visual analogue score (VAS) was 6 points. Her last menstruation was unknown. The patient had AD for 10 years without treatment. G4P2 (i.e., gravida 4, para 2). The vagina bleeding was irregular in the past 6 months, but she didn't receive standard treatment.

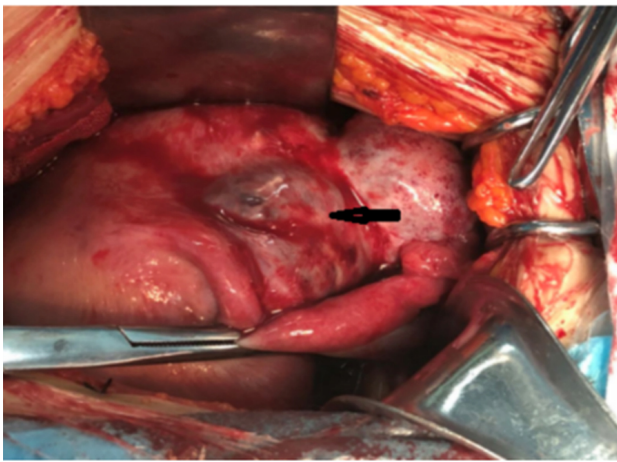
Physical examination showed abnormalities. Additionally, it was suspected positive shifting dullness with abdominal distention and muscle tightness, tenderness, and rebound pain. Gynecological examination showed a small amount of dark red bloody secretions in the vagina, hypertrophy of the cervix, cervical pain, uterus enlargement, and unsatisfactory palpation of the uterus and double appendages. The fornix was smooth without nodul. No abnormality was found in digital rectal examination.

B-ultrasound showed adenomyosis with hysteromyoma with size of 13.3 × 9.0 × 10.0 cm, uterine cavity fluid and pelvic cavity fluid (Fig. 1A). Computed tomography (CT) showed that the shape of uterus was obviously enlarged with local uplift, so that myoma of uterus was excluded. Moreover, mesangial fascia around rectum was thicker and there was pelvic fluid. Urine pregnancy test was negative. Routine blood tests, electrocardiogram, liver and kidney functions and amylase were all normal except that the hemoglobin value was 70 g/L. The final diagnosis was abdominal pain caused by acute pelvic inflammation or dysmenorrhea, adenomyosis and moderate anemia. After giving symptomatic treatment for spasmolysis, the patient's condition did not improve and the abdominal pain did not relieve.

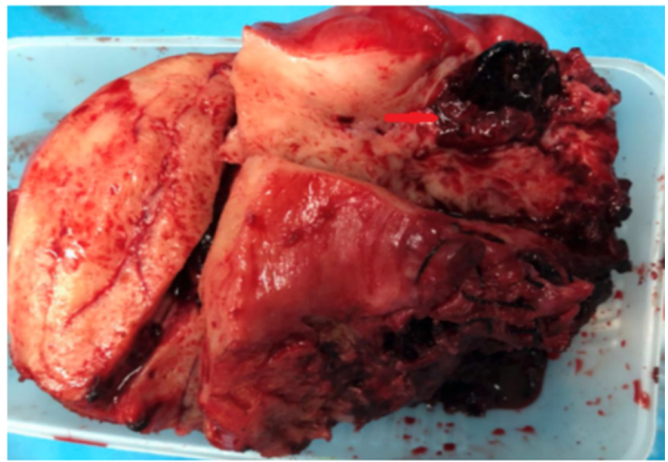
After 4 days of hospitalization, the blood cell analysis showed that hemoglobin value was 54 g/L. And the progressive decrease of hemoglobin value indicated internal bleeding. The amount of anticoagulant was about 3 mL deter-



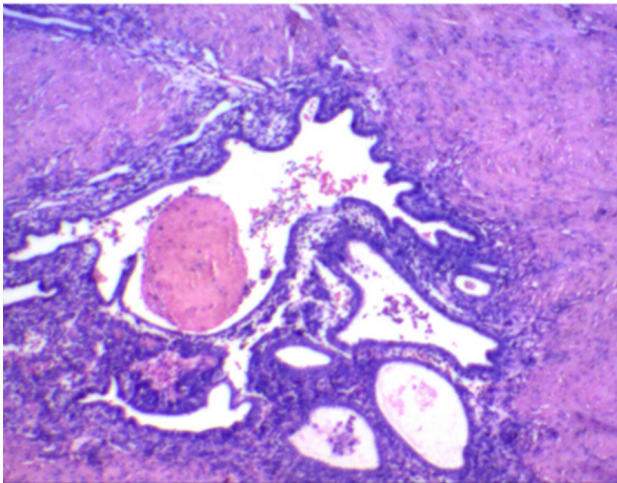
A



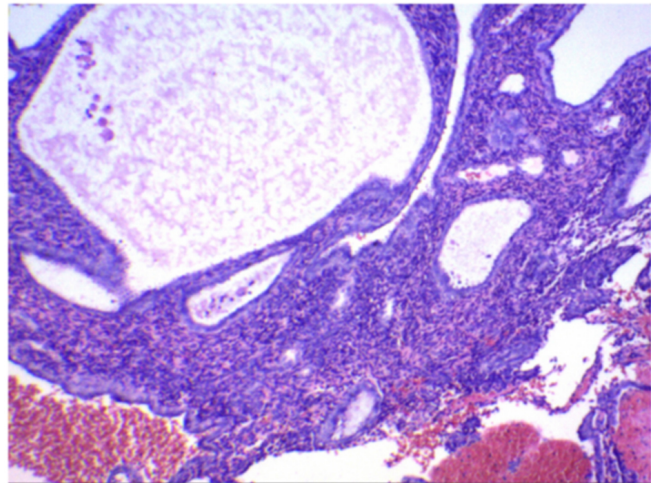
B



C



D



E

Fig. 1. Preoperative and postoperative examination. (A) B ultrasound imaging. (B) The dark red mass on the left posterior wall of the uterus. (C) Excised mass. (D) Histopathologic examination of adenomyosis. (E) Histopathologic examination of left ovary endometriosis with hyperplasia and polyp formation.

mined by vaginal posterior fornix puncture, which was considered the existence of hemoperitoneum for emergency laparotomy. Intraoperative observation suggested blue stain-

ing of peritoneum, dark red hematocoele in abdominal cavity, increased uterus volume, irregular shape, hard mass, poor mobility, and barrel-shaped thickening of cervix. The dark

red mass with size of about $7 \times 6 \times 6$ cm on the left adnexal region adhered tightly to the left posterior wall of the uterus and the left broad ligament, and the mass was intact without fracture (Fig. 1B). Then, the patient underwent abdominal hysterectomy and bilateral adnexal resection. After operation, the myometrium of the uterus was thickened and hard. Necrotic tissue and dark red blood clot were observed in the mass (Fig. 1C). A mass with size of $6 \times 4 \times 4$ cm was observed in the left ovary. The cyst fluid was chocolate-like.

The patient recovered well after surgery. Postoperative histopathology showed adenomyosis (Fig. 1D) and endometriosis cyst (Fig. 1E). CA-125 was 521.40 U/mL, CA-199 was 162.11 U/mL, and SCC was 3.8 ng/mL. Eventually, the patient was diagnosed as rupture and bleeding of adenomyosis and endometriosis cyst. The patient was treated with GnRH to prevent recurrence (leuprorelin 3.75 mg, hypodermic injection, once every 28 days). When the third injection was given, the patient suffered from poor sleep, sweating, leg acid and other perimenopause and osteoporosis symptoms. She received Livial for 12.5 mg, once a night. After calcium supplementation, the above symptoms were improved.

3. Discussion

In recent years, the etiology of AC has been studied in depth. It is generally believed that AD is caused by no submucosa between endometrium and myometrium. Endometrium glands and stroma are easy to directly invade the inner myometrium. It is also believed that glands can break through the serosa layer or muscle layer, which is formed by metaplasia of immature cells [9]. Uterine trauma caused by curettage, high estrogen stimulation and chronic endometritis may be the cause of AC [10]. The latest evidence showed that endometriosis was caused by repeated tissue damage and repair, platelet-induced epithelial-mesenchymal transition agent fibroblast transformation and fibrosis [11].

The patient went to hospital because of abdominal pain and vaginal bleeding. She had previously suffered from adenomyosis. Auxiliary examination indicated that adenomyosis might be caused by pelvic fluid, and the infection index was high. Therefore, abdominal pain and dysmenorrhea caused by inflammation were considered. After treatment, the patient's condition did not improve and hemoglobin gradually decreased. And then hemoperitoneum was considered. The patient underwent abdominal hysterectomy and bilateral adnexal resection. However, many gynecological diseases can cause hemoperitoneum, and those diseases have similar symptoms. It should be carefully identified.

Ectopic pregnancy and rupture of corpus luteum hematoma are common causes of hemoperitoneum in gynecological clinic [12]. It is not difficult to diagnose by combination of urine pregnancy test, blood human chorionic gonadotropin (HCG) determination and B-ultrasound. Malignant tumors, including endometrial malignant tumors, uterine sarcomas, choriocarcinoma and other malignant tumors, may cause vascular rupture and hemoperitoneum

if they erode into blood vessels. In addition, perforation of gastrointestinal tract, rupture of liver and spleen, and disorder of coagulation mechanism can also cause rupture of blood vessels and hemoperitoneum. The patient presented with lower abdominal pain and shock. There was no history of trauma, ulcer or hepatitis. Before operation, there were no fluid and gas levels in the abdominal cavity. Blood coagulation and platelets were normal, and no abnormality was found in the subphrenic, liver, spleen and gastrointestinal tract. Moreover, the ruptured fluid of chocolate cyst of ovary flows into the abdominal cavity, which stimulates the peritoneum. The symptoms of abdominal pain and peritoneum stimulation are obvious, and it will also lead to a small amount of bleeding in the abdominal cavity.

The patient's uterus was larger than that of the 5 months' pregnancy, the left posterior wall of the uterus had dark red mass bulge with a diameter of about 8 cm without breaking on the surface. The mass extended to the left uterine isthmus and parauterine region, the left adnexal region had dark red mass that was tightly adhered to the left posterior wall of the uterus and the left broad ligament. The mass was brittle and intact. During operation, the possibility of trophoblastic tumor rupture and bleeding was considered. However, blood HCG was negative before and after operation, and CA-125 was 521.40 U/mL. The postoperative histopathology suggested adenomyosis and endometriosis cyst. The common symptoms of adenomyosis are dysmenorrhea and increased menstrual cycles. Furthermore, there were other emergent conditions in women with endometriosis/adenomyosis [13]. Hemoperitoneum is rare, and misdiagnosis is caused by lack of rich clinical experience.

The site of active bleeding was near the corner of the posterior wall of the uterus. The serous layer of the uterus had a breach, and there was active bleeding. Uterine rupture and bleeding were considered due to severe erosion and destruction of ectopic endometrium. There are endometriosis cysts on the ovary, which coexist with adenomyosis. There was no bleeding in the ovarian cysts.

In conclusion, we report a case of woman with adenomyosis. Her uterus was enlarged and she was similar to a 5-month pregnant. Her uterus was irregular in shape, hard in texture and immobile in fixation. There was an area of about 6 cm in diameter in the myometrial wall of the lower part of the left uterine horn, which was purple blue. This area had dense adhesion with the left ovary. During operation, blood flowed from the left rear of the uterus. Because of the large size of the uterus and the inability to expose the bleeding site due to fixation, it was confirmed after operation that there was endometriosis focus near the left corner of the left posterior wall of the uterus. The focus penetrated the myometrium, and it led to active bleeding at this site.

The main treatment methods for adenomyosis include drug treatment and surgery. Once there is rupture or bleeding from eroded blood vessels, emergency surgical exploration is required. Hemoperitoneum caused by adenomyosis

is very rarely. It is difficult to diagnose before surgery, which needs the attention of clinicians and is misdiagnosed by leak-proof diagnosis.

Abbreviations

AD, Adenomyosis; CT, computed tomography; GHRH, Gonadotropin releasing hormone; HIFU, high intensity focused ultrasound; MRI, magnetic resonance imaging; UAE, uterine artery embolization; VAS, visual analogue score.

Author contributions

SZ was dedicated to the guarantor of integrity of the entire study, study concepts, study design, clinical studies, manuscript preparation and manuscript editing. LW, BY, SY contributed to the acquisition of data and the analysis and interpretation of data. QZ carried out the definition of intellectual content, manuscript preparation and manuscript review. YH was involved in the literature research and experimental studies. LY carried out the clinical studies, manuscript preparation, manuscript editing. All authors have read and approved this article.

Ethics approval and consent to participate

The patient signed informed consent. The study was conducted in accordance with the Declaration of Helsinki, and the protocol was approved by the Ethics Committee.

Acknowledgment

Not applicable.

Funding

This work was supported by Science Research Fund of Yunnan Education Department in 2020 (2020J0183), Science and Technology Project of the Second Affiliated Hospital of Kunming Medical University (No. 2018yk017) and the National Natural Science Foundation of China (No. 81960469).

Conflict of interest

The authors declare no conflict of interest.

References

- [1] Abbott JA. Adenomyosis and Abnormal Uterine Bleeding (AUB-A)-Pathogenesis, diagnosis, and management. *Best Practice & Research in Clinical Obstetrics & Gynaecology*. 2017; 40: 68–81.
- [2] Taran FA, Stewart EA, Brucker S. Adenomyosis: epidemiology, risk factors, clinical phenotype and surgical and interventional alternatives to hysterectomy. *Geburtshilfe Und Frauenheilkd*. 2013; 73: 924–931.
- [3] Niu Z, Chen Q, Sun Y, Feng Y. Long-term pituitary downregulation before frozen embryo transfer could improve pregnancy outcomes in women with adenomyosis. *Gynecological Endocrinology*. 2013; 29: 1026–1030.
- [4] Dueholm M, Aagaard J. Adenomyosis and IVF/ICSI treatment: clinical considerations and recommendations. *Expert Review of Endocrinology & Metabolism*. 2018; 13: 177–179.
- [5] Otsubo Y, Nishida M, Arai Y, Ichikawa R, Taneichi A, Sakanaka M. Association of uterine wall thickness with pregnancy outcome following uterine-sparing surgery for diffuse uterine adenomyosis. *Australian and New Zealand Journal of Obstetrics and Gynaecology*. 2016; 56: 88–91.
- [6] Hou Y, Qin Z, Fan K, Xu Y, Huang X. Combination therapeutic effects of high intensity focused ultrasound and Metformin for the treatment of adenomyosis. *Experimental and Therapeutic Medicine*. 2018; 15: 2104–2108.
- [7] Hiniker SM, Donaldson SS. Recent advances in understanding and managing rhabdomyosarcoma. *F1000 Prime Reports*. 2015; 7: 59.
- [8] Grimbizis GF, Mikos T, Tarlatzis B. Uterus-sparing operative treatment for adenomyosis. *Fertility and Sterility*. 2014; 101: 472–487.
- [9] Harada T, Khine YM, Kaponis A, Nikellis T, Decavalas G, Taniguchi F. The impact of adenomyosis on women's fertility. *Obstetrical and Gynecological Survey*. 2016; 71: 557–568.
- [10] Seikkula J, Niinimäki M, Suvitie P. Adenomyosis-diagnostic and therapeutic challenge. *Duodecim*. 2016; 132: 836–843.
- [11] Zhu B, Chen Y, Shen X, Liu X, Guo SW. Anti-platelet therapy holds promises in treating adenomyosis: experimental evidence. *Reproductive Biology and Endocrinology*. 2016; 14: 66.
- [12] Dong Weihong. Retrospective analysis of 165 cases of gynecological intraperitoneal hemorrhage. *Chinese and foreign medical treatment*. 2009; 28: 66–67.
- [13] Mabrouk M, Borghese G, Esposti ED, Raimondo D, Remorgida V, Arena A, *et al*. Acute abdominal pain in non-pregnant endometriotic patients: not just dysmenorrhoea. A systematic review. *Journal of Obstetrics and Gynaecology*. 2020; 21: 1–14.