

Anti-Müllerian hormone levels following laparoscopic ovarian cystectomy with subcutaneous abdominal wall lifting for ovarian endometriomas

Masataka Ono¹, Junya Kojima^{1,*}, Ei Hasegawa¹, Yotaro Takaesu^{1,2}, Toru Sasaki¹, Hiroataka Nishi¹

¹Department of Obstetrics & Gynecology, Tokyo Medical University, 6-7-1 Nishishinjuku, Shinjuku, Tokyo, Japan

²Department of Obstetrics & Gynecology, Social Welfare Foundation St. John Society Sakuramachi Hospital, 1-2-20 Sakuramachi, Koganei, Tokyo, Japan

*Correspondence: kojima_j@tokyo-med.ac.jp (Junya Kojima)

DOI: [10.31083/j.ceog.2021.01.5528](https://doi.org/10.31083/j.ceog.2021.01.5528)

This is an open access article under the CC BY-NC 4.0 license (<https://creativecommons.org/licenses/by-nc/4.0/>).

Submitted: March 08, 2020 Revised: August 14, 2020 Accepted: August 15, 2020 Published: February 15, 2021

Purpose of investigation: To examine changes in anti-Müllerian hormone (AMH) levels following laparoscopic ovarian endometriotic cystectomy with abdominal wall lifting. **Materials and methods:** This prospective cohort study analyzed 32 patients with endometriomas who underwent laparoscopic surgery between October 2014 and December 2016 in private and university hospitals. We measured blood AMH levels at baseline and at 1, 3, 6, and 9 months following a cystectomy. We also examined the correlations of AMH levels with age at time of surgery, bilateral cysts, cyst diameter, and Douglas fossa occlusion. Main outcome measures include the ovarian reserve based on AMH levels. **Results:** Compared to baseline (2.14 ± 1.66 ng/mL), AMH levels were significantly reduced at 1 (1.22 ± 1.08 ng/mL) and 3 (1.18 ± 1.02 ng/mL) months post-surgery. However, there were no significant differences between baseline and 6 (1.35 ± 1.02 ng/mL) or 9 (1.37 ± 0.95 ng/mL) months post-surgery. AMH levels were significantly reduced in patients aged ≥ 35 years (1.10 ± 0.98 versus 3.15 ± 1.85 ng/mL, $P = 0.001$), those with bilateral cysts (1.58 ± 0.98 versus 3.15 ± 1.85 ng/mL, $P = 0.006$), and those with pouch of Douglas occlusion (1.16 ± 0.90 versus 2.93 ± 1.60 ng/mL, $P = 0.002$). **Conclusions:** Abdominal wall lifting yielded the same AMH level changes as insufflation, suggesting that their effects on recurrence and preservation of the ovarian reserve following ovarian cystectomy are comparable. Abdominal wall lifting should be proactively considered when performing laparoscopic surgery for patients with endometriosis. If the ovarian reserve is preserved in the long term despite transient postoperative reduction in the ovarian reserve, physicians should consider surgery with consideration of postoperative artificial reproductive therapy for these patients who desire to have children.

Keywords

Cyst; Endometriosis; Fertility; Patients; Pouch

1. Introduction

Endometriosis, which occurs in 10% of women of child-bearing age, is a disease that causes dysmenorrhea and coital pain and markedly reduces women's quality of life. In addition, endometriosis is present in roughly 50% of women with unexplained infertility. It is commonly observed that inflammation plays a central role in the development and progression of endometriosis. The underlying condition is

an inflammatory process that leads to overproduction of inflammatory mediators such as prostaglandins, metalloproteinases, cytokines, and chemokines. In addition, reactive oxygen species (ROS) and oxidative stress (OS) promote the growth and adhesion of endometrial cells in the abdominal cavity, leading to the development of endometriosis and difficulty in menstruation and infertility. Recent studies have revealed possible roles for OS and ROS, with ROS in particular, increasing endothelial cell permeability and expression of adhesion molecules, causing inflammatory processes. It is suggested that the OS substance is involved in the pathogenesis of endometriosis by activating macrophages [1, 2]. Taking into consideration cyst diameter, symptoms such as dysmenorrhea, and the risk of malignant transformation, surgical treatment is often performed based on the definitive diagnosis reached [3, 4]. Severe cases of endometriosis also often involve complete occlusion of the pouch of Douglas and deeply infiltrating endometriosis (DIE), which is defined as endometriosis which penetrates ≥ 5 mm below the peritoneal surface. Such cases require not only cystectomy, but also opening of the pouch of Douglas and excision of DIE to the fullest extent. These procedures are intended to return the uterus and adnexa uteri to the anatomically correct positions while preserving their fertility-related function, alleviate menstrual pain, and improve quality of life.

According to many recent studies, cystectomy for endometriomas may reduce the ovarian reserve and negatively affect fertility [5]. Endometriomas are generally considered to cause more injury to the normal ovarian parenchyma than other benign ovarian cysts. However, one study has reported that endometriomas and other benign ovarian cysts do not differ significantly in terms of reduced postoperative ovarian reserve [6]. Furthermore, while several studies have examined the differences in the ovarian reserve based on age, cyst diameter, and bilateral cysts, no consensus has been reached [7–10]. The ovarian reserve refers to the maturation of fertilizable sperm by latent ovarian function and reserve capacity in female hormone production. Quantitative and qualita-

tive ovarian decline has been indicated as the primary cause of age-related fertility decline. Although the serum levels of follicle-stimulating hormone (FSH) have long been used as an indicator of age-related fertility decline, measurement is hindered by menstrual cycle-related fluctuations and by a lack of sensitivity. Indicators of the ovarian reserve include antral follicle count (AFC) which are measured with ultrasonography and inhibin B which are measured with blood. However, anti-Müllerian hormone (AMH) is now the most widely used marker of the ovarian reserve because it is easier to measure and is more universal. The AMH is not expressed by primordial follicles but is expressed by granulosa cells in the pre-antral follicles, which are further along in the growth process; beyond this point in the growth process, expression of AMH declines. Thus, AMH is considered to reflect the ovarian reserve. The AMH inhibits FSH-induced follicular development, granulosa cell development, and aromatase. Specifically, AMH is considered to regulate follicular development via its relationship with inhibin and activin. Levels of AMH do not fluctuate based on menstrual cycles and are unaffected by hormone preparations; these characteristics make AMH an excellent marker of the ovarian reserve that can be measured at any time [11, 12].

Surgery for endometriomas is often performed laparoscopically. Laparoscopic surgery requires the creation of space to secure an intraperitoneal visual field, which can be done with two different methods: insufflation and abdominal wall lifting. Insufflation involves obtaining a visual field by inflating the peritoneal cavity with CO₂ to extend the abdominal wall. However, insufflation is sometimes associated with various problems such as respiratory and circulatory problems induced by intraperitoneal pressure, increased blood pressure as a result of increased venous return, and tachycardia, arrhythmia, and oliguria secondary to hypercapnia and peritoneal irritation. Abdominal wall lifting, although it yields an inferior visual field compared to insufflation, offers two advantages. First, it does not use CO₂ and therefore has little effect on respiration or circulation. Second, it is highly economical [13–15]. There are four other advantages of abdominal wall lifting including: (i) blind operation is not involved because the treatment ports are created under direct vision; (ii) the visual field is stable because abdominal pressure does not decrease due to ventilation or aspiration; (iii) suture ligation is simple; and (iv) the resected organs can be removed easily through the treatment port. In previous studies on changes in the ovarian reserve following laparoscopic cystectomy, surgery was performed with insufflation. To date, no study has ever examined laparoscopic cystectomy with abdominal wall lifting. Therefore, we examined changes in AMH levels following laparoscopic endometriotic cystectomy with abdominal wall lifting.

2. Materials and methods

The subjects included patients with endometriomas who underwent laparoscopic surgery between October 2014 and

December 2016 at the Tokyo Medical University Hospital or its affiliated hospitals. All subjects provided informed consent. The subjects were women aged 18–45 years with a history of pregnancy. The desire to bear children (or lack thereof) was irrelevant to the present study. Exclusion criteria consisted of the following: history of adnexal surgery, hormonal therapy within the previous six months, endocrine disorders, and history of malignancies.

Endometrioid cysts were preoperatively diagnosed by an obstetrician-gynecologist based on a bimanual examination and vaginal ultrasonography (Sonovista 6.5 MHz probe, Konica Minolta, Inc., Tokyo, Japan). All surgeries were performed laparoscopically using abdominal wall lifting method. The patient was placed in a 20° reverse Trendelenburg lithotomy position under general anesthesia and tractioned upward in the mid-abdomen, using a 5 mm steel wire. Two procedure holes were made in the lateral abdomen using the open technique. Under observation using a 10 mm rigid laparoscope inserted through the procedure hole, additional sites for umbilical trocar insertion were made. After the cyst was aspirated, adhesions between the cyst wall and the pelvic wall or intestine was released. The incision was further extended to strip the cyst wall from the surrounding normal ovarian cortex as gently as possible after identifying the boundary between tumor and normal tissue. Post-cystectomy hemostasis was achieved with a simple ligation alone using Vicryl 000, without the use of a power source. Surgeries were performed by six different physicians. At baseline and at 1, 3, 6, and 9 months after surgery, levels of AMH in the blood were measured, and vaginal ultrasonography was performed. Within 15 minutes of blood collection, blood was centrifuged at 1800 rpm for 10 minutes, and the resulting serum was preserved at -80 °C. Levels of AMH in the collected samples were then measured using an AMH Gen II ELISA Kit (Beckman Coulter, Inc., Marseille, France).

We examined changes in AMH levels before and after surgery. We also examined the correlations of AMH levels with age at surgery, bilateral cysts, cyst diameter, and pouch of Douglas occlusion. Statistical analysis consisted of the Student's *t*-test and the Kruskal-Wallis test, with *P* < 0.05 considered statistically significant. The present study was approved the Tokyo Medical University Institutional Review Board (approval no: 2794). This study was conducted in accordance with the Declaration of Helsinki.

3. Results

3.1 Patient characteristics & surgical operations

The subjects consisted of 32 patients; all of whom were diagnosed with endometriosis by postoperative pathologic examination. Patients' characteristics are shown in Table 1. The subjects had a median age of 32 years and a median body mass index of 19.1 kg/m². Ten subjects were aged ≥ 35 years, whereas 22 subjects were aged < 35 years. Bilateral ovarian endometriotic cysts were present in 18 subjects. The median cyst diameter was 7 cm. Thirteen subjects presented with a

Table 1. Patient characteristics

N	32
Bilateral/Unilateral (cases)	18/14
Age \geq 35 yrs/< 35 yrs (cases)	10/22
\geq 7 cm/ < 7 cm	17/15
Closed/Open	13/19
Age (yrs) (mean \pm SD)	31.7 (\pm 5.3)
BMI (kg/m ²) (mean \pm SD)	19.6 (\pm 3.0)
Cyst diameter (mm) (mean \pm SD)	6.5 (\pm 1.4)
rASRM score (mean \pm SD)	68.4 (\pm 40.8)
Operative time (min) (mean \pm SD)	128.2 (\pm 49.4)
Blood loss (mL) (mean \pm SD)	206.5 (\pm 293.3)
Preoperative AMH (ng/mL) (mean \pm SD)	2.14 (\pm 1.66)
Preoperative FSH (mIU/mL) (mean \pm SD)	4.41 (\pm 5.94)

rASRM: revised American Society for Reproductive Medicine guidelines; AMH: anti-Müllerian hormone; FSH: follicle-stimulating hormone.

completely occluded pouch of Douglas and a frozen pelvis. Three of the 32 subjects dropped out of the study because they were transferred to other hospitals. The median surgical time was 129 minutes, and the median intraoperative blood loss was 120 mL.

Intraoperative findings are shown on the Table 2.

All of the 32 cases had cyst formation on either side or both sides of the ovaries and 18 cases were bilateral. Peritoneal lesions such as red, white, and black were present in 23 cases, and DIE was present in 13 cases. In all cases of deep endometriosis and obstruction of the Douglas fossa, the deep endometriosis was excised, and the Douglas fossa was freed except in one case. In one case, the patient's family did not consent for the surgical invasion, so we limited to excision of the ovarian cyst.

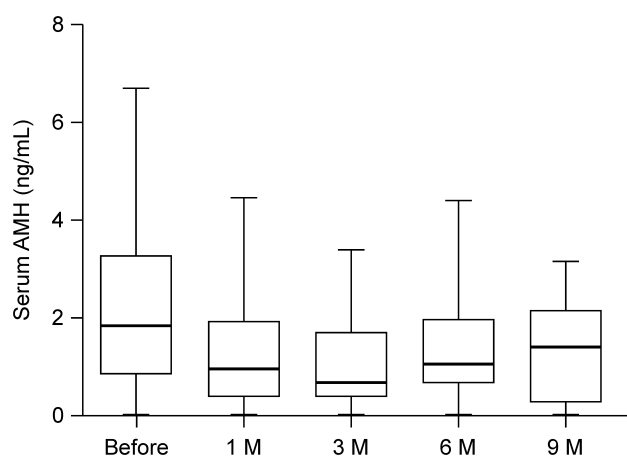


Fig. 1. Compared to baseline, AMH levels were significantly reduced at 1 month and 3 months post-surgery. From 3 months onward, AMH levels recovered in some patients and did not differ significantly from baseline at 6 months or 9 months.

Table 2. Surgical operations

CASE	ASRM	Frozen Pelvic*1	Peritoneal lesion	Adhesion*2
NO.1	40	±	+	mild
NO.2	148	+	+	strong
NO.3	20	-	+	mild
NO.4	74	±	-	mild
NO.5	40	-	+	mild
NO.6	116	+	+	strong
NO.7	38	-	+	mild
NO.8	118	+	+	strong
NO.9	82	-	+	strong
NO.10	108	+	+	strong
NO.11	33	-	+	none
NO.12	37	±	+	mild
NO.13	36	±	-	mild
NO.14	52	-	+	mild
NO.15	27	-	-	none
NO.16	52	±	-	mild
NO.17	104	+	+	strong
NO.18	55	-	-	mild
NO.19	100	+	+	strong
NO.20	29	±	+	mild
NO.21	46	-	+	strong
NO.22	136	+	+	strong
NO.23	158	+	+	strong
NO.24	36	-	-	strong
NO.25	58	-	+	strong
NO.26	148	+	+	strong
NO.27	52	-	+	mild
NO.28	44	-	+	mild
NO.29	24	-	-	mild
NO.30	48	-	-	mild
NO.31	78	±	+	strong
NO.32	58	-	+	strong

*1 Cases with complete closure of the Douglas fossa were marked as + and those with semi-closed fossa were marked as ±.

*2 The degree of adhesion is described based on the ASRM classification.

Strong adhesions of more than two-thirds of the tubes or ovaries were defined as severe, and other adhesions were defined as mild.

3.2 Postoperative levels of AMH

Fig. 1 shows changes in AMH levels. The Kruskal-Wallis test revealed significant differences ($P < 0.05$) in AMH levels at baseline and at 1, 3, 6, and 9 months after surgery; therefore, we performed multiple comparisons. All subjects demonstrated a transient or consistent decrease in AMH levels after surgery. Compared to baseline (2.14 ± 1.66 ng/mL), AMH levels were significantly reduced at 1 month (1.22 ± 1.08 ng/mL) and 3 months (1.18 ± 1.02 ng/mL) postoperatively. From 3 months onward, AMH levels recovered in some patients and did not differ significantly from baseline at 6 months (1.35 ± 1.02 ng/mL) or 9 months (1.37 ± 0.95 ng/mL).

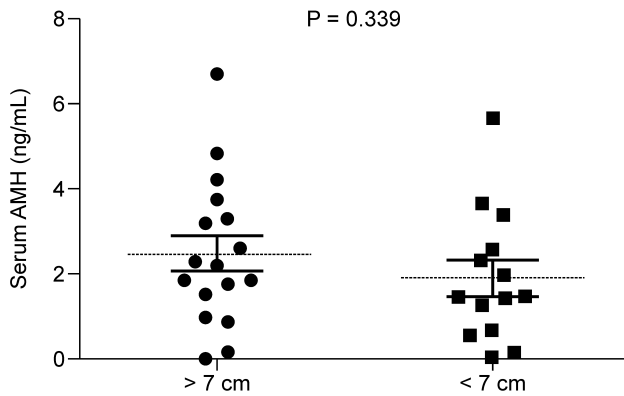


Fig. 2. The figure shows the comparisons of AMH levels at baseline. No significant difference was observed in AMH levels at baseline based on cyst diameter ($P > 0.05$).

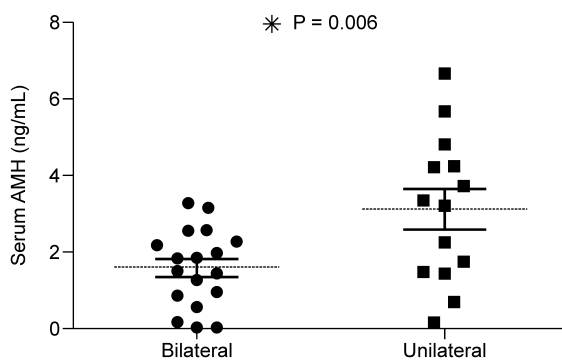


Fig. 3. Comparisons based on the presence of bilateral cysts revealed that baseline AMH levels were significantly lower among patients with bilateral cysts ($P = 0.006$).

3.3 Comparisons of AMH levels based on clinical factors

We examined the correlations of AMH levels with age at surgery, bilateral cysts, cyst diameter, and pouch of Douglas occlusion. For comparisons based on cyst diameter, subjects with a cyst diameter ≥ 7 cm were defined as the large cyst group; however, no significant difference was observed in AMH levels at baseline based on cyst diameter as shown in Fig. 2 (2.46 ± 1.67 versus 2.05 ± 1.54 ng/mL, $P = 0.339$). Comparisons based on the presence of bilateral cysts revealed that baseline AMH levels were significantly lower among subjects with bilateral cysts as shown in Fig. 3 (1.58 ± 0.98 versus 3.15 ± 1.85 ng/mL, $P = 0.006$). For comparisons based on age, subjects aged ≥ 35 years at surgery were considered older. AMH levels were significantly lower among older subjects as shown in Fig. 4 (1.10 ± 0.98 versus 3.15 ± 1.85 ng/mL, $P = 0.001$). Patients with pouch of Douglas occlusion (as determined in laparoscopic findings during surgery) had significantly lower AMH levels than patients without pouch of Douglas occlusion as shown in Fig. 5 (1.16 ± 0.90 versus 2.93 ± 1.60 ng/mL, $P = 0.002$). We similarly compared the AMH levels based on clinical factors after surgery. Comparisons of cyst diameter revealed no sig-

nificant differences at any time point postoperatively. Comparisons based on the presence of bilateral cysts and age at surgery showed that AMH levels were significantly lower among subjects with bilateral cysts and among older subjects at 6 months post-operatively; however, these significant differences disappeared by 9 months. Subjects with pouch of Douglas occlusion displayed significantly lower postoperative AMH levels than those without occlusion, but the significant difference disappeared from 6 months onward.

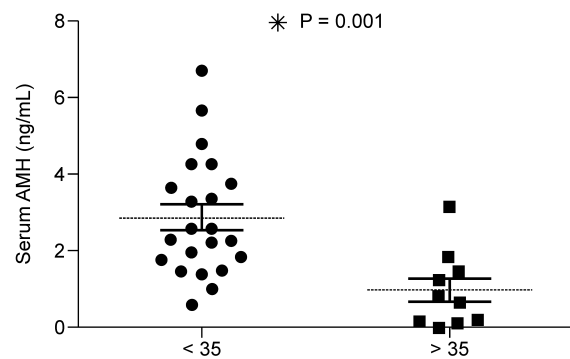


Fig. 4. This figure shows an age-based comparison. Patients who were aged ≥ 35 years at the time of surgery were defined as older subjects. AMH levels were significantly lower among older patients ($P = 0.001$).

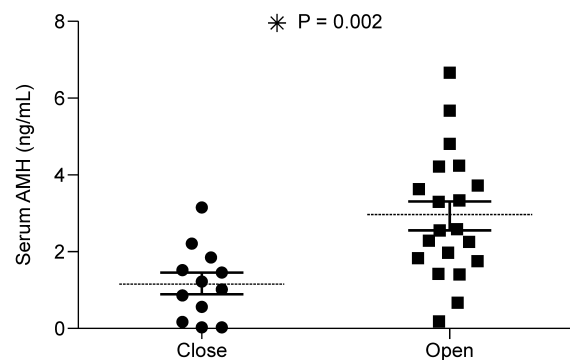


Fig. 5. Assessment of Douglas obstruction was determined by laparoscopic findings during surgery. Patients with pouch of Douglas occlusion had significantly lower AMH levels than patients without pouch of Douglas occlusion ($P = 0.002$).

4. Discussion

Several studies have reported on the ovarian function after cystectomy in patients with ovarian endometriomas. However, previous studies involved insufflation; and none of them included analyses of abdominal wall lifting [16–21]. One previous study that used insufflation yielded results similar to the present study in terms of patient characteristics such as age and body mass index [22]. However, we did not limit our subjects to infertile women; as a result, our study included many severe cases of endometriosis, and approxi-

mately 40% of the patients presented with a frozen pelvis. In the present study, subjects were observed for a median period of 27.3 months following surgery. We collected blood and conducted ultrasonography until 9 months post-surgery and continued to conduct ultrasonography afterwards to monitor for recurrence. Among our 32 subjects, three dropped out of the study because they transferred to other hospitals. Defining postoperative recurrence of endometrioma as the formation of a cyst ≥ 2 cm in diameter, Vercellini *et al.* examined the rates of postoperative recurrence at 36 months in 27 cases of excision of endometriomas. The postoperative rate of recurrence was 8% among patients who underwent postoperative low-dose estrogen-progestin (LEP) treatment versus 45% among patients who did not undergo LEP [23]. In the present study, using the same definition for recurrence, we found that recurrence was prevented in 11 subjects receiving postoperative dienogest or LEP. Although recurrence was not observed during postoperative hormone therapy, two patients who did not undergo recurrence prevention demonstrated postoperative recurrence. Previous studies have reported ovarian chocolate cyst recurrence rates of 12%-30% at 2-5 years post-operatively [24–29]. Although the present study established a short postoperative observation period, our results were relatively favorable compared to previous studies. Spontaneous pregnancy occurred shortly after surgery in four of the 10 subjects who desired to bear children. However, the desire to bear children was not examined in the present study, and our spontaneous pregnancy rate was lower than that in previous studies.

After surgery, levels of AMH decreased transiently or consistently; these levels were significantly lower at 1 and 3 months post-surgery compared to baseline but they subsequently recovered, which was comparable to previous findings that used insufflation. Previous studies have also reported that bilateral cysts and advanced age (≥ 33 years) are risk factors for a diminished ovarian reserve. The present study found significantly lower AMH levels in association with advanced age, pelvic occlusion, and bilateral cysts. However, at 9 months, AMH levels did not differ significantly in any clinical factor. In all cases, significant differences in postoperative AMH levels compared to baseline disappeared from 6 months onward. These results suggested that abdominal wall lifting prevented complete breakdown of the ovarian reserve, even in patients with further risk factors in previous studies, thereby indicating that the ovarian reserve can be preserved in the longer term. When performing cystectomy for patients with endometriosis who are aged ≥ 35 years, who are suspected to have bilateral cysts and an occluded pouch of Douglas, and desire to become pregnant, physicians must sufficiently explain the potential for irreversible damage to the ovarian reserve and consider operability carefully.

Concerning pelvic occlusion, while a previous study reported a significant decline in the ovarian reserve based on the American Society for Reproductive Medicine classification of endometriosis, the present study found that the ovar-

ian reserve was significantly lower from baseline to 3 months in patients with pelvic occlusion [5]. In severe cases of endometriosis in which the pelvis is completely occluded, ovarian cysts generally adhere strongly to the posterior uterine wall or the pelvic floor [3, 4, 22]. The management of DIE by medication is not curative but used chiefly to alleviate symptoms and often causes serious side effects. It is not clear whether the medicine prevents disease progression, especially in severe endometriosis such as symptomatic DIE with colorectal dilation. Since the discontinuation of this treatment generally causes a recurrence, it can be argued that surgical management is the main treatment for severe endometriosis. Regardless of the location of endometriotic lesions such as endometrioma, peritoneal endometriosis, DIE, the most important therapeutic strategy is complete excision of the implant and preservation of normal tissue [30, 31]. Improving dysmenorrhea requires resection of cysts, resection of DIE, and opening of the pouch of Douglas. In these procedures, adhesion and detachment of the cyst wall may trigger injury in healthy ovarian tissue and interrupt blood flow around the hilum of the ovary. In light of previous studies reporting that excision of DIE improves outcomes in ART for patients with severe endometriosis who desire to bear children, the results of the present study indicate that if the decline in the ovarian reserve is only transient, the physician should consider the option of surgery with consideration of postoperative ART despite the decline in AMH levels [3, 4, 22].

With regard to coagulation in healthy ovarian tissue following cystectomy, several studies have stated that postoperative ovarian reserve was better preserved in patients who only had suturing than in patients who underwent bipolar coagulation or other forms of thermocoagulation [16–21]. Abdominal wall lifting is performed in a manner similar to laparotomy and is thus performed with the same instruments used in laparotomy. Post-cystectomy coagulation is achieved with sutures alone without the use of a power source (such as bipolar coagulation) or specific bio-based products because suturing can be performed easily. In all cases in the present study, we performed subcutaneous abdominal wall lifting and achieved coagulation with simple ligation alone to protect the postoperative ovarian reserve.

This study has several limitations. First, the present study did not directly compare abdominal wall lifting with insufflation, thus preventing us from commenting on the superiority of abdominal wall lifting. Second, we did not limit subjects to infertile women, thus preventing us from discussing postoperative pregnancy rates or numbers of eggs collected. In the future, we intend to include a larger number of cases and conduct investigations limited to specific groups of participants, such as infertile women, patients with certain symptoms, and obese patients. By doing so, we hope to further examine the utility and efficacy of abdominal wall lifting compared to insufflation.

5. Limitation

There is some evidence in the literature that suggests suture ligation alone results in better ovarian reserve. However, because surgery in our hospital was performed using only the wall lifting method, we could not directly compare this method with insufflation methods.

Unfortunately, we could not recruit the planned number of cases within the study period, thus limiting the sample size. A larger prospective study is required to confirm the present findings.

6. Conclusions

In conclusion, in the present study, AMH levels transiently decreased postoperatively but improved from 6 months onwards to the point that they were no longer significantly different from baseline. Abdominal wall lifting in ovarian cystectomy results in the same changes in AMH levels as insufflation and is thus considered to be comparable with insufflation in terms of recurrence and protection of postoperative ovarian reserve. Although laparoscopic surgery is generally minimally invasive, it is more expensive than laparotomy owing to the use of disposable products and power sources. Most instruments used in abdominal wall lifting are cheap and reusable, and abdominal wall lifting does not require expensive insufflators, thus making it evidently superior to insufflation in terms of health care costs. Based on economics and minimal invasiveness in anesthesia management, abdominal wall lifting should be proactively considered when performing laparoscopic surgery for patients with endometriosis.

Author contributions

MO, JK and EH designed the research study. MO, EH, YT performed the research. YT, TS provided help and advice on the ELISA experiments. MO, JK analyzed the data. MO, JK and HN wrote the manuscript. All authors contributed to editorial changes in the manuscript. All authors read and approved the final manuscript.

Acknowledgment

Funding for the present study was provided by Tokyo Medical University.

Conflict of interest

The authors declare no competing interests.

References

- [1] Vitale SG, Capriglione S, Peterlunger I, La Rosa VL, Vitagliano A, Noventa M, *et al.* The role of oxidative stress and membrane transport systems during endometriosis: a fresh look at a busy corner. *Oxidative Medicine and Cellular Longevity*. 2018; 2018: 1-14.
- [2] Laganà AS, Vitale SG, Salmeri FM, Triolo O, Ban Frangež H, Vrtačnik-Bokal E, *et al.* Unus pro omnibus, omnes pro uno: a novel, evidence-based, unifying theory for the pathogenesis of endometriosis. *Medical Hypotheses*. 2017; 103: 10-20.
- [3] Douay-Hauser N, Yazbeck C, Walker F, Luton D, Madelenat P, Koskas M. Infertile women with deep and intraperitoneal endometriosis: comparison of fertility outcome according to the extent of surgery. *Journal of Minimally Invasive Gynecology*. 2011; 18: 622-628.
- [4] Bianchi PHM, Pereira RMA, Zanatta A, Alegretti JR, Motta ELA, Serafini PC. Extensive excision of deep infiltrative endometriosis before in vitro fertilization significantly improves pregnancy rates. *Journal of Minimally Invasive Gynecology*. 2009; 16: 174-180.
- [5] Shebl O, Ebner T, Sommergruber M, Sir A, Tews G. Anti müllerian hormone serum levels in women with endometriosis: a case-control study. *Gynecological Endocrinology*. 2009; 25: 713-716.
- [6] Kwon SK, Kim SH, Yun S, Kim DY, Chae HD, Kim C, *et al.* Decline of serum antimüllerian hormone levels after laparoscopic ovarian cystectomy in endometrioma and other benign cysts: a prospective cohort study. *Fertility and Sterility*. 2014; 101: 435-441.
- [7] Hirokawa W, Iwase A, Goto M, Takikawa S, Nagatomo Y, Nakahara T, *et al.* The post-operative decline in serum anti-Müllerian hormone correlates with the bilaterality and severity of endometriosis. *Human Reproduction*. 2011; 26: 904-910.
- [8] Celik HG, Dogan E, Okyay E, Ulukus C, Saatli B, Uysal S, *et al.* Effect of laparoscopic excision of endometriomas on ovarian reserve: serial changes in the serum antimüllerian hormone levels. *Fertility and Sterility*. 2012; 97: 1472-1478.
- [9] Hwu Y, Wu F, Li S, Sun F, Lin M, Lee R. The impact of endometrioma and laparoscopic cystectomy on serum anti-Müllerian hormone levels. *Reproductive Biology and Endocrinology*. 2011; 9: 80.
- [10] Taniguchi F, Sakamoto Y, Yabuta Y, Azuma Y, Hirakawa E, Nagira K, *et al.* Analysis of pregnancy outcome and decline of anti-Müllerian hormone after laparoscopic cystectomy for ovarian endometriomas. *Journal of Obstetrics and Gynaecology Research*. 2016; 42: 1534-1540.
- [11] Tsepelidis S, Devreker F, Demeestere I, Flahaut A, Gervy C, Englert Y. Stable serum levels of anti-Müllerian hormone during the menstrual cycle: a prospective study in normo-ovulatory women. *Human Reproduction*. 2007; 22: 1837-1840.
- [12] Seifer DB, Maclaughlin DT. Müllerian Inhibiting Substance is an ovarian growth factor of emerging clinical significance. *Fertility and Sterility*. 2007; 88: 539-546.
- [13] Uen Y, Chen Y, Kuo C, Wen K, Koay L. Randomized trial of low-pressure carbon dioxide-elicited pneumoperitoneum versus abdominal wall lifting for laparoscopic cholecystectomy. *Journal of the Chinese Medical Association*. 2007; 70: 324-330.
- [14] Ogihara Y, Isshiki A, Kindscher JD, Goto H. Abdominal wall lift versus carbon dioxide insufflation for laparoscopic resection of ovarian tumors. *Journal of Clinical Anesthesia*. 1999; 11: 406-412.
- [15] Uen Y, Liang A, Lee H. Randomized comparison of conventional carbon dioxide insufflation and abdominal wall lifting for laparoscopic cholecystectomy. *Journal of Laparoendoscopic & Advanced Surgical Techniques*. 2002; 12: 7-14.
- [16] Beretta P, Franchi M, Ghezzi F, Busacca M, Zupi E, Bolis P. Randomized clinical trial of two laparoscopic treatments of endometriomas: cystectomy versus drainage and coagulation. *Fertility and Sterility*. 1998; 70: 1176-1180.
- [17] Fedele L, Bianchi S, Zanconato G, Bergamini V, Berlanda N. Bipolar electrocoagulation versus suture of solitary ovary after laparoscopic excision of ovarian endometriomas. *The Journal of the American Association of Gynecologic Laparoscopists*. 2004; 11: 344-347.
- [18] Muzii L, Bellati F, Bianchi A, Palaia I, Mancini N, Zullo MA, *et al.* Laparoscopic stripping of endometriomas: a randomized trial on different surgical techniques. Part II: pathological results. *Human Reproduction*. 2005; 20: 1987-1992.
- [19] Pellicano M, Bramante S, Guida M, Bifulco G, Di Spiezio Sardo A, Cirillo D, *et al.* Ovarian endometrioma: postoperative adhesions following bipolar coagulation and suture. *Fertility and Sterility*. 2008; 89: 796-799.

- [20] Coric M, Barisic D, Pavicic D, Karadza M, Banovic M. Electrocoagulation versus suture after laparoscopic stripping of ovarian endometriomas assessed by antral follicle count: preliminary results of randomized clinical trial. *Archives of Gynecology and Obstetrics*. 2011; 283: 373-378.
- [21] Ata B, Turkgeldi E, Seyhan A, Urman B. Effect of hemostatic method on ovarian reserve following laparoscopic endometrioma excision; comparison of suture, hemostatic sealant, and bipolar desiccation. A systematic review and meta-analysis. *Journal of Minimally Invasive Gynecology*. 2015; 22: 363-372.
- [22] Ballester M, Oppenheimer A, Mathieu d'Argent E, Touboul C, Antoine J, Nisolle M, *et al*. Deep infiltrating endometriosis is a determinant factor of cumulative pregnancy rate after intracytoplasmic sperm injection/in vitro fertilization cycles in patients with endometriomas. *Fertility and Sterility*. 2012; 97: 367-372.e3.
- [23] Vercellini P, Somigliana E, Daguati R, Vigano P, Meroni F, Crosignani PG. Postoperative oral contraceptive exposure and risk of endometrioma recurrence. *American Journal of Obstetrics and Gynecology*. 2008; 198: 504.e1-5.
- [24] Busacca M, Marana R, Caruana P, Candiani M, Muzii L, Calia C, *et al*. Recurrence of ovarian endometrioma after laparoscopic excision. *American Journal of Obstetrics and Gynecology*. 1999; 180: 519-523.
- [25] Saleh A, Tulandi T. Reoperation after laparoscopic treatment of ovarian endometriomas by excision and by fenestration. *Fertility and Sterility*. 1999; 72: 322-324.
- [26] Ghezzi F, Beretta P, Franchi M, Parisis M, Bolis P. Recurrence of ovarian endometriosis and anatomical location of the primary lesion. *Fertility and Sterility*. 2001; 75: 136-140.
- [27] Jones KD, Sutton CJG. Recurrence of chocolate cysts after laparoscopic ablation. *The Journal of the American Association of Gynecologic Laparoscopists*. 2002; 9: 315-320.
- [28] Vercellini P, Chapron C, De Giorgi O, Consonni D, Frontino G, Crosignani PG. Coagulation or excision of ovarian endometriomas? *American Journal of Obstetrics and Gynecology*. 2003; 188: 606-610.
- [29] Koga K, Takemura Y, Osuga Y, Yoshino O, Hirota Y, Hirata T, *et al*. Recurrence of ovarian endometrioma after laparoscopic excision. *Human Reproduction*. 2006; 21: 2171-2174.
- [30] Laganà AS, Vitale SG, Trovato MA, Palmara VI, Rapisarda AM, Granese R, *et al*. Full-thickness excision versus shaving by laparoscopy for intestinal deep infiltrating endometriosis: rationale and potential treatment options. *BioMed Research International*. 2016; 2016: 3617179.
- [31] Raffaelli R, Garzon S, Baggio S, Genna M, Pomini P, Laganà AS, *et al*. Mesenteric vascular and nerve sparing surgery in laparoscopic segmental intestinal resection for deep infiltrating endometriosis. *European Journal of Obstetrics & Gynecology and Reproductive Biology*. 2018; 231: 214-219.