

# Office hysteroscopy in cases of recurrent implantation failure; Do or not to do

M. Elmahdy<sup>1,\*</sup>, I. Elfourtia<sup>2</sup>, H. Maghraby<sup>1</sup>

<sup>1</sup>Alexandria University, Obstetrics and Gynecology Department, Alexandria (Egypt)

<sup>2</sup>Libya Ministry of Health, Misurata (Libya)

## Summary

**Objective:** To assess the management and outcome of office hysteroscopy in patients experiencing recurrent implantation failure (RIF) with two or more intra cytoplasmic sperm injection (ICSI) failures. **Study design:** The prospective study was conducted at Elshatby maternity university hospital and Misrata National Center for Infertility, Misrata, Libya. One hundred and seventy-five female patients aged below 40 years and with 2 or more previous ICSI failures, with  $\geq 2$  fresh embryos transferred per attempt were included in the study. Office hysteroscopy was done in all patients to assess the endometrial cavity for any abnormal uterine findings and clinical pregnancy rate after hysteroscopy was evaluated. At the end of hysteroscopy, endometrial biopsy was done to observe prevalence of any different inflammatory cells, plasma cells or lymphocytes. **Results:** Out of 175 patients, 135 had abnormal hysteroscopic findings with single and combined pathologies. Endometritis 43 (65%) and septum with endometritis 34 (49%) were the most common pathologies observed. After office hysteroscopy, 13 (19.6%) women with single pathology and 13 (18.8%) women with combined pathologies became pregnant. Of the 175 patients studied, pregnancies occurred in 33 (18.8%) women with two or more ICSI failures after corrected endometrial pathology by hysteroscopy. **Conclusion:** Office hysteroscopy is a good diagnostic and therapeutic tool in cases of recurrent implantation failure. It has the potential to improve pregnancy rate in these patients.

**Key words:** Recurrent implantation failure; Office hysteroscopy; ICSI failures; Clinical pregnancy.

## Introduction

Recurrent implantation failure (RIF) is defined as failure to achieve pregnancy after transfer of good quality embryos in women below 40 years following several in vitro fertilization (IVF) treatment cycles [1]. RIF may be due to declined endometrial receptivity, defective embryonic development, acquired thrombophilia (i.e. antiphospholipid syndrome) and other factors such as endometriosis, hydrosalpinx and myomas distorting the uterine cavity [2]. Factors which might cause defective endometrial receptivity include uterine polyps, septa, leiomyomata, adhesions and thin endometrium [3-7].

Hysteroscopy is the gold standard technique for diagnosis of intrauterine macroscopic lesions. When ultrasound, saline infusion sonography, and hysteroscopy for endometrial pathology were compared, the relative sensitivities and specificities were 89% and 56%, 91.8% and 60%, and 97.3% and 92%, respectively [5, 6]. Ultrasound is more effective in evaluating myometrial and extramural uterine disease such as type III-VII fibroids and ovarian diseases, but is less sensitive with cornual disease, sessile polyps, intrauterine adhesions, and chronic endometritis. Three-dimensional ultrasound is more sensitive and specific than transvaginal and saline infusion sonography, identifying 100% of submucosal myomas and müllerian anomalies. It is still of lower sensitivity and specificity for polyps (61.1% and 91.5%, respectively) relative to hysteroscopy [7].

Several approaches were tried to improve outcome of IVF in RIF patients such as low molecular weight heparin, immunotherapy with intravenous immunoglobulin (IVIG), assisted hatching, endometrial stimulation and office hysteroscopy [3, 8]. Transvaginal ultrasound guided embryo transfer may significantly increase the percentage of pregnancies per transfer [9].

Office hysteroscopy is a well-tolerated outpatient procedure that can diagnose uterine cavity and endometrial pathology and is considered to be the gold standard for evaluating the endometrial cavity [10]. It is used to correct abnormalities in the uterine cavity in order to improve the pregnancy rates. Intrauterine pathology affects reproductive outcomes, and advances in technology allow many opportunities for better diagnosis and management through office hysteroscopy [11]. Office hysteroscopy may be a method of endometrial scratch. Endometrial scratch may be beneficial in RIF patients to increase the odds of implantation, clinical pregnancy and live birth rate. Endometrial scratch is a type of endometrial injury during hysteroscopy using instruments such as grasper forceps. There is no specific time for this procedure. Most of the publications were in the preceding luteal phase. Till now there is no solid conclusion on its efficacy [10, 12]. The current study aimed to assess the role of office hysteroscopy in the diagnosis and management of the cause of RIF and its impact on pregnancy rate.

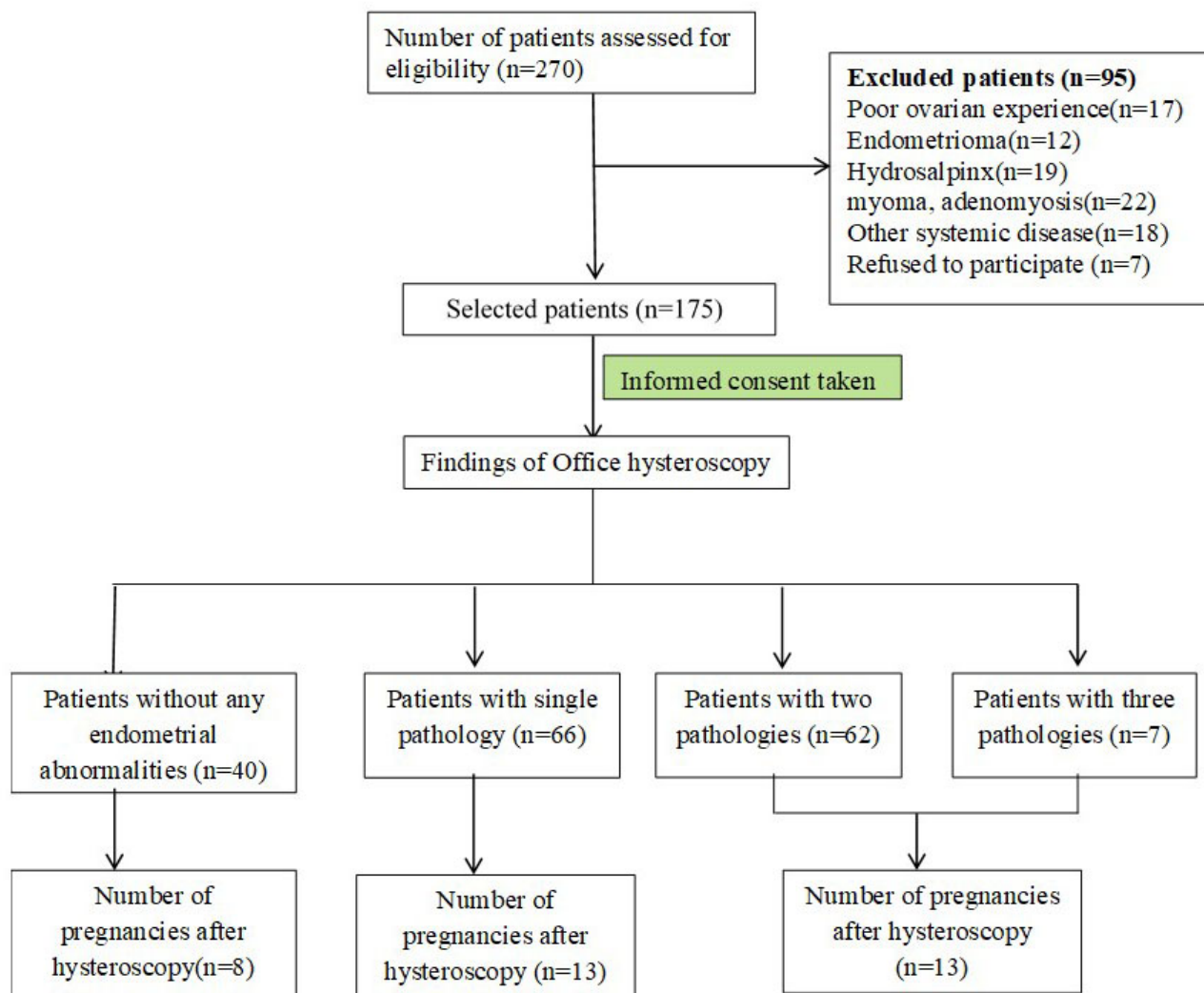


Figure 1. — Flow chart.

## Materials and Methods

### Study design

The study was a prospective observational study.

### Study settings

The study was conducted at Elshatby maternity university hospital, Alexandria, Egypt and Misrata National Center for infertility, Misrata, Libya. from April 2016-January 2018.

### Sample size

All cases fulfilling the inclusion criteria attending the IVF center in both study locations and accepting to enter in the study during the period from April 2016-January 2018.

### Participants

Female patients of age below 40 years, with 2 or more previous intra cytoplasmic sperm injection (ICSI) failures and with  $\geq 2$  good fresh embryos transferred per attempt were included in the study. Patients with poor ovarian response (POR) diagnosed by Bologna criteria [13],

endometrioma, hydrosalpinx, myoma, adenomyosis, any other systemic disease and those who had not given consent were excluded from the study. A total 175 female patients were eligible for this study and were enrolled after receiving informed consent.

Prior to hysteroscopy all patients enrolled in the study were subjected to a gynecologic examination, followed by a speculum, smear and swab when indicated. A detailed 2D ultrasound, sagittal and transverse views, was done. When polyps were visualized with 2D ultrasound, additional saline infusion sonography was performed when indicated to confirm the diagnosis and verify the site of polyp attachment. Uterine dimensions, endometrial thickness and nature, the incidence of uterine cavity abnormalities, polyps, fluid, septum, wall abnormalities, presence of fibroids, adenomyosis, uterine wall thickness and midline thickness and body/cervix ratio were recorded. Sonohysterogram was ordered when needed.

Table 1. — Baseline clinical and hormonal profile of the patients.

Parameters	Values (n = 175)
Mean age (years) ± SD	34.4 ± 4.6
E2 levels on basal day 3 (pg/mL)	46.1 ± 35.6
AMH (pmol/L)	3.3 ± 3.2
FSH (IU/L)	7.7 ± 3.4
LH (IU/L)	5.4 ± 2.4
Prolactin (IU/L)	18.7 ± 14
TSH (IU/mL)	2.7 ± 2.2

Table 2. — Pregnancy in single pathologies after office hysteroscopy.

Hysteroscopic findings	Number of cases (%)	Number of pregnant (%)
Endometritis	43 (65%)	7 (16.3%)
U1*	3 (4.5%)	1 (33.3%)
U2a*	10 (15%)	4 (26.7%)
U3a*	2 (3%)	0 (0%)
Polyp	4 (6%)	0 (0%)
Adhesions	4 (6%)	1 (20%)
Total	66 (100%)	13 (19.6%)

U1 = Dysmorphic uterus, U2a = partial septate uterus, U3a = partial bicorporeal uterus  
 $\chi^2 = 3.15, p = 0.676$

Table 3. — Pregnancy in combined pathologies after office hysteroscopy.

Findings	Number of cases (%)	Number of pregnant (%)
Septum U2a + endometritis	34 (49%)	10 (29.4%)
Septum U3 + endometritis	3 <sup>a</sup> (4%)	1 (33.3%)
Polyp + Septum U2a	11 (15%)	1 (9.9%)
Polyp + endometritis	14 (20%)	1 (7.1%)
Three	7 (10.4%)	0 (0%)
Total	69 (100%)	13 (18.8%)

U2a = partial septate uterus, U3a = partial bicorporeal uterus, U3c = bicorporeal septate uterus;  
<sup>a</sup>2 cases are with U3a, 1 case with U3c;  $\chi^2 = 4.59, p = 0.333$

Routine investigations for complete blood count, liver and kidney profile, screening for virus (hepatitis B surface antigen, hepatitis C antibody and HIV antibody) and hormones (AMH, FSH, E2, thyroid hormones) were obtained.

The hysteroscopies were done in the follicular phase of the menstrual cycle, 1-3 months before starting the ICSI cycle. All hysteroscopic examinations were performed by two experienced gynecologists (IF, HM), using a 5 mm outer diameter continuous flow Bettocchi hysteroscope with a 30° angle (Karl Storz Endoscopy, Stöpler Medical Instruments, Utrecht, The Netherlands & Olympus Belgium N.V., Aartselaar, Belgium). Uterine cavity distension was achieved

by using normal saline solution at the pressure of 120-150 mmHg. The hysteroscopy procedures were performed in an operative theatre setting. The hysteroscope was introduced under vision without dilatation using the vaginoscopic approach without anesthesia.

At the end of hysteroscopy, an endometrial biopsy was obtained using a sharp curette oriented to the location that revealed pathology during the hysteroscopy. Anterior, posterior and lateral walls were also gently curetted. These biopsies were fixed in 4% phosphate buffered formaldehyde solution and processed routinely into hematoxylin and eosin (HE) stained slides. An observation of abnormal prevalence of different inflammatory cells, plasma cells or lymphocytes destructing the endometrial tubuli was suggestive of chronic endometritis.

### Statistical Analysis

Data were fed to the computer and analyzed using IBM SPSS software package version 20.0. (Armonk, NY: IBM Corp) Qualitative data were described using numbers and percents. The Kolmogorov-Smirnov test was used to verify the normality of distribution. Quantitative data were described using range (minimum and maximum), mean, standard deviation and median. The Chi-square test was used to compare categorical variables. Significance of the obtained results was judged at the 5% level.

### Results

The study consisted of 175 subjects with RIF. Eligibility and follow up of the cases is illustrated in the flowchart (Figure 1). The frequency of ICSI failures was 2 in 98 patients, 3 in 36 patients, 4 in 24 patients and more than 4 in 17 patients. The patient's characteristics including mean age, levels of estradiol (E2) on basal day 3, anti-mullerian hormone (AMH), follicle stimulating hormone (FSH), leutinizing hormone (LH), prolactin and thyroid stimulating hormone (TSH) are presented in Table 1.

The frequency of overall pathological findings was 78.3%. Out of 175, 40 (22.8%) patients (This adds up to 101.1% so needs clarification) did not show any abnormal findings on hysteroscopy. Of these 8(20%) women with correct endometrial pathology became pregnant after hysteroscopy. Sixty-six (37.7%) patients were noted to have endometritis, septum, polyp and adhesions while 69 (39.4%) had combined abnormalities. Endometritis 43 patients (65%) and partial septate uterus (U2a) 10 patients (15%) were the most common hysteroscopic abnormalities observed with 13 (19.6%) women becoming pregnant after office hysteroscopy (Table 2).

Table 3 describes the incidence of combined pathologies in 69 patients out of 175. Thirty-four (49%) were noted to have partial septate uterus with endometritis. Seven (10.4%) were reported with three pathologies (septum + polyp + endometritis). Among 69 women with combined pathologies, only 13 (19.7%) had clinical pregnancies after office hysteroscopy. Of 34 (49%) patients with sep-

Table 4. — Pregnancy in number of failed ICSI after office hysteroscopy.

No. of counts (% within number of failed ICSI)	Pregnancy		Total
	No	Yes	
2 count	78 (79.59%)	20 (20.41%)	98 (100.0%)
3 count	28 (77.8%)	8 (22.2%)	36 (100.0%)
4 count	20 (83.3%)	4 (16.7%)	24 (100.0%)
4 + count	16 (94.11%)	1 (5.89%)	17 (100.0%)
Total count (% within number of failed ICSI)	142 (81.1%)	33(18.8%)	175 (100.0%)

$\chi^2 = 2.37, p = 0.500$

tum and endometritis, 10 (29.4%) became pregnant. None of the patients with three pathologies obtained pregnancy. Among 175 patients with different numbers of ICSI failures 33 women became pregnant following office hysteroscopy as given in Table 4.

### Discussion

Recurrent implantation failure (RIF) is a complex problem that may be affected by embryo quality, endometrial receptivity, endometrial cavity problems and systemic disorders like thrombophilia [2, 14]. By adopting the definition of RIF, we excluded the embryo quality as a factor. Thrombophilia can be easily diagnosed and after thromboprophylaxis, pregnancy rates improved. Patients who received low molecular weight heparin for thromboprophylaxis had a significant increase in the implantation and pregnancy rates that are comparable with the findings of Clark *et al.* [15].

After exclusion of thrombophilia, uterine cavity and endometrial receptivity will be the expected factors affecting RIF. Office hysteroscopy is a safe and easy tool for diagnosing cavity problems and endometrial pathologies [16]. Uterine cavity abnormalities may be present in up to 50% of women with recurrent implantation failure. Findings include polyps, endometritis, adhesions and congenital uterine anomalies. Of these, chronic endometritis plays a pivotal role in etiology of RIF and is in accordance with the conclusions of MacAnanny *et al.* [17]. In our study, hysteroscopic abnormal findings were detected in 78.3% of cases out of 175 which was higher than earlier studies by Fatma. (Reference) Aletebi reported abnormalities in 38% out of 132 and Cenksoy *et al.* found hysteroscopic abnormalities in 44.9% patients out of 156 [18, 19].

Several reports confirmed that hysteroscopic corrections of uterine abnormalities improved pregnancy rates. In logistic regression analysis, doing hysteroscopy before the first IVF cycle without correcting anatomic anomalies was not an independent predictor of live birth rate (OR: 0.72, 95% CI: 0.310-1.68,  $p = 0.45$ ) [20]. In this study, out of 175 cases, 40 women were without endometrial abnormalities, 135 were reported with different hysteroscopic findings on office hysteroscopy and 33 patients achieved pregnancy. This result was comparable with the earlier reports

of Elmorsy *et al.* [21]. In addition, Aletebi *et al.* in his findings reported that 132 patients with repeated RIF, 50 patients (38%) had uterine abnormalities on hysteroscopy and 55% of patients with abnormal uterine pathologies got pregnant in subsequent IVF cycles after hysteroscopy [18]. Office microhysteroscopy is well tolerated, safe and simultaneous operative correction make it an ideal and routine procedure in order to diagnose and manage missed intrauterine pathologies, especially in women with infertility resulting in additional improvement of the pregnancy rate [22].

Endometritis was the most common noted pathology either single (65%) or combined (83.7%). This finding necessitates the value of office hysteroscopy in RIF if 3D ultrasound is normal. Endometritis showed a non-satisfactory pregnancy rate after complete cure (16.3%). This pregnancy rate is lower in a non-significant manner than cases with normal finding (21.1%) and adhesions (20%). This may denote the neutralized effect of antibiotic therapy in endometritis, but the overall low pregnancy rate may reflect micro-environmental affection by endometritis or underlying cell mediated immunity abnormalities. This theory may affect the endometrial receptivity and endometrial response to hormonal changes. This finding was magnified in cases with uterine polyps which showed the worst pregnancy rate and decreased the same in cases of mullerian anomalies if combined with polyps. This may reflect endometrial hyperplasia or asynchronous endometrial growth with altered levels of inflammatory mediators making the endometrium non receptive. In addition to specifically altering receptivity, uterine abnormalities may induce or be associated with local endometrial changes. Significant decrease in endometrial leukaemia inhibitory factor mRNA expression in abnormal endometrial canal during the mid-secretory phase, indicates that RIF in women with endometrial canal defects could have a molecular basis [23]. A defect of both vascular endothelial growth factor transmembranous receptors (KDR and Flt-1) has also been described in endometrium covering uterine septum and thought to be responsible for uterine abnormalities [24]. It was also established that mast cells and other humoral factors are dysregulated in endometrium near uterine polyps, which adds an immunologic component to this pathological entity [25].

The occurrence of mullerian duct anomalies also dif-

fers significantly, with findings ranging from 0.16-10% [26, 27]. They were either congenital mullerian anomalies (U1, U2, U3) or acquired lesions like endometritis, polyps, adhesions or combined lesions. In the present study, 15 cases were reported with varied classes of uterine anomalies (U1, U2a, U3a), with 10 having a class U2a or partial septate uterus (15%). After office hysteroscopy 4 women became pregnant and the improved percentage was similar to other studies [28]. Alonso Pacheco conducted a study on a total of 63 women with uterine anomalies with 60 trying to conceive after metroplasty. Clinical pregnancy rate after metroplasty was 83.3% (n = 50/60) ( $p < 0.001$ ), and the LBR was 63.3% (n = 38/60) ( $p < 0.001$ ). Cesarean section rate was 26.3%. No pregnancy complications potentially related to metroplasty were reported. The spontaneous abortion rate was 12% (n = 6/50) ( $p < 0.001$ ) [28].

In the current study, 4 (6%) of the patients were diagnosed with polyps, 14 (20%) with endometrial polyps and 11 (15%) with partial septate polyps as uterine abnormalities. None of the women with single pathology, and two women with combined pathology of polyps became pregnant after hysteroscopy. This low pregnancy rate might be due to increased levels of glycodelin in the ovulatory phase in women that inhibits sperm-oocyte binding thus preventing the process of implantation and angiogenesis [29]. It is also postulated that endometrial polyps decrease mRNA levels of HOXA10 and HOXA11, which are well-known molecular markers of endometrial receptivity [30]. In contrast to our results, previous studies of Aletibi *et al.* observed a significant improvement in pregnancy rates after hysteroscopic polypectomy [18].

In the present study of 175 women, 98 patients with two failed ICSI trails and 77 patients with three and more than that failed ICSI trails were reported. Pregnancy was observed in 33 women (19.8%). In the above cases after doing office hysteroscopy before the next ICSI attempt. Pregnancy rate did not show any improvement in cases with previous three failed ICSI denoting hidden etiology rather than the gross picture. Repeated ICSI and repeated uterine instrumentation may be a cause of endometritis and its harmful effects on implantation. This suggest the need for contemporary investigation of molecular indicators of endometrial receptivity [31]. In the study of Achache *et al.* he compared patients with repeated IVF failure with fertile controls and revealed that reduced prostaglandin synthesis in the human endometrium may also lead to poor endometrial receptivity in patients with RIF [32]. The results of the present study reinforce the view that office hysteroscopy is beneficial to women with RIF prior to further infertility treatment.

In conclusion, office hysteroscopy is an essential procedure for infertility investigation before ICSI. It demonstrates and corrects abnormalities in uterine cavities as it is cost effective and the gold standard technique for assessment of the endometrial cavity. It was considered as a positive prognostic factor in improving the clinical preg-

nancy rate in recurrent miscarriage patients with ICSI. Further studies need to be carried out to confirm the conclusions of this study. The limitations of this study were that it was not a randomized control trial and the environment is different between the Egypt and Libya (place of the study). The strength of the study it was conducted on a cohort of cases with high order of RIF which carry the worst prognosis in IVF and need a tool for both diagnosis and management.

### Trial Registration

Alexandria university, faculty of medicine 0304338. Registered 17 June 2019 - Retrospectively registered, <http://iclas.org/members>

### Authors' Contributions

ME analyzed and interpreted the patient data regarding the findings in office hysteroscopy. HM, IF and ME performed the office hysteroscopy and the ICSI cycles, and were contributors in writing the manuscript. All authors read and approved the final manuscript.

### Ethics Approval and Consent to Participate

This study was approved from the Ethics committee, faculty of medicine, Alexandria university. The number is: 0304338.

Written informed consent for publication of their clinical details and/or clinical images was obtained from the patient. A copy of the consent form is available for review by the Editor of this journal.

The datasets used and/or analyzed during the current study are available from the corresponding author on reasonable request.

### Acknowledgments

The Misurata national IVF center team for assistance in the work.

### Conflict of Interest

The authors declare no conflict of interest.

Submitted: September 27, 2019

Accepted: February 27, 2020

Published: October 15, 2020

### References

- [1] Coughlan C., Ledger W., Wang Q., Liu F., Demirel A., Gurgan T. *et al.*: "Recurrent implantation failure: definition and management". *Reprod. Biomed. Online*, 2014, 28(1), 14-38.
- [2] Margalioth E.J., Ben-Chetrit A., Gal M., Eldar-Geva T.: "Investigation and treatment of repeated implantation failure following IVF-ET". *Hum. Reprod.*, 2006, 21, 3036-43.
- [3] Demirel A., Gurgan T.: "Effect of treatment of intrauterine pathologies with office hysteroscopy in patients with recurrent IVF failure". *Reprod. Biomed. Online*, 2004, 8, 590-4.
- [4] Azem F., Many A., Ben Ami I., Yovel I., Amit A., Lessing J.B., Kupferminc M.J.: "Increased rates of thrombophilia in women with repeated IVF failures". *Hum. Reprod.*, 2004, 19, 368-70.

- [5] Grimbizis, G., Tsolakidis, D., Mikos, T., Anagnostu, E., Asimakopoulos, E., Stamatopoulos, E. *et al.*: "A prospective comparison of transvaginal ultrasound, saline infusion sonohysterography and diagnostic hysteroscopy in the evaluation of endometrial pathology". *Fertil. Steril.*, 2010, 94, 2720-2725.
- [6] Rogerson, L., Bates, J., Weston, M., Duffy, S.: "A comparison of outpatient hysteroscopy with saline infusion hysterosonography". *BJOG.*, 2002, 109, 800-804.
- [7] Apirakviriyaa, C., Rungruksirivorn, T., Phupong, V., Wisawasukmongchol, W.: "Diagnostic accuracy of 3D-transvaginal ultrasound in detecting uterine cavity abnormalities in infertile patients as compared with hysteroscopy". *Euro J Obstet Gynecol Repro Biol*, 2016, 200, 24-28.
- [8] Bashiri, A., Halper, K.I., Orvieto, R.: "Recurrent Implantation Failure-update overview on etiology, diagnosis, treatment and future directions". *Reprod. Biol. Endocrinol.*, 2018, 16, 121.
- [9] Larue L., Keromnes G., Massari A., Roche, C., Moulin, J., Gronier, H., *et al.*: "Transvaginal ultrasound-guided embryo transfer in IVF". *J. Gynecol. Obstet. Hum. Reprod.*, 2017, 46(5), 411-416.
- [10] Barash A., Dekel N., Fieldust S., Segal I., Schechtman E., Granot I.: "Local injury to the endometrium doubles the incidence of successful pregnancies in patients undergoing in vitro fertilization". *Fertil. Steril.*, 2003, 79, 1317-22.
- [11] Parry J.P., Isaacson K.B.: "Hysteroscopy and why macroscopic uterine factors matter for fertility". *Fertil. Steril.*, 2019, 112(2), 203-210.
- [12] Grgan T., Kalem, Z., NKalem M., Ruso H., Benkhalifa M., Makri-giannakis A.: "Systematic and standardized hysteroscopic endometrial injury for treatment of recurrent implantation failure". *Reprod. Biomed. Online*, 2019, 39(3), 477-483.
- [13] Ferraretti A.P., La Marca A., Fauser B.C., Tarlatzis B., Nargund G., Gianaroli L.: "ESHRE working group on Poor Ovarian Response Definition. ESHRE consensus on the definition of "poor response" to ovarian stimulation for in vitro fertilization: The Bologna criteria". *Hum. Reprod.*, 2011, 26, 1616-24.
- [14] Visser JI., Ulander V.M., Helmerhorst F.M., Lampinen K., Morin-Papunen L., Bloemenkamp K.W., Kaaja R.J.: "Thromboprophylaxis for recurrent miscarriage in women with or without thrombophilia HABENOX\*: A randomized multicentre trial". *Thromb. Haemost.*, 2011, 105, 295-301.
- [15] Clark P., Walker I.D., Langhorne P., Crichton L., Thomson A., Greaves M., *et al.*: "SPIN (Scottish Pregnancy Intervention) study: A multicenter, randomized controlled trial of low-molecular-weight heparin and low dose aspirin in women with recurrent miscarriage". *Blood*, 2010, 115, 4162-7.
- [16] Siristatidis C., Chrelias C., Salamalekis G., Kassanos D.: "Office hysteroscopy: current trends and potential applications: a critical review". *Arch. Gynecol. Obstet.*, 2010, 282, 383-8.
- [17] Johnston-MacAnanny E.B., Hartnett J., Engmann L.L., Nulsen J.C., Sanders M.M., Benadiva C.A.: "Chronic endometritis is a frequent finding in women with recurrent implantation failure after in vitro fertilization". *FertilSteril*, 2010, 93, 437-41.
- [18] Aletebi F.: "Hysteroscopy in women with implantation failures after in vitro fertilization: Findings and effect on subsequent pregnancy rates". *Middle East Fertil. Soc. J.*, 2010, 15, 288-91.
- [19] Cenksoy P., Ficicioglu C., Yildirim G., Yesiladali M.: "Hysteroscopic findings in women with recurrent IVF failures and the effect of correction of hysteroscopic findings on subsequent pregnancy rates". *Arch. Gynecol. Obstet.*, 2013, 287(2), 357-60.
- [20] Atakan T., Sezcan M., Hakan Y., Grkan B.: "The effect of performing hysteroscopy prior to the first in vitro fertilization (IVF) cycle on live birth rate". *Gynecol. Endocrinol.*, 2019, 35(5), 443-447.
- [21] Hossam E.S., Mahmoud E., Mostafa K.: "Eissa routine office hysteroscopy prior to ICSI and its impact on assisted reproduction program outcome: a randomized controlled trial". *Middle East Fertil. Soc. J.*, 2012, 17, 14-21.
- [22] Seyam E.M., Hassan M.M., Mohamed Sayed Gad M.T., Mahmoud H.S., Ibrahim M.G.: "Pregnancy outcome after office microhysteroscopy in women with unexplained infertility". *Int. J. Fertil. Steril.*, 2015, 9(2), 168-175.
- [23] Hasegawa E., Ito H., Hasegawa F., Hatano K., Kazuka M., Usuda S., Isaka K.: "Expression of leukemia inhibitory factor in the endometrium in abnormal uterine cavities during the implantation window". *Fertil. Steril.*, 2012, 97(4), 953-58.
- [24] Raga F., Casan E.M., Bonilla-Musoles F.: "Expression of vascular endothelial growth factor receptors in the endometrium of septate uterus". *Fertil. Steril.*, 2009, 92(3), 1085-90.
- [25] El-Hamarneh T., Hey-Cunningham A.J., Berbic M., Al-Jefout M., Fraser I.S., Black K.: "Cellular immune environment in endometrial polyps". *Fertil. Steril.*, 2013, 100(5), 1364-72.
- [26] Rock J.A.: "Surgery for anomalies of the mullerian ducts". Tompson J.D., Rock J.A., eds. *TeLind's Operative Gynecology*. 9th ed. Philadelphia, Pa: JB Lippincott Williams & Wilkins, 2003, 705.
- [27] Reyes-Munoz, E., Vitale, S.G., Alvarado-Rosales, D., Iyune-Cojab, E., Vitagliano, A., Lohmeyer, *et al.*: "Mllerian anomalies prevalence diagnosed by hysteroscopy and laparoscopy in mexican infertile women: results from a cohort study". *Diagnostics*, 2019, 9, 149.
- [28] Pacheco L.A., Lagan A.S., Garzon S., Garrido A.P., Gorns A.F., Ghezzi F.: "Hysteroscopic outpatient metroplasty for T-shaped uterus in women with reproductive failure: results from a large prospective cohort study". *Eur. J. Obstet. Gynecol. Reprod. Biol.*, 2019, 243, 173-178.
- [29] Richlin S., Ramachandran S., Shanti A., Murphy A.A., Parthasarathy S.: "Glycodelin levels in uterine flushings and in plasma of patients with leiomyomas and polyps: implications and implantation". *Hum. Reprod.*, 2002, 17, 2742-7.
- [30] Rackow W., Jorgensen E., Taylor H.S.: "Endometrial polyps affect uterine receptivity". *Fertil. Steril.*, 2011, 95(8), 2690-2.
- [31] Revel A.: "Defective endometrial receptivity". *Fertil. Steril.*, 2012, 97(5), 1028-32.
- [32] Achache H., Tsafirir A., Prus D., Reich R., Revel A.: "Defective endometrial prostaglandin synthesis identified in patients with repeated implantation failure undergoing in vitro fertilization". *Fertil. Steril.*, 2010, 94(4), 1271-8.

Corresponding Author:

Mohamed Elmahdy, M.D.

Alexandria University, Obstetrics and Gynecology

Department, Alexandria,

Egypt 13 Glyis Street Raml Station,

Alexandria (Egypt)

e-mail: mahdy\_moh@yahoo.com