

Case Report

Making Diagnosis of Gestational Trophoblastic Neoplasia: What, When, How to Treat and What to do Next?

Membuat Diagnosis Gestational Trophoblastik Neoplasia: Apa, Kapan, Bagaimana Cara Mengobati dan Apa yang Harus Dilakukan Selanjutnya?

Tricia D Anggraeni¹, Olivia Widyanti²

¹Department of Obstetrics and Gynecology

²Faculty of Medicine, Universitas Indonesia

Dr. Cipto Mangunkusumo General Hospital
Jakarta

Abstract

Objective : Delay on diagnosing GTN may increase the GTN score from low risk become high risk, as follow.

Methods : case report

Results : Mrs I, 29 yo, P1A7 came with vaginal bleeding. Four months before admission, she had surgery of ectopic pregnancy, and the left salphynx and ovary had already taken out. No histopathology examination was performed. After the surgery, she had vaginal bleeding and underwent curettage, but the tissue was not sent for histopathology exam. US exam one week after procedure shows mass protruding in the uterine, with BhCG 225.000 IU/ml. The patient was planned to undergo chemotherapy. While waiting for chemotherapy, patient complaints of acute abdomen due to hemoperitoneum due to perforation of trophoblastic mass. Emergency laparotomy was performed.

Conclusions : Inadequate treatment due to inadequate staging is the most common reason for unsuccessful GTN treatment, and increase patient morbidity. Histopathology result also plays an important role to decide the mode of treatment should be given since PSTT and ETT treatment of choice is not using chemotherapy.

Keywords : ectopic pregnancy, gestational trophoblastic neoplasia, molar gestation, vaginal bleeding pathology.

Abstrak

Tujuan : Penundaan dalam mendiagnosis GTN dapat meningkatkan skor GTN dari risiko rendah menjadi risiko tinggi, sebagai berikut.

Metode : laporan kasus

Hasil : Ny. I, 29 tahun, P1A7 datang dengan pendarahan vagina. 4 bulan sebelum masuk, dia menjalani operasi kehamilan ektopik, dan salphynx dan ovarium kiri sudah diambil. Tidak ada pemeriksaan histopatologi yang dilakukan. Setelah operasi, dia mengalami pendarahan vagina dan menjalani kuret, tetapi jaringan itu tidak dikirim untuk pemeriksaan histopatologi. Ujian AS 1 minggu setelah prosedur menunjukkan massa menonjol di uterus, dengan BhCG 225.000 IU / ml. Rencanakan kemoterapi. Sambil menunggu kemoterapi, keluhan pasien perut akut karena hemoperitoneum karena perforasi massa trofoblas. Laparotomi darurat dilakukan.

Kesimpulan : pengobatan yang tidak memadai karena pementasan yang tidak memadai adalah alasan yang paling umum dari pengobatan GTN tidak berhasil, dan meningkatkan morbiditas pasien. Hasil histopatologi juga memainkan peran penting untuk menentukan cara pengobatan yang harus diberikan, karena pilihan pengobatan PSTT dan ETT tidak menggunakan kemoterapi.

Kata kunci : kehamilan ektopik, kehamilan mola, neoplasia trofoblastik gestasional, patologi perdarahan pervaginam.

Correspondence author: Tricia D Anggraeni; anggi73@gmail.com

INTRODUCTION

A delay on diagnosing Gestational Trophoblastic Neoplasia (GTN) may cause an increase of morbidity to the patient. The important things that OBGYN usually forgot are that GTN may develop not only from previous molar gestation (50-60%), but also from abortions or ectopic pregnancy (25-30%) and term or preterm deliveries (10-

25%).^{1,2}This can cause a delay on diagnosing that may increase the GTN score from low risk become high risk, such as this case, as follow.

CASE

Mrs I, 29 yo, P1A7 came with vaginal bleeding. Four months before admission, she had surgery of ectopic pregnancy, and the left salphynx and

ovary had already taken out. No histopathology examination was performed. After the surgery, she had vaginal bleeding and underwent curettage, but the tissue was not sent for histopathology exam. She had US exam one week later, there is tissue remnant and invaded to the uterine wall, given primolut for 15 days, then checked for b-hCG, and the result was 225.000 IU/ml. The patient was then referred to our hospital. Ultrasonographic findings found a solid mass on the posterior part, irregular, no clear border, size 60x10 mm malignant trophoblastic mass. Mass on left anterior corpus invaded the left adnexa, left ovary sized 100x110 mm. Liver, spleen, and both kidneys were normal. Conclusion: malignant trophoblastic disease with invasion to left adnexa.

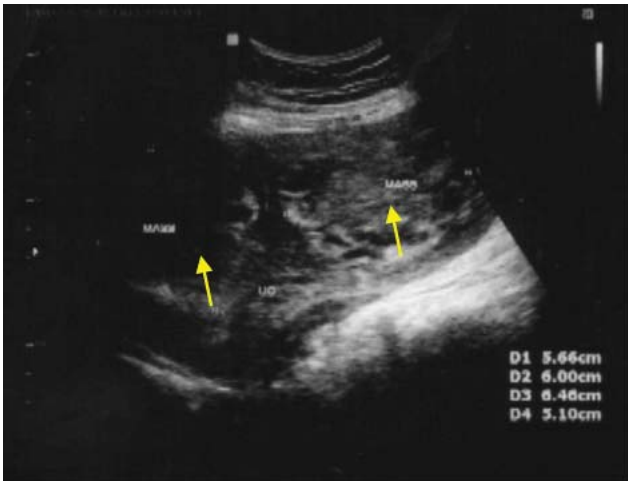


Figure 1. Malignant mass invaded to myometrium

While waiting for chemotherapy, patient complaints of acute abdomen due to hemoperitoneum due to perforation of trophoblastic mass. Emergency laparotomy was performed, found hemoperitoneum and perforation on the upper left side of the uterus, total hysterectomy was performed.

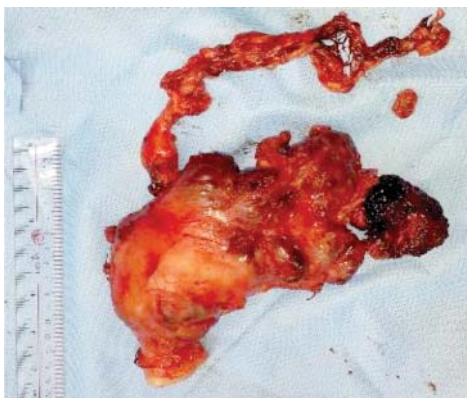

Figure 2. The specimen demonstrated perforation on the upper left side of the uterus

Based on the fact that there were several cases of GTN found too late, we try to explain about GTN "What, When, How to Treat and What to do Next?" What kind of GTN could be managed by general obgyn and when to refer the patient to Oncology-gynecologist. In this article, only treatment with single-agent chemotherapy will be discussed deeply.

What is Gestational Trophoblastic Neoplasia (GTN)?

Gestational trophoblastic neoplasia (GTN) is the term used to describe malignant lesions that originate in the chorionic villi and the extravillous trophoblast. GTN includes four different proliferation, invasion and dissemination, such as invasive mole (IM), choriocarcinoma (CCA), placental site trophoblastic tumour (PSTT) and epithelioid trophoblastic tumour (ETT). The overall cure rate with chemotherapy is around 90%, but for PSTT and ETT are relatively resistant for chemotherapy.² Therefore, the first-line treatment in these cases is surgery, particularly in no metastatic cases³. PSTT and ETT, however, develop after term deliveries or non-molar abortions in 95% of the cases⁴.

When we have to think about GTN?

Most of GTN develops from postmolar gestation (50-60%) while GTN could also develop from previous abortion, ectopic pregnancy and term or preterm deliveries.¹⁻³ Following a molar pregnancy, the risk of a further hydatidiform mole increases around 1%.^{5,6} After two molar gestations, the risk of a third mole is 15%–20% and is not decreased by changing partners.⁷ Most of PSTT and ETT (95%) usually develop after term delivery or non-molar abortion². That is why the pathology result of the tissue that had been evacuated previously plays a vital role in diagnosing GTN.

The components needed to diagnose postmolar GTN, based on FIGO 2002 include at least 1 of the following; hCG plateau for 4 consecutive values over 3 weeks; hCG rise of $\geq 10\%$ for 3 values over 2 weeks; hCG persistence 6 months after molar evacuation; histopathologic diagnosis of choriocarcinoma; or presence of metastatic disease. While PSTT and ETT are classified separately.¹⁻³ hCG value measured after mole evacuation use as a reference value. A rise,

plateau or persistence value of hCG, the presence of metastatic disease, or picture of invasive mass out of uterine cavity (such as myometrium) after molar evacuation could be used to diagnose GTN. On the other side histopathology results was used to classify GTN by its characteristics, for example: invasive mole have a risk of perforation, choriocarcinoma have a high risk of metastases, ETT or PSTT usually resistance to chemotherapy.

When GTN is suspected or established, a metastatic workup and an evaluation for risk factor should be performed. Along with complete history and physical examination, complete blood count, including coagulation studies, renal and liver function test and quantitative hCG level should be performed. Radiologic studies, such as pelvic ultrasound, chest x-ray, CT scan or brain MRI also recommended, if there was a sign of neurologic deficits, to detect any site of metastases.^{2,5}

GTN metastases occur by hematogenous spread to the lungs (80%), vagina (30%), brain (10%) and liver (10%). Biopsies are not recommended because of the high risk of bleeding.^{2,5}

What to do after diagnosing GTN?^{2,5}

Treatment of GTN is based on risk groups classification by stage and scoring system using FIGO or modified WHO prognostic scoring and the pathology findings. Only GTN that originated from previous molar pregnancy or low-risk GTN with single chemotherapy agent could be managed by general OBGYN; others should be managed by oncology-gynaecologist.

Prior to treatment, OBGYN should classify the disease to choose the right treatment plan. There were several classifications of GTN, such as Hammond, FIGO and WHO modified FIGO classification. Chemotherapy given did not correlate with the staging (FIGO), but depend on the Hammond classification or WHO modified FIGO classification.

Hammond classifies malignant GTN divided into good prognostic GTN and poor prognostic GTN; metastatic GTN is diagnosed when we found nodules on other organs, except vagina and lungs.

Table 1. Metastatic GTN Classification Based on Hammond (1981)

	Good Prognosis	Poor Prognosis
Urinary hCG	<10 ⁵ IU/lit	>10 ⁵ IU/lit
Serum hCG	<4x10 ⁴ mIU/ml	>4x10 ⁴ mIU/ml
Symptom present	< 4 months	> 4 months
Liver or brain metastases	No	Yes
Prior chemotherapy	No	Yes
Following term pregnancy	No	Yes

Table 2. GTN Staging by FIGO

Stage	Description
I	Disease confined to the uterus
II	Disease extend outside uterus but is limited to genital structures (adnexa, vagina, broad ligament)
III	Disease extends to lungs with or without genital tract involvement
IV	Disease involves other metastatic sites

The FIGO stage is followed by the Modified WHO score and separated by a colon. Based on Hammond nonmetastatic classification (FIGO: stage I) and low-risk metastatic (FIGO: stages II and III or score <7 due to WHO modified FIGO classification) GTN can be treated with single-agent chemotherapy resulting in a survival rate approaching 100%.^{2,5}

High-risk GTN (FIGO: stages II-IV, score ≥7 due to WHO modified FIGO classification) requires initial multiagent chemotherapy with or without adjuvant radiation and surgery to achieve a survival rate of 80-90%.^{2,5}

The overall cure rate was 90% with chemotherapy. However, for PSTT and ETT, Hysterectomy with lymph node dissection is the treatment of choice with survival rate is approximately 100% for nonmetastatic disease and 50-60% for metastatic disease.^{2,5}

Table 3. Modified WHO Prognostic Scoring System as Adapted by FIGO

Risk factor	Score			
	0	1	2	4
Age, yo	≤39	>39	-	-
Antecedent pregnancy	mole	abortion	term	
Pregnancy even to treatment interval, mo	<4	4-6	7-12	>12
Pretreatment hCG, mIU/ml	< 10 ³	10 ³ -10 ⁴	10 ⁴ -10 ⁵	> 10 ⁵
Largest tumour mass including uterus, cm	<3	3-4	≥5	-
Site of metastases	-	Spleen, kidney	GI tract	Brain, liver
No. of metastases	-	1-4	5-8	>8
Previous failed chemotherapy	-	-	Single-drug	≥ 2 drug

How to treat low-risk GTN?

There were several different outpatient chemotherapy protocols have been used. Benefits seem to be greater when hCG concentration is below 1500 IU/L at the time of evacuation², and the adverse side effect rate was much greater with combination therapy (62%) than with single-agent methotrexate (29%) or actinomycin D (19%).⁵

The three most common regimens used are: weekly low-dose intramuscular (IM) MTX 0.4 mg/kg (maximum 25mg/day) for 5 day, repeat every 14 days; pulsed doses of ActD 1.25mg/m² repeat every two weeks; and several other dosing regimens of MTX 1mg/kg IM (d 1,3,5,7) with or without folinic acid (FA) rescue 0.1 mg/kg IM (d 2,4,6,8) repeat every 15-18 days. The survival rate using this kind of regiments was more than 90%.^{2,5}

Mortality rates associated with IM reached 15%. In the presence of metastases, CCA had a mortality rate of 100%, and about 60% when the hysterectomy was performed to treat apparent nonmetastatic disease.²

What to do next?

Definitive follow up requires serial quantitative hCG measurements every 1-2 weeks until achieving the normal level, and it is consolidation dose by continuing the follow up with three consecutive tests that show normal level (depend on the normal laboratory value) after treatment. After that, hCG levels should be determined every 1-month intervals for 12 months. The relapse risk

was about 3% in the first year after completing the therapy.^{3,7-8}

Follow up

Contraception (preferably using oral contraceptives) should be maintained during treatment and for one year after completion of chemotherapy.^{1-3,9} Because there is 1-2% risk of second gestational trophoblastic disease in subsequent pregnancies, pelvic ultrasound is recommended in the first trimester to confirm a normal gestation. The products of conception or placentas should be examined by histopathology and serum quantitative hCG level should be determined six weeks after any pregnancy.³

Most woman resumes normal ovarian function after chemotherapy and exhibits no increase in infertility. No evidence for reactivation of the disease because of subsequent pregnancy.^{3,10} Primary remission was achieved in 48-67% of patients with the first single-agent chemotherapy regimen. From 1-14% of patients needed multiagent chemotherapy after failed sequential single-agent chemotherapy with or without surgery to achieve remission, but eventually, all patients were cured.³

The most common reasons for unsuccessful GTN treatment are use of single-agent chemotherapy for patients with high-risk disease; inappropriate use of weekly IM methotrexate chemotherapy for treatment of patients with metastatic disease, FIGO scores ≥ 7, and/or nonpostmolar choriocarcinoma.³

CONCLUSION

Inadequate treatment due to inadequate staging is the most common reason for unsuccessful GTN treatment, and increase patient morbidity. It is important to know how to perform GTN staging using the WHO modified staging score, adapted by FIGO and how to perform adequate treatment for this disease. Histopathology also plays an essential role to decide the mode of treatment that should be given since PSTT, and ETT treatment of choice is not using chemotherapy.

Since there is a risk of repeated gestational trophoblastic disease, it is important to use contraception during treatment and one year after completion of chemotherapy. It is also recommended to examine the conception product or placenta by histopathology and serum quantitative hCG level should be determined six weeks after any pregnancy.

REFERENCES

1. Ngan, Hextan Y.S.; Michael J. Seckl, Ross S. Berkowitz, Yang Xiang, François Golfier, P.K. Sekharan, John R. Lurain. FIGO CANCER REPORT 2015: Update on the diagnosis and management of gestational trophoblastic disease. *Int J Gynecol Obstet*, 2015; 131:S123–S6.
2. Biscaro, A., Braga, A., & Berkowitz, R. S. (2015). Diagnosis, classification and treatment of gestational trophoblastic neoplasia. *Revista Brasileira de Ginecologia e Obstetrícia*, 37(1), 42-51.
3. Goldstein DP, Berkowitz RS. Current management of gestational trophoblastic neoplasia. *Hematol Oncol Clin North Am*. 2012;26(1):111-31.
4. Osborne R, Dodge J. Gestational trophoblastic neoplasia. *Obstet Gynecol Clin North Am*. 2012;39(2):195-212.
5. Lurain, John R. MD. Gestational trophoblastic disease II: classification and management of gestational trophoblastic neoplasia *Am J Obstet Gynecol*. 2011.doi: 10.1016/j.ajog.2010.06.072
6. Mangili, Giorgia MD, Domenica Lorusso, et al. Trophoblastic Disease Review for Diagnosis and Management: A Joint Report From the International Society for the Study of Trophoblastic Disease, European Organisation for the Treatment of Trophoblastic Disease, and the Gynecologic Cancer InterGroup. *Int J Gynecol Cancer* 2014;24: S109-S116.
7. Yang J, Xiang Y, Wan X, Yang X. Recurrent gestational trophoblastic tumor: management and risk factors for recurrence. *Gynecol Oncol* 2006;103:587–90.
8. Sun Y, Xiang Y, Wan XR, Yang XY. Factors related to recurrence of choriocarcinoma and evaluation of treatment outcomes. *Zhonghua Fu Chan Ke Za Zhi* 2006;41: 329–32.
9. ESMO Guidelines Working Group. Clinical Practice Guidelines; Gestational Trophoblastic Disease: ESMO Clinical Practice Guidelines for diagnosis, treatment and follow-up. *Annals Oncol*,2013; 24 (Supp 6): vi39–vi50.
10. Lurain, J. R. (2010). Gestational trophoblastic disease I: epidemiology, pathology, clinical presentation and diagnosis of gestational trophoblastic disease, and management of hydatidiform mole. *Am J Obstet Gynecol*, 203;6: 531-9.