

# Intrauterine balloon failure: unrecognized placenta accreta spectrum disorders

K. Tamura<sup>1</sup>, H. Takahashi<sup>1,\*</sup>, S. Uchida<sup>1</sup>, M. Ogoyama<sup>1</sup>, R. Usui<sup>1</sup>, S. Matsubara<sup>1</sup>

<sup>1</sup>Department of Obstetrics and Gynecology, Jichi Medical University, Tochigi (Japan)

## Summary

Several studies indicate that intrauterine balloon (IUB) use is less effective for postpartum hemorrhage (PPH) due to placenta accreta spectrum (PAS) disorders than that due to atonic bleeding. IUB failed to achieve hemostasis because the present two cases had normally positioned PAS. *Case Report:* A 37-year-old woman was transferred due to PPH. She vaginally delivered. The placenta was without macroscopic defect. Atonic bleeding was suspected. An IUB was placed, without achieving hemostasis. Her status deteriorated, necessitating a hysterectomy. The placenta remained, adhering to the uterine body. Histological examination revealed placenta accreta. The second case was a 40-year-old woman that was transferred due to PPH of atonic bleeding after vaginal delivery. The placenta was without macroscopic defect. An IUB was placed, without hemostasis, and was subsequently removed. Conservative treatment achieved hemostasis. An Ultrasound revealed the placenta in the uterine body. We diagnosed her with clinical PAS. Nonprevia PAS may be present when an IUB fails to achieve hemostasis.

*Key words:* Intrauterine balloon; Hysterectomy; Postpartum hemorrhage; Placenta accreta spectrum; Transfusion.

## Introduction

Intrauterine balloon (IUB) use is effective for hemostasis of postpartum hemorrhage (PPH), and the present team published various techniques to enhance the hemostatic effect of IUB [1, 2]. Several studies indicate that IUB is less effective for PPH associated with placenta accreta spectrum (PAS) disorders than that associated with atonic bleeding [3, 4]. When PAS is accompanied by placenta previa (placenta previa accreta), especially in women with a scarred uterus, obstetricians suspect the presence of PAS and as such, manage PPH. In the present study, the authors describe two PPH patients where PPH was considered to be due to normally positioned (non-previa) PAS. In both cases, an IUB failed to achieve hemostasis. The authors wish to draw attention to the fact that PAS, especially nonprevia PAS, may be present when PPH is refractory to IUB.

## Case Report

### Case 1

A 37-year-old woman (2-gravida, 1-parous, without a history of uterine surgery) was transferred to us due to PPH. She spontaneously conceived and vaginally delivered a term infant. The placenta was delivered without macroscopic defect. On arrival, no color Doppler intrauterine signals were detected. The blood loss was 1,850 mL and atonic bleeding was suspected. An IUB was placed, without achieving hemostasis, with blood loss (vaginal + from IUB drain) of 300 mL for one hour after IUB insertion (Figure 1). Although the authors planned to perform transarterial embolization, her circulatory status acutely deteriorated with

a shock index of 1.5, necessitating a hysterectomy. Total blood loss after delivery was 6,000 mL. Transfusions were required (red blood cells: 16 units, fresh frozen plasma: 16 units, platelet concentrate: 10 units). The placenta (6 × 4 cm) remained, adhering to the posterior lower uterine body (Figure 2a). Histological examination revealed placenta accreta (Figure 2b).

### Case 2

A 40-year-old primiparous woman, conceiving after assisted reproductive technology, was transferred to us due to PPH at two hours after term vaginal delivery. The placenta was delivered spontaneously without macroscopic defect, and then PPH occurred. Under the diagnosis of atonic bleeding, an IUB was placed, without hemostasis; marked bleeding occurred beyond the balloon, and subsequently the IUB was removed. On arrival to this institute, bleeding decreased and vaginal gauze packing and transfusion ameliorated the condition, and hemostasis was achieved. At one week postpartum, an ultrasound revealed a hyper-vascular lesion (5.1 × 6.2 cm) in the mid-uterine body (Figure 3a), suggestive of hyper-vascular placental tissue (Figure 3b). While adopting a wait and see strategy, the placenta was spontaneously expelled at 24 days postpartum. Small parts of the residual placenta were observed for two months and then disappeared. The authors diagnosed this condition as clinical PAS.

## Discussion

These two cases suggest two important clinical issues. Firstly, although the placenta was delivered without diffi-

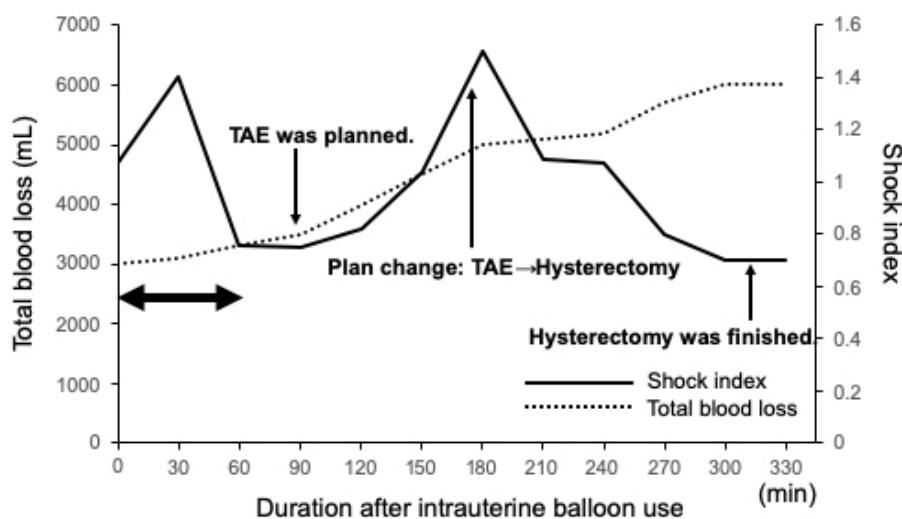


Figure 1. — Clinical course of Case 1. The blood loss (vaginal + from intrauterine balloon drain) steadily increased to as much as 300 mL at one hour after intrauterine balloon use (bold arrow). CS: cesarean section, TAE: transarterial embolization.

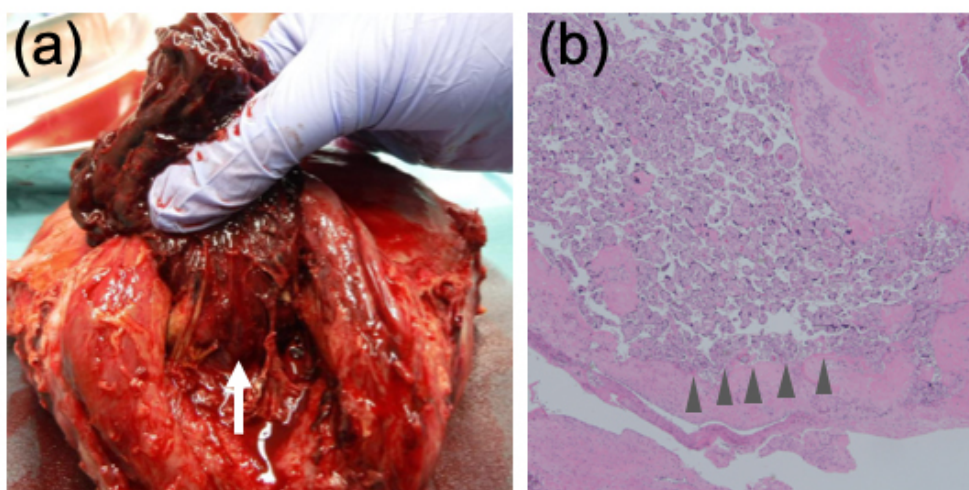


Figure 2. — Macroscopic (a) and microscopic (b) findings in Case 1. Placenta accreta spectrum is observed. A placental fragment adhered to the posterior uterine body (arrow). Chorionic villi directly attached to the myometrium (arrowhead) without decidua, suggesting placenta accreta.

culties and examinations of the delivered placenta showed no placental defects, PAS, especially non-previa PAS, cannot be ruled out. In focal PAS, rather than diffuse PAS, the PAS lesion is confined to some placental area. The main placental parts, being devoid of PAS, may be easily removed. With the rare exception with accessory placenta being PAS, placental examination after delivery theoretically shows the placental defect reflecting the placental parts of PAS still undelivered. However, gross examination of the placenta sometimes does not accurately indicate this, espe-

cially when the remaining parts are relatively small. To detect the remaining placenta, especially PAS placenta, ultrasound, especially Color Doppler, and magnetic resonance imaging may be useful. Secondly, nonprevia PAS can be misdiagnosed as atonic bleeding or these two may sometimes coexist. If an IUB is placed without success, it may sometimes delay obstetricians resorting to more invasive hemostatic procedures (including hysterectomy as in Case 1 presented here). Insertion of an IUB achieves hemostasis in 85-100% [1, 2, 5, 6] and 17-63% [3, 4] in cases of atonic

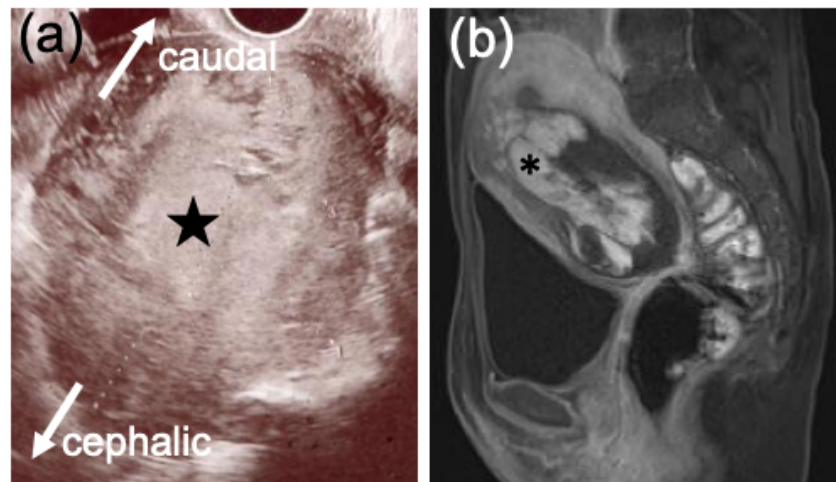


Figure 3. — Imaging findings in Case 2. Transvaginal ultrasound shows the residual placenta (high-echoic part: star) in the uterus on postpartum day 8. The placenta is retained in the anterior uterus (asterisk) based on magnetic resonance imaging (T1 gadolinium enhanced) on postpartum day 10.

bleeding and. PAS respectively, meaning that an IUB is less likely to achieve hemostasis in PAS.

Aside from whether PPH is caused by atonic bleeding or PAS, we should consider for whom does an IUB achieve hemostasis. A hemorrhage following an IUB placement may provide one clue. To the present authors' knowledge, two studies have focused on this issue. The current authors previously showed that of 71 PPH patients in whom IUB was placed, hemorrhage at one hour after IUB insertion was  $< 100$  vs.  $> 250$  mL in all 66 hemostasis (+) vs. all five hemostasis (-) patients, respectively, being markedly different [3]. The other study showed a similar context. Wah *et al.* measured the bleeding amount at 30 minutes (instead of one hour) after IUB placement. It was  $42 \pm 36$  (mean  $\pm$  SD),  $176 \pm 136$ , and  $709 \pm 439$  mL for patients achieving hemostasis, those requiring uterine compression sutures or transarterial embolization, and those requiring hysterectomy, respectively [4]. Indeed, in Case 1, blood loss was 300 mL at one hour after IUB placement. In Case 2, marked bleeding occurred, exceeding 300 mL at one hour after IUB placement.

Here, the authors showed that an IUB did not achieve hemostasis in two PPH patients. Hemorrhage after IUB placement may predict IUB success vs. failure. In Case 1, hysterectomy was required and thus the IUB may have delayed the decision of hysterectomy, whereas in Case 2 hemostasis was achieved with a wait and see strategy. Thus, in retrospect, IUB insertion may and may not have been harmful for Cases 1 and 2, respectively. In Case 1, bleeding continued irrespective of an IUB. This may have been because bleeding pressure from the site was higher than IUB pressure, or the IUB may have been located in the uterine caudal portion and did not compress the bleeding site. In Case 2, bleeding occurred even with IUB for the same

reasons as stated above, but after IUB removal bleeding stopped. Whether this was due to transfusion with platelets, and thus amelioration of coagulopathy, gauze packing, or some other factors such as, uterine contraction, favorably affecting hemostasis, is unknown. PPH shows various clinical courses depending on the context.

An advanced maternal age and/or assisted reproductive technologies increase the PAS risk: this is also true for non-previa PAS. In patients with placenta previa, especially in those with a CS history, we are usually concerned about the presence of PAS and as such prepare for it. Non-previa PAS may be hidden behind PPH and it sometimes coexists with atonic bleeding. Macroscopic examination of the delivered placenta may not always effectively rule out PAS. Non-previa PAS may be hidden when IUB does not achieve hemostasis.

#### Ethics Approval and Consent to Participate

All subjects gave their informed consent for inclusion before they participated in the study. The study was conducted in accordance with the Declaration of Helsinki.

#### Conflict of Interest

The authors declare no competing interests.

Submitted: April 22, 2019

Accepted: June 24, 2019

Published: June 15, 2020

#### References

- [1] Revert M., Cottenet J., Raynal P., Cibot E., Quantin C., Rozenberg P.: "Intrauterine balloon tamponade for management of severe postpartum haemorrhage in a perinatal network: a prospective cohort study". *BJOG*, 2017, *124*, 1255.
- [2] Vintejeux E., Ulrich D., Mousty E., Masia F., Mares P., de Tayrac

- R., *et al.*: "Success factors for Bakri™ balloon usage secondary to uterine atony: a retrospective, multicentre study". *Aust. N. Z. J. Obstet. Gynaecol.*, 2015, 55, 572.
- [3] Ogoyama M., Takahashi H., Usui R., Baba Y., Suzuki H., Ohkuchi A., *et al.*: "Hemostatic effect of intrauterine balloon for postpartum hemorrhage with special reference to concomitant use of "holding the cervix" procedure (Matsubara)". *Eur. J. Obstet. Gynecol. Reprod. Biol.*, 2017, 210, 281.
- [4] Kong C.W., To W.W.: "Prognostic factors for the use of intrauterine balloon tamponade in the management of severe postpartum hemorrhage". *Int. J. Gynaecol. Obstet.*, 2018, 142, 48.
- [5] Georgiou C.: "Balloon tamponade in the management of postpartum haemorrhage: a review". *BJOG*, 2009, 116, 748.
- [6] Brown H., Okeyo S., Mabeya H., Wilkinson J., Schmitt J.: "The Bakri tamponade balloon as an adjunct treatment for refractory postpartum hemorrhage". *Int. J. Gynaecol. Obstet.*, 2016, 135, 276.

Corresponding Author:

HIRONORI TAKAHASHI, M.D.

Department of Obstetrics and Gynecology

Jichi Medical University

3311-1 Yakushiji, Shimotsuke

Tochigi 329-0498 (Japan)

e-mail: hironori@jichi.ac.jp