

# Short term outcomes of a new non-dissection minimally invasive surgery method for cystocele repair

G. Calongos<sup>1,\*</sup>, Y. Tsuji<sup>1</sup>, Y. Ito<sup>1</sup>, M. Handa<sup>1</sup>, Y. Kubota<sup>1</sup>, A. Ida<sup>1</sup>

<sup>1</sup>Department of Obstetrics and Gynecology, Kobe Adventist Hospital, Arinodai, Kita-ku, Kobe (Japan)

## Summary

**Purpose of investigation:** The objective of this study was to assess the safety and efficacy of our new surgical technique for cystocele treatment. **Materials and Methods:** Twenty patients diagnosed from May 2017 to October 2018 with a minimum stage III cystocele were included. Our new technique was performed bilaterally using two polypropylene monofilament suture threads. The suture started at the level of the left bulbo cavernosus muscle and continued to the right and then to the left uterosacral ligament. With the second thread, the suture was made on the opposite side to that described above. Patients were followed-up for a minimum of six months post-operatively (mean 9.9 months). **Results:** No intra-surgical or post-surgical complications were observed. Only one patient presented with a cystocele recurrence during follow-up, but did not require treatment. **Conclusion:** The new surgical technique was found to be safe and effective for cystocele repair in this study.

**Key words:** Cystocele; Pelvic organ prolapse (POP); Vaginal surgery.

## Introduction

Pelvic organ prolapse (POP) refers to the descent of one or more pelvic organs into the vagina. These may present at the anterior vaginal wall, posterior vaginal wall, apex of the vagina (cervix to uterus), or vault (cuff) after hysterectomy [1]. The most frequent form of POP is anterior vaginal wall prolapse or cystocele [2]. POP occurs in up to 50% of women who have given birth [3, 4] and has a prevalence of up to 6% [5]. The etiology of POP is complex and is associated with many factors. These includes age, pregnancy, history of vaginal delivery and previous pelvic surgery. Also contributing are high-risk factors that increase intra-abdominal pressure, such as chronic pulmonary disease, constipation, obesity and heavy manual labor [1].

The goal of cystocele repair is to reinforce the cervicovaginal fascia [6]. Cystocele is most commonly treated by transvaginal repair using native tissue, i.e. colpectomy with colporrhaphy [7]. Anterior colporrhaphy has a reported success rate of only 30%, however this may be improved by using the correct suture type and placement [4]. Because of the high failure rate of these conventional methods, the use of a graft or mesh as reinforcing material has been popularized, but with specific complications [6]. Abdominal and laparoscopic sacral colpophyteropexy have also become an option for primary cystocele repair [7].

Despite the prevalence of this disorder, there is a lack of consensus regarding the optimal surgical approach. The authors developed a non-dissection minimally invasive and low-cost surgical technique for the repair of anterior wall prolapse. The aim of this study was to evaluate the safety and effectiveness of a new surgical method for the correc-

tion of cystocele.

## Materials and Methods

This study was approved by the Ethical Review Board of the Kobe Adventist Hospital. The study included 20 patients with POP-Q (Pelvic Organ Prolapse Quantification System) stage III or higher prolapse of the anterior wall and diagnosed between May 2017 and October 2018. Informed consent was obtained after detailed explanation about the procedure to the patient and family. Women with previous hysterectomy, pelvic organ cancer, active sexual life, medical complications which contraindicated general anesthesia, and patients who declined participation were excluded from this study. A preoperative physical examination was performed on each participant by the team of gynecologists undertaking all the surgeries.

Surgeons utilized a new technique consisted of a continuous suture with 5 mm or less distance between stitches (Figure 1). Under tension, the sutures were almost completely hidden by the vaginal mucosa, thereby reducing patient discomfort. The length and depth of suture were approximately 2 cm and 1 cm, respectively. The author hypothesized that this approach would provide sufficient stability and strength to correct the anterior wall prolapse without damaging the bladder.

Patients were placed in the dorsal lithotomy position under general anesthetic and then examined to confirm the diagnosis. Two sets of polypropylene monofilament suture thread with a needle at each end were used. An anchoring suture was sited with the first needle of the first suture thread in the vestibule of the vagina at the level of

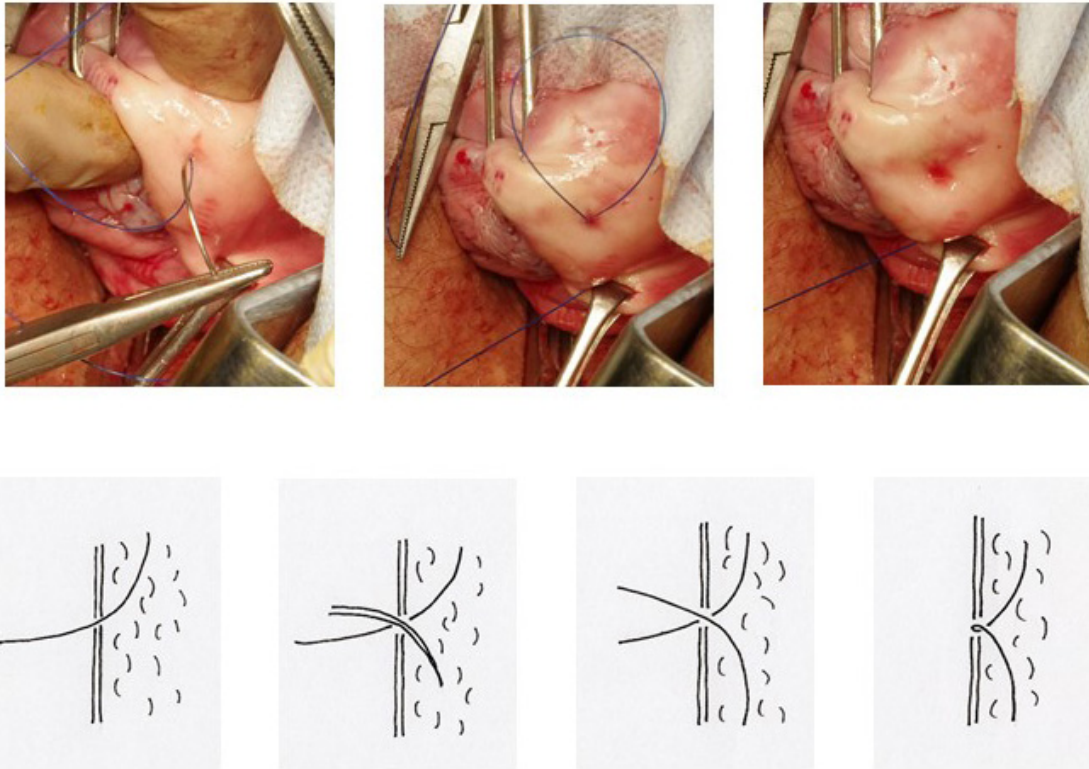


Figure 1. — Schematic representation of the new type of suture for repair of pelvic organ prolapse (POP).

the left bulbo cavernosus muscle, at least 2 cm from the urethra (Figure 2A). The suture described above was then performed from that point through the vaginal wall to the right uterosacral ligament (Figure 2B). The suture was deep enough to include the pubocervical fascia. Using the second needle, the suture was threaded from the previous anchoring suture to the right uterosacral ligament, as described in Figure 2C.

The procedure was duplicated and reversed on the right (Figure 2D). The repair was then continued with the second set of needles from the left to the right uterosacral ligament, crossing the anterior fornix. Using the first set of needles, the repair was mirrored and applied from the right to the left uterosacral ligament (Figure 2E). The suture threads were then pulled at both ends, thus returning the bladder to its normal anatomical position (Figure 2F). Finally, the ends were tied together to secure the correction.

Follow up assessments were performed at 2-4 weeks, three months, six months and one year after surgery. Post-operative check-ups consisted of physical examination, evaluation of prolapse symptoms and patient satisfaction with the procedure. Cure rates, intra-operative and post-operative complication rates were also assessed. Recurrence was defined as POP-Q stage I or higher with or without symptoms noted at any of the follow-up visits.

Statistical analysis was performed using Microsoft Excel 2013. Population data and post-operative complications

Table 1. — *Preoperative clinical characteristics of the patients*

Characteristics	Value
Age (years)	72.3 ± 7.8
Body weight (kg)	56.5 ± 7.4
Body mass index (kg/m <sup>2</sup> )	24.5 ± 3.0
Parity	2.3 ± 0.9
Previous pelvic organ prolapse surgery	6 (30)

Values are presented as mean ± SD, number of women and percentage

were presented as mean ± SD or the number of women and percentage. Follow-up time was presented as median and range.

## Results

Clinical characteristics of the study patients are presented in Table 1. Two gynecologist performed all surgeries according to the technique described above. The mean age of the patients at the time of surgery was 72.3 ± 7.8 years. Six (30%) women had undergone previous surgery for POP, two had a transvaginal mesh (TVM), two had a Manchester surgery, and two had an anterior colporrhaphy.

Surgery time was 83.5 ± 18.3 minutes with a mean blood loss of less than 10 mL. No injury to the bladder (assessed as

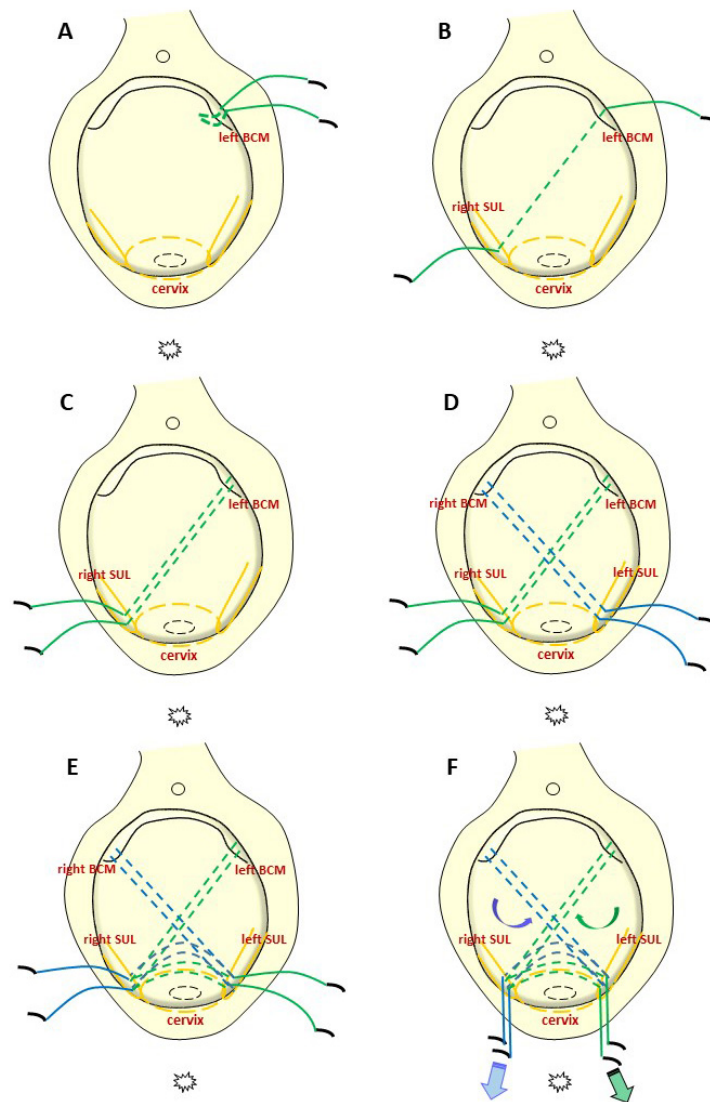


Figure 2. — Schematic representation of the new surgical technique. An anchor-like suture was started at the left bulbo cavernosus muscle (BCM) level (A). A new type of suture was then performed from that point to the right uterosacral ligament (USL) (B). Using the second needle, the same suture was performed in the same direction (C). A different set of suture thread was then used to perform the suture from the opposite side as described above (D). The same suture was then continued from the left to right and from the right to left USL (E). Both ends were pulled to return the bladder to its normal anatomical position (F).

absence of hematuria), rectum or major pelvic vessels were observed, nor any other intra-surgical complications. All patients had improved anatomical results after surgery and none experience postoperative complications. The mean follow-up was 9.9 months (range 6 to 12 months). At the six months-follow-up, one patient presented POP-Q stage II recurrence; but her symptoms were not an indication for treatment. At the final follow-up, no other recurrence was noted (Table 2) and all patients reported to be satisfied with the procedure.

## Discussion

Currently, different surgical techniques are being implemented for the correction of cystocele with the use of native tissue or synthetic mesh. However, the Cochrane review on surgery for anterior compartment prolapse did not support the use of mesh due to increased morbidity [3]. Also, in 2011 the FDA stated that although mesh augmentation may provide an anatomic benefit, it may not result in better symptomatic results [8]. Consequently, native tissue repair is still an option for the repair of cystocele. In this study we describe and evaluate a novel, non-dissection, minimally

Table 2. — Postoperative outcomes and complications of the patients

Characteristics	Value
Fever	0
Hematoma formation	0
Abscess formation	0
Post-operative pelvic pain	0
Recurrence	1 (5)

Values are presented as number of women and percentage.

invasive and low cost method for the repair of anterior compartment prolapse. This technique resulted in positive outcomes and no intraoperative complications, with excellent results throughout the follow-up period.

Cystocele occurs as a result of a defect in the pubocervical fascia [6]. It is possible to correct this defect with purse-string and reinforced sutures resulting in no recurrences and no postoperative voiding complications [6]. Given that many failures of anterior vaginal repairs are due to the weakness of vaginal apical supports [9], the success rates for cystocele repair may be improved by performing a concomitant apical procedure, such as the uterosacral or sacrospinous ligament suspension [4, 10, 11]. The low recurrence rate observed with the surgical method described here may be due to the combination of both pubocervical fascia repair and uterosacral ligament suspension.

Sacrospinous rather than uterosacral ligament suspension is preferred because there is a less risk for ureteral injury [12]. However in the present study, uterosacral ligaments were used as an anchor-like support because of their superior anatomical differentiation. No renal dysfunction due to ureteral plication or ligation was observed in blood tests after surgery (data not shown).

POP is a condition that affects the quality of life and causes a tremendous financial burden on the healthcare system around the world [4]. Consequently, the authors anticipate their new low-cost surgical technique can be applied successfully to this problem, particularly in underdeveloped countries. Although the mean surgery time was longer than the average colporrhaphy, the authors expect that surgery time will decrease with increasing familiarity with the procedure.

The study is limited by the small population sample and the short term follow-up, which may influence the strength of the conclusions. Furthermore, the effects of this surgery on sexual function were not assessed. However, the high success and low complication rates suggest that further research is warranted.

## Conclusion

The authors developed a new non-dissection, minimally invasive and low-cost surgical technique that is effective for anterior wall prolapse repair. Further studies are needed in order to evaluate the validity of our findings for other kinds

of POP.

## Conflict of Interest

The authors declare no competing interests.

Submitted: June 04, 2019

Accepted: September 02, 2019

Published: June 15, 2020

## References

- [1] Choi K.H., Hong J.Y.: "Management of pelvic organ prolapse". *Korean J. Urol.*, 2014, 55, 693.
- [2] Hendrix S.L., Clark A., Nygaard I., Aragaki A., Barnabei V., McTiernan A.: "Pelvic organ prolapse is the Women's Health Initiative: gravity and gravidity". *Am. J. Obstet. Gynecol.*, 2002, 186, 1160.
- [3] Maher C., Feiner B., Baessler K., Christmann-Schmid C., Haya N., Brown J.: "Surgery for women with anterior compartment prolapse". *Cochrane Database Syst. Rev.*, 2016, 11, CD004014.
- [4] Houman, J., Weinberger J.M., Eilber K.S.: "Native tissue repair for pelvic organ prolapse". *Curr. Urol. Rep.*, 2017, 18, 6.
- [5] Barber M.D., Maher C.: "Epidemiology and outcome assessment of pelvic organ prolapse". *Int. Urogynecol. J.*, 2013, 24, 1783.
- [6] Song H., Choo G.Y., Jin L., Yoon S., Lee T.: "Transvaginal cystocele repair by purse-string technique reinforced with three simple sutures: surgical technique and results". *Int. Neurourol. J.*, 2012, 16, 144.
- [7] Lucot J.P., Cosson M., Bader G., Debodinance P., Akladios C., Salet-Lizee D, et al.: "Safety of vaginal mesh surgery versus laparoscopic mesh sacropexy for cystocele repair: results of the prosthetic pelvic floor repair randomized controlled trial". *Eur. Urol.*, 2018, 74, 167.
- [8] U.S. Food and Drug administration: "FDA Safety Communication UPDATE on serious complications associated with transvaginal placement of surgical mesh for pelvic organ prolapse". Available at: <http://www.fda.gov/MedicalDevices/Safety/AlertstandNotices/ucm252435.htm>
- [9] Bureau M., Carlson K.V.: "Pelvic organ prolapse: a primer for urologists". *Can. Urol. Assoc. J.*, 2017, 11, S125.
- [10] Papa Petros P.E.: "The female pelvic floor: function, dysfunction and management according to the integral theory". Berlin: Springer-Verlag Berlin Heidelberg, 2004.
- [11] Geynisman-Tan J., Kenton K.: "Surgical updates in the treatment of pelvic organ prolapse". *Rambam Maimonides Med. J.*, 2017, 8, e0017.
- [12] Weintraub A.Y., Zvi M.B., Yohay D., Neymeyer J., Reuven Y., Neuman M., Tsivian A.: "Safety and short term outcomes of a new truly minimally-invasive mesh-less and dissection-less anchoring system for pelvic organ prolapse apical repair". *Int. Braz. J. Urol.*, 2017, 43, 533.

Corresponding Author:

GIANNINA CALONGOS, M.D., PhD

Kobe Adventist Hospital,

8-4-1 Arinodai, Kita-ku, Kobe (Japan)

e-mail: calongos@kahns.org