

Amniotic fluid embolism: the pathophysiology, diagnostic clue, and blood biomarkers indicator for disease prediction

R. Suvannasarn¹, T. Tongsong¹, P. Jatavan¹

¹Department of Obstetrics and Gynecology, Division of Maternal-Fetal Medicine, Chiang Mai University, Chiang Mai (Thailand)

Summary

Objective: This article aims to review and provide more understanding of current knowledge of amniotic fluid embolism regarding pathophysiology, diagnostic criteria, risk factors, indicating biomarkers, treatment strategies and outcomes of some case reports. **Study design:** A systematic literature review was performed using the PubMed database, restricted to articles published in English from 1992 to 2018. Original research, case reports, guideline recommendations, and review articles were reviewed in this study. **Summary:** Amniotic fluid embolism (AFE) is a rare catastrophic obstetric condition defined by clinical manifestations of pregnancy with sudden onset of cardiopulmonary arrest, consumptive coagulopathy or neurological deficits without other explainable illnesses. The incidence varies from 1.7-14.8 cases per 100,000 worldwide. The current understanding of AFE pathophysiology includes fetal components obstructing maternal microvessels with subsequent anaphylactoid reaction. Maternal pulmonary vasospasm and hematologic activation occur later, followed by heart failure and sudden cardiovascular collapse. Some of the possible risk factors for AFE include; 1) Maternal risk: age over 35 years, hypertensive disorder and diabetes mellitus; 2) Fetal risk: polyhydramnios, multiparity, non-vertex at delivery, fetal distress and fetal macrosomia; 3) Obstetric risks: amniocentesis, artificial amniotic fluid injection, oxytocin infusion, and placental abruption. Some of the useful biomarkers have been proposed including zinc coproporphyrin-1, squamous cell carcinoma antigen, carcinoembryonic antigen, cancer antigen 125, Siatyl Tn, monoclonal antibody TKH-2, C3, C4, trypsin, insulin-like growth factor binding protein-1, C1 esterase inhibitor. Management of AFE requires immediate basic life support and advanced cardiac life support. Adequate oxygenation, ventilation, coagulopathy correction, and appropriate vasopressors are recommended. However, the outcome prediction of AFE remains challenging.

Key words: Amniotic fluid embolism; Pathophysiology; Biomarker; Diagnosis; Cases.

Introduction

Amniotic fluid embolism (AFE) is a rare obstetric emergency condition. Despite its low incidence, maternal and perinatal mortality is still high. This high mortality could be explained by the limitation of disease prediction as well as a scarce diagnostic clue for AFE. Speculating the disease outcomes is also challenging. However, countless studies had been done over the past decades to improve the knowledge of the disease. This study attempts to improve the understanding of the condition and updated pathophysiology, risk factors, useful diagnostic markers, management, and case report outcomes.

Diagnostic criteria for amniotic fluid embolism and incidence

AFE was first described in 1926 by Meyer and recognized widely in 1941 [1]. It is defined by its fundamental features of sudden onset of cardiopulmonary arrest, consumptive coagulopathy, atonic bleeding, acute hypoxia, seizures, disturbed consciousness, acute hypotension, without other explainable illnesses or underlying diseases. However, the diagnostic criteria vary among nations as listed in Fig. 1 [2, 3, 4]. A study by Kobayashi, et al. showed that Japan criteria had a medium agreement with

that of the UK ($k = 0.538$) and the USA ($k = 0.453$). This results in diagnosing different subgroups of patients [4]. Uterine AFE was considered to have occurred when fetal debris and amniotic fluid components were found in the uterus in pathological examination of cases of severe uterine hemorrhage after placental removal (eg. bleeding caused by uterine atony) in absence of other obstetric hemorrhagic complications such as abnormal placentation, trauma during labor and delivery, and severe preeclampsia or eclampsia.

There is no consensus on the true incidence of AFE due to the rarity and variation of diagnostic criteria from countries to countries [5]. However, in the United States, the total cases of AFE have been estimated as 7.7 cases per 100,000 [6]. In Canada, the total rate of AFE in single and multiple birth deliveries was 14.8 and 6.0 per 100 000 singleton deliveries respectively [7]. Incidence of 1.7, 2.5 and 6.1 cases per 100,000 was reported in the United Kingdom, Netherlands, and Australia, respectively [8, 9]. The mortality rate reported by case studies is also varied from 20% to 60% [10].

Pathophysiology of amniotic fluid embolism

Until now, the pathophysiology of AFE remains unclear. Recent studies have proposed that the onset of AFE requires two actions. First, an amniotic fluid containing fetal com-

THE UNITED KINGDOM	THE UNITED STATES	JAPAN
<p>In the absence of any other clear cause, either: Clinical diagnosis: Acute maternal collapse with one or more of the following features: acute fetal compromise; cardiac arrest; cardiac rhythm problems; coagulopathy; hypotension; maternal hemorrhage; premonitory symptoms (e.g. restlessness, numbness, agitation, tingling); seizure; or shortness of breath. Excluding: women with maternal hemorrhage as the first presenting feature, in whom there was no evidence of early coagulopathy or cardiorespiratory compromise. Pathologic diagnosis: made at postmortem examination of fetal squames or hair in lungs.</p>	<ol style="list-style-type: none"> 1. Acute hypotension or cardiac arrest. 2. Acute hypoxia, defined as dyspnea, cyanosis or respiratory arrest. 3. Coagulopathy, defined as laboratory evidence of intravascular consumption or fibrinolysis or severe clinical haemorrhage in the absence of other explanations* 4. Onset of the above during labor, caesarean section or dilatation and evacuation or within 30 minutes post-partum 5. Absence of any other significant confounding condition or potential explanation for the signs and symptoms observed *Patient meeting all other criteria including abrupt cardiorespiratory arrest who died before coagulopathy could be assessed were included in the primary analysis. 	<ol style="list-style-type: none"> 1. Symptoms appeared during pregnancy or within 12 hours of delivery. 2. Intensive medical intervention was conducted to treat one of the following symptoms/diseases <ol style="list-style-type: none"> (a) Cardiac arrest (b) Severe bleeding of unknown origin within 2 hours of delivery (≥ 1500 mL) (c) Disseminated intravascular coagulopathy (d) Respiratory failure 3. If the findings or symptoms obtained could not be explained by other diseases. Consumptive coagulopathy/ DIC due to evident etiologies such as abnormal placentation, trauma during labor, and severe preeclampsia/eclampsia should be excluded.
<p style="text-align: center;">THE NETHERLANDS</p> <ol style="list-style-type: none"> 1. Reported as maternal mortality/severe maternal morbidity with AFE as diagnosis/differential diagnosis. 2. One or more of the following severe enough to require medical treatment: hypotension (and/or cardiac arrest); respiratory distress; DIC; and coma and/or seizures. 3. Absence of any other clear medical explanation for the clinical course. 		<p style="text-align: center;">AUSTRALIA</p> <p>Clinical diagnosis of AFE (acute hypotension or cardiac arrest, acute hypoxia, or coagulopathy in absence of any other potential explanation for signs and symptoms observed) OR Pathologic/postmortem diagnosis (presence of fetal squames/debris in pulmonary circulation).</p>

Figure 1. — Diagnostic criteria of AFE in different countries.

ponents including squamous cells, vernix, lanugo, meconium inflow into the maternal circulation. These materials then enter the exposed and ruptured vessels in the intrauterine cavity or lacerated uterine muscles. The components are capable of obstructing maternal microvessels and can end up as pulmonary emboli. Second, the maternal anaphylactoid reaction occurs against the influx of amniotic fluid in maternal circulation which can activate pulmonary vasospasm and create platelets, factor VII, white blood cells and complement stimulation. This hematologic activation can initiate disseminated intravascular coagulopathy and subsequent coagulation cascade followed by ischemic distal organ dysfunction and multi-organ failure. This process may induce other hemorrhagic complications such as hematuria, bleeding from venipunctures, gastrointestinal bleeding.

The presence of fetal materials or amniotic fluid in myometrium can cause a maternal local immune reaction which might interfere with myometrial function, leading to uterine atony and postpartum hemorrhage which may

present as incoagulable vaginal bleeding in some cases [3, 11]. Embolization may contribute to pulmonary hypertension, right-sided heart failure leading to left ventricular failure and sudden cardiovascular collapse [3, 5, 12]. Regarding immunological reactions, the previous studies revealed some relevant mediators such as tryptase, bradykinin, histamine, endothelin, arachidonic metabolites, and leukotriene. Nevertheless, the laboratory results do not show a significant elevation of these mediator levels [5, 13, 14]. The mechanism of AFE is summarized in Fig. 2.

Risk factors

AFE is a potentially catastrophic condition as it is an unpredictable and unpreventable syndrome. Many attempts have been made to identify the risk factors to overcome or prevent the occurrence of AFE. The risk factors which have been repeatedly reported are as follows: maternal age over 35 years, induction of labor, cesarean section, forceps

Table 1. — Risk factors for AFE.

Maternal Risk	Fetal Risk	Obstetric Risk
- Age over 35 years	- Polyhydramnios	- Amniocentesis
- Hypertensive disorder	- Multiparity	- Artificial amniotic fluid injection
- Pre-eclampsia or eclampsia	- Non-vertex at delivery	- Oxytocin infusion
- Diabetes	- Male fetus	- Cesarean section
	- Fetal distress	- Forceps or vacuum-assisted delivery
	- Fetal macrosomia	- Uterine rupture or laceration
	- Intrauterine death	- Placenta previa
		- Placental abruption
		- Cervical laceration

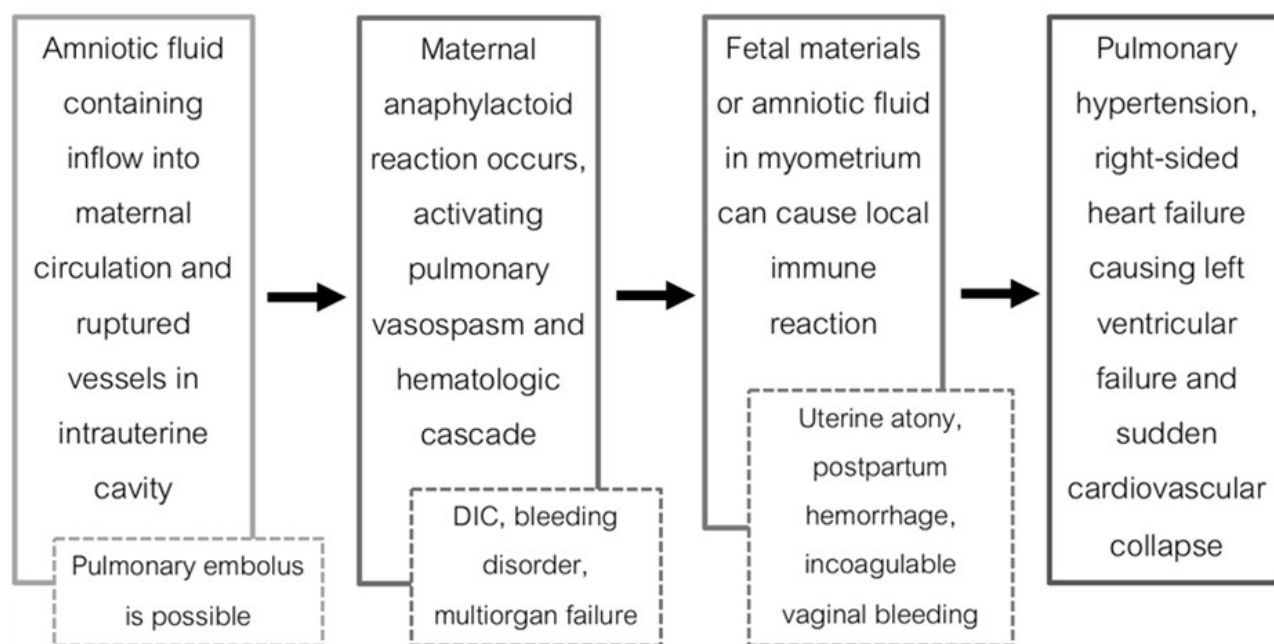


Figure 2. — Mechanism of AFE.

or vacuum-assisted vaginal delivery, uterine rupture or laceration, placenta previa, placental abruption, polyhydramnios, pre-eclampsia, and eclampsia as summarized in Table 1 [6, 15, 16]. However, this may only alert physicians to immediately manage or avoid these risk factors to reduce the prevalence of AFE but also to lower the fatality rate. Oi et al. have proposed eight parameters including dyspnea, cardiac arrest, loss of consciousness, serum sialyl Tn > 47U/mL, serum interleukin-8 > 100 pg/ml, vaginal delivery, multiparity, and term delivery as potential factors to predict mortality rate and more accurate prognosis [1, 12, 17]. In 2018, a systematic review and analysis from a data pool by Indraccolo et al. revealed that among all risk factors, only oxytocin infusion during labor can increase fatality in typical AFE cases [18].

AFE can occur during the first or second trimester of pregnancy as it is also believed to be a complication after amniocentesis and artificial amniotic fluid injection. However, Drukker et al. revealed that over the past 55 years,

there were only two cases of AFE identified after performing amniocentesis in the English literature [15]. However, despite multiple risk factors given, none of them is adequately established to alter standard obstetric care [12].

Biomarkers: the predictor of AFE

The early diagnosis for AFE remains challenging as there is no universal biomarker used for screening AFE. To the current knowledge, some of the useful biomarkers have been purposed as summarized in Table 2. Those primitive markers identified include sialyl Tn (STN) and Zincoporphyrin-1 (ZnCP1) which were proven to be over-expressed in meconium and amniotic fluid [19, 20, 21]. Serum squamous cell carcinoma antigen is also a potentially useful marker as it is only present in amniotic fluid, not in maternal serum [22].

Insulin-like growth factor binding protein-1 (IGFBP-1) has been considered as a valuable biomarker due to its high

Table 2. — Biomarkers and tests proposed for AFE diagnosis.

Author, Year	Marker	Abnormal finding	AFE cases	Non-AFE cases	Sensitivity	Specificity
Kanayama N, 1992 [20]	Zinc	Serum level > 35 nmol/L	4	50	100%	98%
Sarandakou A, 1992 [31]	Coproporphyrin-1	Serum level, Umbilical cord blood, Amniotic fluid level > 5 ng/ml	0	56	-	-
	CEA	Serum level, Umbilical cord blood, Amniotic fluid level > 5 ng/ml	0	56	-	-
	CA-125	Serum level, Umbilical cord blood, Amniotic fluid level > 35 U/ml	0	56	-	-
	Squamous cell carcinoma antigen	Serum level, Umbilical cord blood, Amniotic fluid level > 2.5 ng/ml	0	56	-	-
Kobayashi H, 1993 [19]	Sialyl Tn	Serum level > 50 U/mL	4	32	100%	96%
Kobayashi H, 1997 [29]	Monoclonal antibody TKH-2	Positive staining	4	4	100%	100%
Benson M, 2001 [14]	C3	Serum level < 70 mg/dL	6	22	87.50%	100%
	C4	Serum level < 16 mg/dL	6	22	100%	100%
	Tryptase	Serum level > 2 SD	9	22	0%	-
Iwai K, 2011 [21]	Sialyl Tn	Serum level > 47 U/ml	127	74	77.80%	-
	Sialyl-Tn	Serum level > 47 U/ml	127	74	25.80%	97.30%
	Zinc coproporphyrin-1	Serum level > 1.6 pmol/ml	127	74	45.90%	73%
Legrand M, 2012 [23]	Insulin-like growth factor binding protein-1	Serum level > 104.5 nmol/L	25	94	92%	97.80%
Tanura N, 2014 [25]	C1 Esterase inhibitor	Serum activity level 25%	106	88	-	-
Koike N, 2017 [22]	Squamous cell carcinoma antigen	Serum level > 7.15 ng/mL	20	74	60.00%	89.20%

concentration in amniotic fluid. It could be detected in maternal serum even in case of amniotic fluid leakage into maternal circulation in only a very small amount. IGFBP-1 level is low in normal pregnancy and was proven to rise after the onset of AFE [23]. A case report by Wernet et al. revealed that alpha-fetoprotein (AFP) and insulin-like growth factor binding protein-1 were increased fourfold during the onset of AFE after performing dilatation and curettage in the first trimester. This might be helpful in early diagnosis and rapid management of AFE [24].

Furthermore, numerous reports have demonstrated that the complement system plays a role in AFE resulting in decreased maternal complement levels. C1 Esterase inhibitor (C1INH) activity levels are significantly lower in AFE cases and lowest in fatal A>FE patients indicating that C1INH is a potential prognostic factor [25]. C3 and C4 levels are significantly depressed in AFE from previous studies [1, 14]. Regarding subsequent mast cell activities, the tryptase levels are inconsistent and relatively unpredictable among studies and therefore cannot be used as a diagnostic tool for AFE [14, 26]. Campanharo et al. reported a

case of maternal SLE with AFE measuring a decrease of the C3a level. This indicated that the complement activation was secondary to the patient's SLE. For this reason, patients with autoimmune disease should be observed with closed surveillance [27].

Some specific cytokines including Interleukin 6 (1500-2000 pg/ml), interleukin 8 (500-700pg/ml) and tumor necrosis factor alpha-soluble receptor p55 (sTNFp55) are detected in amniotic fluid. These unique markers are useful in identifying AFE in cases with systemic inflammatory response syndrome [16, 28].

AFE can also be histologically diagnosed by specific staining. The TKH-2 is an antibody that reacts with meconium and amniotic fluid-derived mucin-type glycoprotein. The TKH-2 immunostaining is present in the pulmonary vasculature of patients with AFE, which can be easily missed by the conventional hematoxylin-eosin stain. Moreover, it was reported that no TKH-2 staining was found in non-AFE patients. Therefore TKH-2 has been considered as a potential sensitive method to diagnose AFE [16, 28, 29]. The presence of amniotic components using

Table 3. — Cases reports of AFE and outcomes.

Author, Year	Age	GA (week)	Route of delivery	Onset	Cardiac arrest	Outcome	Remark
MahshidN, 2009 [34]	27	35	Cesarean section	Following placental delivery	Yes	Died	
Lee JH, 2010 [35]	33	40 + 6	Cesarean section	5 minutes after spinal block	Yes	Died	
Hosoya Y, 2013 [36]	40	36	Cesarean section	-	Yes	Resolved	
Campanharo FF, 2015 [27]		33	Cesarean section	Rapidly after anesthetic block	No	Resolved	Maternal underlying of systemic lupus erythematosus
Mita K, 2017 [37]	29	37	Cesarean section	After placental delivery	Yes	Resolved	Complicated with pheochromocytoma crisis
Drukker L, 2017 [15]	36	24	-	Rapidly after amnio-centesis	No	Resolved	Maternal underlying of portal hypertension, portal vein thrombosis, esophageal varices, factor V Leiden homozygosity, hypothyroidism
Tinres F, 2017 [38]	35	39	Cesarean section	4 hours after epidural analgesia	Yes	Resolved	Successfully treated by venoarterial extracorporeal membrane oxygenation
Lynch W, 2017 [39]	28	41	Vaginal delivery with vacuum extraction	After labor epidural catheter was placed	Yes	Resolved	Lipid emulsion infusion was applied for rescue
Chen W, 2018 [40]	28	39	Vaginal delivery with forceps extraction	20 minutes after artificial rupture of membrane	Yes	Died	Complicated with maternal hepatic rupture
Maack KH, 2018 [41]	40	40 + 2	Cesarean section	Immediately after spontaneous rupture of membrane	Yes	Resolved	Complicated with maternal right heart mass
Seong GM, 2018 [10]	32	39 + 1	Vaginal delivery	After entirely opened cervix	Yes	Resolved	Successfully treated by venoarterial extracorporeal membrane oxygenation

hematoxylin-eosin, alcian blue and sialyl-Tn in the uterine vasculature was also evaluated in DIC-type PPH. Nevertheless, the result showed no significant finding [30].

Some tumor markers (squamous cell carcinoma [SCC] antigen, carcinoembryonic antigen [CEA], and cancer antigen-125 [CA-125]) have been found significantly elevated in amniotic fluid when compared to those in umbilical cord blood and maternal serum. Hence, further considerable efforts should be made to introduce these markers as a diagnostic tool for AFE [31]. Moreover, there are some proteins that specifically present in amniotic fluid, including Procollagen type I N-terminal propeptide (PINP), Pro-early placenta insulin-like peptide (ProEPIL), Annexin I, Brain Natriuretic Peptide (BNP), Pro-Opiomelanocortin (POMC), Chromogranin A (CgA). (However, these are not conventional markers and more researches is need to eluci-

date their potential roles in AFE [28].

It is recognized that coagulopathy is one of the predominant features of AFE which occurs in a remarkably short period. Early measurement of fibrinogen levels may help reduce the risk of maternal death from AFE [32].

Amniotic fluid embolism: management and outcomes

According to Society for Maternal-Fetal Medicine guidelines, AFE should be one of the differential diagnosis for the case of any pregnant woman or recently postpartum patient with sudden cardiopulmonary compromise or cardiac arrest, in which basic life support and advanced cardiac life support protocols should be immediately activated and performed as in a non-pregnant individual manner.

The additional components in rescuing cardiac arrest pregnant women include: 1) Lateral displacement of the

uterus to prevent aortocaval compression 2) Removing fetal monitor is recommended during cardioversion or defibrillation although the presence of monitors should not delay defibrillation and 3) An immediate fetal delivery (assisted vaginal delivery/cesarean section) should be performed if fetal survival is expected or gestational age of ≥ 23 weeks.

AFE should be diagnosed based on clinical features and immediately managed. No laboratory test is required for confirming AFE. A multidisciplinary team (anesthesia, respiratory therapy, critical care, and maternal-fetal medicine) should be involved.

After successful resuscitation, a postcardiac arrest patient must be closely monitored and targeted as follows: 1) Mean arterial pressure of 65 mmHg, 2) Pulse oximetry at the value of 94-98%, 3) The serum glucose level at 140-180 mg/dL, and 4) Body temperature at 32-36°C for 12-24 hours to improve neurological outcomes.

In the early phase, transthoracic and/or transesophageal echocardiography can be applied, monitor ongoing right ventricular failure. Hypoxia, hypercapnia, and acidosis should be avoided. After the right heart function improves, left ventricular failure along with cardiogenic pulmonary edema usually follow in a later phase [12]. Adequate oxygenation, ventilation, and appropriate vasopressors or inotropic drugs are recommended. High-dose adrenocorticosteroid is effective on some occasions [3]. Excessive fluid administration should be avoided. Dialysis may be indicated in severe pulmonary congestion unresponsive to diuretic drugs [12].

Disseminated intravascular coagulation usually presents either shortly after a cardiovascular collapse or in the later phases. Therefore, early assessment of coagulopathy and aggressive management of clinical bleeding with standard transfusion protocols is recommended. It has been reported that rapid transfusion of cryoprecipitates or FFP can alleviate patients in critical condition. A platelet count above 50,000/mm³ and normal (or close to normal) activated partial thromboplastin time and international normalized ratio should be maintained [12]. It was previously suggested to administer heparin in AFE with DIC patients. However, heparin may induce severe bleeding. Therefore using heparin is not currently recommended [3]. In cases of uterine atony, uterotonic agents such as oxytocin, ergot derivatives, and prostaglandins are appropriate as indicated. Other surgical management such as uterine tamponade, uterine artery ligation, B-Lynch stitch or hysterectomy may be required in more severe cases of postpartum hemorrhage [12].

The mortality rate has been reported to be varied between 20% and 60% [10, 33]. Maternal mortality rate per 100,000 live births has been estimated to be 0.4 in the Netherlands, 0.5 in the United Kingdom and Sweden, 0.7 in Canada, 1.5 in Australia and 1.0-1.7 in the United States [9, 33]. However, the understanding of AFE has improved in the last decade. Some available case reports and the following outcomes are in Table 3.

Conclusion

AFE is a rare condition but often leads to lethal consequence and the current knowledge is still limited. Over the past few decades, a lot of attempts have been made to gain more understanding of the disease. Pathophysiology, some risk factors, and diagnostic markers are identified and reviewed here in this article. A high quality basic and advanced life support, adequate oxygenation and coagulopathy correction along with a multidisciplinary team approach should be performed. Further investigations and research is required to improve the understanding of the disease. This review has offered some useful clinical points and management which should be applied in a case-by-case manner.

Acknowledgment

This work was partially supported by the Chiang Mai University Fund (TT).

Conflict of interest

There is no conflict of interest to declare.

References

- [1] Oi H., Naruse K., Noguchi T., Sado T., Kimura S., Kanayama N., et al.: "Fatal factors of clinical manifestations and laboratory testing in patients with amniotic fluid embolism". *Gynecol. Obstet. Invest.*, 2010, 70, 138.
- [2] Clark S.L., Romero R., Dildy G.A., Callaghan W.M., Smiley R.M., Bracey A.W., et al.: "Proposed diagnostic criteria for the case definition of amniotic fluid embolism in research studies". *Am. J. Obstet. Gynecol.*, 2016, 215, 408.
- [3] Kanayama N., Tamura N.: "Amniotic fluid embolism: pathophysiology and new strategies for management". *J. Obstet. Gynaecol. Res.*, 2014, 40, 1507.
- [4] Kobayashi H., Akasaka J., Naruse K., Sado T., Tsunemi T., Niiri E., et al.: "Comparison of the Different Definition Criteria for the Diagnosis of Amniotic Fluid Embolism". *J. Clin. Diagn. Res.*, 2017, 11, QC18.
- [5] Ito F., Akasaka J., Koike N., Uekuri C., Shigemitsu A., Kobayashi H.: "Incidence, diagnosis and pathophysiology of amniotic fluid embolism". *J. Obstet. Gynaecol.*, 2014, 34, 580.
- [6] Abenhaim H.A., Azoulay L., Kramer M.S., Leduc L.: "Incidence and risk factors of amniotic fluid embolisms: a population-based study on 3 million births in the United States". *Am. J. Obstet. Gynecol.*, 2008, 199, 49.e1.
- [7] Kramer M.S., Rouleau J., Baskett T.F., Joseph K.S., System MHS-GotCPS.: "Amniotic-fluid embolism and medical induction of labour: a retrospective, population-based cohort study". *Lancet*, 2006, 368, 1444.
- [8] Fitzpatrick K.E., Tuffnell D., Kurinczuk J.J., Knight M.: "Incidence, risk factors, management and outcomes of amniotic fluid embolism: a population-based cohort and nested case-control study". *BJOG*, 2016, 123, 100.
- [9] Knight M., Berg C., Brocklehurst P., Kramer M., Lewis G., Oats J., et al.: "Amniotic fluid embolism incidence, risk factors and outcomes: a review and recommendations". *BMC Pregnancy Childbirth*, 2012, 12, 7.
- [10] Seong G.M., Kim S.W., Kang H.S., Kang H.W.: "Successful extracorporeal cardiopulmonary resuscitation in a postpartum patient with amniotic fluid embolism". *J. Thorac. Dis.*, 2018, 10, E189.
- [11] Farhana M., Tamura N., Mukai M., Ikuma K., Koumura Y., Furuta N., et al.: "Histological characteristics of the myometrium in the postpartum hemorrhage of unknown etiology: a possible involvement of local immune reactions". *J. Reprod. Immunol.*, 2015, 110, 74.
- [12] Society for Maternal-Fetal Medicine (SMFM), Pacheco L.D., Saade

- G., Hankins G.D., Clark S.L.: "Amniotic fluid embolism: diagnosis and management". *Am. J. Obstet. Gynecol.*, 2016, 215, B16.
- [13] Busardò F.P., Frati P., Zaami S., Fineschi V.: "Amniotic fluid embolism pathophysiology suggests the new diagnostic armamentarium: β -tryptase and complement fractions C3-C4 are the indispensable working tools". *Int. J. Mol. Sci.*, 2015, 16, 6557.
- [14] Benson M.D., Kobayashi H., Silver R.K., Oi H., Greenberger P.A., Terao T.: "Immunologic studies in presumed amniotic fluid embolism". *Obstet. Gynecol.*, 2001, 97, 510.
- [15] Drukker L., Sela H.Y., Ioscovich A., Samueloff A., Grisaru-Granovsky S.: "Amniotic Fluid Embolism: A Rare Complication of Second-Trimester Amniocentesis". *Fetal Diagn. Ther.*, 2017, 42, 77.
- [16] Sultan P., Seligman K., Carvalho B.: "Amniotic fluid embolism: update and review". *Curr. Opin. Anaesthesiol.*, 2016, 29, 288.
- [17] Oi H., Naruse K., Koike N., Tsunemi T., Shigetomi H., Kanayama N., et al.: "Predictor of mortality in patients with amniotic fluid embolism". *J. Obstet. Gynaecol. Res.*, 2014, 40, 941.
- [18] Indraccolo U., Battistoni C., Mastrantonio I., Di Iorio R., Greco P., Indraccolo S.R.: "Risk factors for fatality in amniotic fluid embolism: a systematic review and analysis of a data pool". *J. Matern. Fetal Neonatal Med.*, 2018, 31, 661.
- [19] Kobayashi H., Ohi H., Terao T.: "A simple, noninvasive, sensitive method for diagnosis of amniotic fluid embolism by monoclonal antibody TKH-2 that recognizes NeuAc alpha 2-6GalNAc". *Am. J. Obstet. Gynecol.*, 1993, 168, 848.
- [20] Kanayama N., Yamazaki T., Naruse H., Sumimoto K., Horiuchi K., Terao T.: "Determining zinc coproporphyrin in maternal plasma—a new method for diagnosing amniotic fluid embolism". *Clin. Chem.*, 1992, 38, 526.
- [21] Iwai Ho K., Tsunemi T., Naruse K., Noguchi T., Sado T., Kobayashi H., et al.: "Sialyl Tn and Zinc coproporphyrin 1 as potential serum markers of amniotic fluid embolism". *Adv. Obstet. Gynecol.*, 2011, 63, 483.
- [22] Koike N., Oi H., Naruse K., Kanayama N., Kobayashi H.: "Squamous cell carcinoma antigen as a novel candidate marker for amniotic fluid embolism". *J. Obstet. Gynaecol. Res.*, 2017, 43, 1815.
- [23] Legrand M., Rossignol M., Dreux S., Luton D., Ventré C., Barranger E., et al.: "Diagnostic accuracy of insulin-like growth factor binding protein-1 for amniotic fluid embolism". *Crit. Care Med.*, 2012, 40, 2059.
- [24] Wernet A., Luton D., Muller F., Ducarme G.: "Use of insulin-like growth factor binding protein-1 for retrospective diagnosis of amniotic fluid embolism in first trimester". *Arch. Gynecol. Obstet.*, 2014, 289, 461.
- [25] Tamura N., Kimura S., Farhana M., Uchida T., Suzuki K., Sugi-hara K., et al.: "Cl esterase inhibitor activity in amniotic fluid embolism". *Crit. Care Med.*, 2014, 42, 1392.
- [26] Benson M.D.: "Current concepts of immunology and diagnosis in amniotic fluid embolism". *Clin. Dev. Immunol.*, 2012, 2012, 946576.
- [27] Campanharo F.F., Santana E.F., Araujo Júnior E., Sarmiento S.G., Fernandes F.C., Sun S.Y., et al.: "Amniotic embolism with complement activation in a lupic pregnant woman". *J. Obstet. Gynaecol.*, 2015, 35, 416.
- [28] Hiroshi Kobayashi, Toshiyuki Sado, Taketoshi Noguchi, Shozo Yoshida, Hiroshi Shigetomi, AOaHO." Search for Amniotic Fluid-Specific Markers: Novel Biomarker Candidates for Amniotic Fluid Embolism". *Open Womens Health J.*, 2011, 5, 7.
- [29] Kobayashi H., Ooi H., Hayakawa H., Arai T., Matsuda Y., Gotoh K., et al.: "Histological diagnosis of amniotic fluid embolism by monoclonal antibody TKH-2 that recognizes NeuAc alpha 2-6GalNAc epitope". *Hum. Pathol.*, 1997, 28, 428.
- [30] Nakagami H., Kajihara T., Kamei Y., Ishihara O., Kayano H., Sasaki A., et al.: "Amniotic components in the uterine vasculature and their role in amniotic fluid embolism". *J. Obstet. Gynaecol. Res.*, 2015, 41, 870.
- [31] Sarandakou A., Kontoravdis A., Kontogeorgi Z., Rizos D., Phocas I.: "Expression of CEA, CA-125 and SCC antigen by biological fluids associated with pregnancy". *Eur. J. Obstet. Gynecol. Reprod. Biol.*, 1992, 44, 215.
- [32] Tanaka H., Katsuragi S., Osato K., Hasegawa J., Nakata M., Murakoshi T., et al.: "Value of fibrinogen in cases of maternal death related to amniotic fluid embolism". *J. Matern. Fetal Neonatal Med.*, 2017, 30, 2940.
- [33] Conde-Agudelo A., Romero R.: "Amniotic fluid embolism: an evidence-based review". *Am. J. Obstet. Gynecol.*, 2009, 201, 445.e1.
- [34] Mahshid N., Ahmad S., Nahid M., Afshin F.: "Sudden cardiac arrest during cesarean section — a possible case of amniotic fluid embolism". *Middle East J. Anaesthesiol.*, 2009, 20, 315.
- [35] Lee J.H., Yang H.J., Kim J.H., Lee S.Y., Gill H.J., Kim B.K., et al.: "Amniotic fluid embolism that took place during an emergent Cesarean section -A case report". *Korean J. Anesthesiol.*, 2010, 59, S158.
- [36] Hosoya Y., Watanabe M., Terashima M., Amiya E., Nakao T., Hasegawa A., et al.: "Cardiac magnetic resonance imaging in a patient with amniotic fluid embolism associated with severe cardiopulmonary complications". *Int. Heart J.*, 2013, 54, 119.
- [37] Mita K., Tsugita K., Yasuda Y., Matsuki Y., Obata Y., Kamisawa S., et al.: "A successfully treated case of cardiac arrest after Caesarean section complicated by pheochromocytoma crisis and amniotic fluid embolism". *J. Anesth.*, 2017, 31, 140.
- [38] Tincrès F., Conil J.M., Crognier L., Rouget A., Georges B., Ruiz S.: "Veno-arterial extracorporeal membrane oxygenation in a case of amniotic fluid embolism with coexisting hemorrhagic shock: lessons learned". *Int. J. Obstet. Anesth.*, 2018, 33, 99.
- [39] Lynch W., McAllister R.K., Lay J.F., Culp W.C.: "Lipid Emulsion Rescue of Amniotic Fluid Embolism-Induced Cardiac Arrest: A Case Report". *Case Rep.*, 2017, 8(3), 64-66.
- [40] Chen W., Qi J., Shang Y., Ren L., Guo Y.: "Amniotic fluid embolism and spontaneous hepatic rupture during uncomplicated pregnancy: a case report and literature review". *J. Matern. Fetal Neonatal Med.*, 2018, 1.
- [41] Maack K.H., Munk K., Dahl K., Jørgensen H.H., Christiansen A., Helmig R.B.: "Right heart masses demonstrated by echocardiography in a patient with amniotic fluid embolism during labour". *Acta Anaesthesiol. Scand.*, 2018, 62, 134.

Corresponding Author:

P. JATAVAN, M.D.

Department of Obstetrics and Gynecology

Division of Maternal – Fetal Medicine

Chiang Mai University, Chiang Mai (Thailand)

e-mail address: kod.thanata@gmail.com