

A comparative study of three ultrasonic elastographic methods for the differentiation and diagnosis of benign and malignant breast masses

F. Tang^{1*}, Y.-F. Kang^{2*}, G.-L. Lu², Z.-J. Wang², Z.-S. Zhang³, S.-Z. Xu⁴, T.-T. Du², J. Tong², J. Li²

¹Department of General Surgery, ²Department of Function, The First Affiliated Hospital of Medical College of Shihezi University, Shihezi, Xinjiang
³Department of Physiology and Pathophysiology, ⁴Department of Statistics, Medical College of Shihezi University, Shihezi, Xinjiang (China)

Summary

Background: To evaluate the application of three elastography methods including real-time tissue elasticity imaging (RTE), strain rate ratio elasticity imaging (SR), and acoustic radiation force elastic imaging (ARFI) in two ultrasound instruments for the diagnosis of benign and malignant breast lesions. **Materials and Methods:** The authors examined 97 breast nodules of 97 patients who were ready to undergo adenomammectomy. For each patient, RTE was applied to determine nodule properties by level 5 score method, SR was applied to measure the strain rate ratio of targeted nodules, and the surrounding mammary glands at the same level, ARFI was applied to measure internal and marginal shear wave velocity (SWV) values of targeted nodules. **Results:** The sensitivity and specificity of RTE, SR, the internal SWV values, and marginal SWV values were more than 80% in diagnosing breast nodules. Area under the curve of RTE, SR, the internal SWV values, and the marginal SWV values in diagnosis of benign and malignant breast nodules were 0.923, 0.934, 0.934 and 0.916, respectively. No significant differences were found among the four values for the diagnosis efficiency. **Conclusions:** RTE, SR, and ARFI are all highly valuable in diagnosing benign and malignant breast nodules.

Key words: Ultrasonic elastography; Breast masses; Real-time tissue elasticity imaging; Strain rate ratio elasticity imaging; Acoustic radiation force elastic imaging; Differential diagnosis.

Introduction

Breast cancer is the most common cancer among women worldwide [1]. It is essential to evaluate the nature of breast masses accurately at an early stage. B-mode ultrasonography (BUS) has been proven to be useful in differentiating benign from malignant breast masses [2, 3], although this modality is limited by its low specificity [4, 5]. Elasticity is an important reference value for disease diagnosis, which is closely related to biological characteristics. Ultrasound elastography has attracted the attention of clinicians for extending the connotation of ultrasonic diagnosis theory and the scope of ultrasonic diagnosis. Studies have shown that real-time tissue elasticity imaging (RTE), strain rate ratio elasticity imaging (SR), and acoustic radiation force impulse (ARFI) elastography have the potential to differentiate benign from malignant breast masses [6-10]. Currently, many ultrasonic diagnostic instruments are equipped with elastic imaging software, making elasticity imaging more and more popular [11-13]. To find the best method of ultrasonic elasticity for diagnosing breast mass properties, the authors examined the application value in the differential diagnosis using real-time tissue elasticity imaging (RTE), strain rate ratio elasticity imaging (SR), and acoustic radiation force

elastic imaging (ARFI) methods by comparing ultrasound images with postoperative pathologic results of 97 breast masses.

Materials and Methods

This prospective study was approved by the First Affiliated Hospital of the Medical College of Shihezi University Ethical Review Committee and all patients signed informed consent.

In total, 97 masses in 97 patients who were ready to undergo mastectomy at the First Affiliated Hospital of Shihezi University Medical College were enrolled in this study from February 2014 to April 2015, undergoing US, RTE, SR, and ARFI checks in turn. The sizes of the masses were 0.7×0.5×0.7 cm to 0.7×1.7×3.8 cm. The ages ranged from 21-78 years, and the average age was 46.69 ± 12.84 years. The diagnostic golden standard of all masses were based on pathologic diagnoses. The patients had never been treated with radiotherapy, chemotherapy, or endocrine therapy pre-operatively.

RTE and SR were performed using 9L4, a real-time linear array high-frequency probe. A real-time tissue elastography unit was used for SR measurement. ARFI was performed using a color Doppler ultrasonic diagnosis apparatus. A 9L4 probe with a frequency of 5.0~14.0 MHz was applied to perform ARFI technology.

At first, the authors set the instruments on breast check conditions. Patients were instructed to assume a supine position, to fully

*Contributed equally.

expose the breasts, and to raise both hands over heads. The general characteristics of mammary gland masses were examined by routine ultrasound for size, shape, location, boundary, aspect ratio, echo, and whether or not there was attenuation and calcifications. RTE-graded elastic images were judged according to the Tsukuba Elasticity Score, [14] as follows: 1 point, the entire masses was green, 2 points, the masses were a mosaic of green and blue, 3 points, the peripheral areas of the masses were green and the center was blue, 4 points, the entire mass was blue, and 5 points, both the mass and the surrounding tissue were blue. The elasticity images were diagnosed as benign with a score of 1-3 points and malignant with a score of 4-5 points. The authors activated the elasticity imaging function, setting the upper bound as breast hypodermic adipose tissue and the lower bound as chest muscle tissue, with both sides including at least 5 mm of surrounding tissues. The authors set the hand-held probe slightly vibrated in masses areas, which was appropriate when the QF value of the instrument display screen was between 45 and 60. For ARFI technology, the authors gently controlled the probe without pressure on the targeted masses. Then, elastic sampling frames were set vertically to the scanning parts of the region of interest (ROI) to record the shear wave velocity (SWV). Caution was exercised to avoid the calcification and liquefied necrotic areas. As the measurable SWV range was 0-9 m/s, it could be taken as 9 m/s if the value was beyond the measurable scope of the instrument when appearing as "x.xx m/s".

SPSS13.0 software was used for data processing. Measurement data are presented as $\pm s$. A *t*-test was used for comparisons among groups. A χ^2 test was used for count data. Drawing the RTE, SR, and SWV ROC curve, Delong's test was utilized for the differences in the area under the curve (AUC). The tangency point of the highest point of the Youden index was considered the best cut-off value. The pathologic diagnosis was designated as the gold standard. The sensitivity, specificity, and accuracy of RTE, SR, and SWV in diagnosing benign and malignant breast masses were calculated. A $p < 0.05$ for the difference was considered statistically significant.

Results

Among the 97 masses, 36 were malignant and 61 were benign. The age range was 21-81 years, and the average age was 46.69 ± 12.84 years. The average age of patients with malignant masses was 54.94 ± 11.72 years, and the average age of patients with benign masses was 52.82 ± 10.89 years; no statistically significant difference existed between patients with benign and malignant masses. Thirty-six malignant masses (33 infiltrating ductal carcinomas, one invasive lobular carcinoma, one ductal carcinoma *in situ*, and one acidophil breast carcinoma), and 61 benign masses (22 fibromas, 21 adenomas, seven adenosis with adenomas, three adenosis with intraductal papillomas, two fat necrosis, two adenosis with fibromas, one lipoma, one plasmocytic mammitis, one mammary duct expansion, and one papilloma) were reported. The specific distribution of variety pathologic results are shown in Table 1.

The sensitivity of RTE in diagnosing benign and malignant masses was 80.3% (49/61), the specificity was 100% (36/36), the accuracy rate was 87.65% (85/97), the Youden index was 0.803 (0.803+1-1), the positive predictive value was 100% (49/49), and the negative predictive value was

Table 1. — Pathologic results of the examined malignant and benign breast masses.

Pathologic diagnosis	No. of masses (%)
Malignant (n=36)	
Invasive ductal carcinoma	33 (91.6)
Invasive lobular carcinoma	1 (2.8)
Ductal carcinoma <i>in situ</i>	1 (2.8)
Oncocytic carcinoma of breast	1 (2.8)
Benign (n=61)	
Fibrocystic change	22 (36.1)
Fibroadenoma	21 (34.4)
Papilloma	1 (1.6)
Adiponecrosis	2 (3.3)
Lipoma	1 (1.6)
Other	14 (23.0)

Table 2. — RTE values to identify benign and malignant breast masses.

RTE	Pathologic diagnosis		Total
	Benign	Malignant	
Benign (score ≤ 3)	49	0	49
Malignant (score ≥ 4)	12	36	48
Total	61	36	97

75% (36/48). The specific results are shown in Table 2 (Figures 1A and 1D).

The range of 61 benign breast masses SR values was from 1.06-6.41, and the average value was 2.39, while the range of SR value of 36 malignant mammary gland masses was from 2.16-16.33, and the average value was 5.66. The SR values of malignant mammary gland masses were higher than the benign breast masses, without a statistically significant difference ($t = -8.387$, $p = 0.000$; Figures 1A and Figure 1D). Using 2.89 m/s as the best cut-off value, the authors achieved the greatest Youden index for diagnosing benign and malignant breast masses. The sensitivity was 83.6% (51/61), the specificity was 97.2% (35/36), the accuracy rate was 88.7% (86/97), the Youden index was 0.808 (0.836 + 0.972-1), the positive predictive value was 98.1% (51/52), and the negative predictive value was 97.2% (35/45). The specific results are shown in Table 3.

The internal SWV results of the masses were as follows: the SWV values of 61 breast benign masses were from 1.33-9.00 m/s, the average was 3.19 m/s, SWV values of 36 malignant breast masses were from 1.74-9.00, and the average was 8.46 m/s. The SWV values of malignant masses were higher than benign breast masses with a significant statistically difference ($t = -13.311$, $p < 0.001$; Figures 1B and 1E). Using 8.85 m/s as the best cut-off value, the value of the ARFI method for diagnosing benign and malignant breast masses were as follows: the sensitivity was 93.4% (57/61), the specificity was 91.7% (33/36), the accuracy rate was 92.8 (90/97), the Youden index was 0.851 (0.934 + 0.917-1), the positive predictive value was 95.0% (57/60), and the negative predictive value was 89.2% (33/37). The

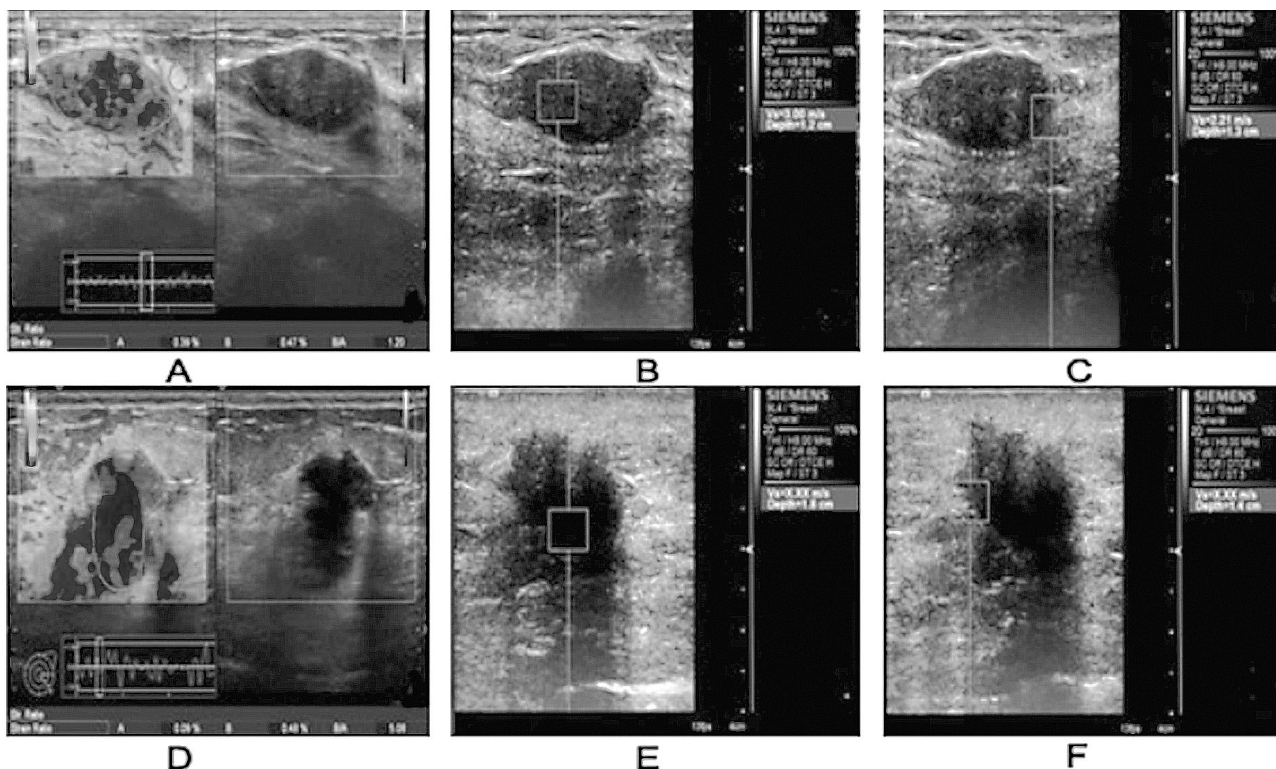


Figure 1. — Two hypoechoic masses on ultrasonography, which are benign (A, B, and C) and invasive ductal carcinoma (E, F, and G) by postoperative pathologic results, respectively. (A) RTE elasticity score is 3 and SR is 1.20. (B) The internal SWV value is 2.85 m/s. (C) The marginal SWV value is 2.37 m/s. (E) RTE elasticity score is 4 and the SR is 5.06. (F) The internal SWV value is X.XX m/s. (G) The marginal SWV value is X.XX m/s.

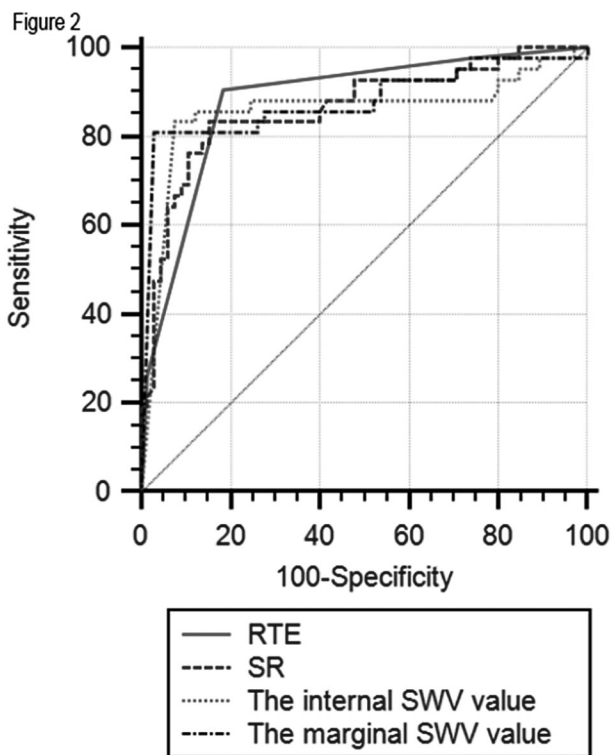


Figure 2. — ROC curves of RTE, SR, the internal SWV value, and the marginal SWV value.

specific results are shown in Table 4.

The marginal SWV values of 61 benign breast masses were from 1.17-9.00 m/s, and the average value was 2.70 m/s. The marginal SWV values of 36 malignant breast masses were from 2.08-9.00 m/s, and the average value was 8.27 m/s. The marginal SWV values of malignant breast masses were higher than benign breast masses; the difference was statistically significant ($t = 16.048, p < 0.001$; Figures 1C and 1F). Using 8.74 m/s as the best cut-off value, the values of the ARFI method for diagnosing the benign and malignant breast masses were as follows: the sensitivity, specificity, and accuracy rate were 98.4% (60/61), 88.9% (32/36), and 94.8% (92/97), respectively. The Youden index was 0.873 (0.984 + 0.889-1), the positive predictive value was 93.8% (60/64), and the negative predictive value was 97.0% (32/33). The specific results are shown in Table 5.

ROC curves of SR values, the internal SWV values, and the marginal SWV values were used to diagnose benign and malignant masses (Figure 2). The diagnostic efficiencies of RTE, SR, the internal SWV values, and the marginal SWV values were compared. No significant difference occurred in the diagnostic efficiency between any two methods ($p > 0.05$). The specific results are shown in Table 6.

Table 3. — SR to identify benign and malignant breast masses.

SR	Pathologic diagnosis		Total
	Benign	Malignant	
Benign (< 2.89)	51	1	52
Malignant (\geq 2.89)	10	35	45
Total	61	36	97

Table 4. — The internal SWV values of masses to identify benign and malignant breast masses.

The internal SWV value	Pathologic diagnosis		Total
	Benign	Malignant	
Benign (< 8.85)	57	3	60
Malignant (\geq 8.85)	4	33	37
Total	61	36	97

Table 5. — The marginal SWV values to identify benign and malignant breast masses.

Border of masses	Pathologic diagnosis		Total
	Benign	Malignant	
Benign (< 8.74)	60	4	64
Malignant (\geq 8.74)	1	32	33
Total	61	36	97

Table 6. — Pairwise comparison of ROC curves.

Methods	Difference between areas	Z statistic	Significance level
RTE vs. SR	0.018	0.657	0.511
RTE vs. internal SWV value	0.023	0.526	0.599
RTE vs. marginal SWV value	0.002	0.042	0.967
SR vs. internal SWV value	0.005	0.117	0.907
SR vs. marginal SWV value	0.017	0.401	0.689
Internal SWV value vs. marginal SWV value	0.022	1.172	0.241

Discussion

Currently, tissue elastic information is an important reference value for disease diagnosis; however, traditional medical imaging methods, such as ultrasound, MRI, and CT, do not directly provide tissue elasticity information. With the development of physics and ultrasound technology, elastic imaging has had a significant impact in reflecting tissue hardness. Based on the difference in elastic coefficient between breast tumor and normal tissue, the authors determined whether or not the breast masses were benign or malignant. [15] Currently, RTE, SR, and ARFI have become new methods for evaluating breast masses; however, few related reports have discussed whether or not there is any difference among the three methods for the identification of benign and malignant breast masses. The present study compared the nature of breast masses through three kinds of elastography.

In this study, the diagnostic performance of RTE in di-

agnosing benign and malignant breast masses were as follows: the sensitivity was 80.3%, the specificity was 100%, the accuracy rate was 87.65%, the Youden index was 0.803, the positive predictive value was 100%, the negative predictive value was 75%, and the area under the ROC curve was 0.923. This study confirmed that RTE had high diagnostic value in the diagnosis of benign and malignant breast masses, especially when the specificity reached 100%. This is inconsistent with other published papers. Thomas *et al.* [16] reported that the sensitivity and specificity was 79.6% and 91.5% when evaluating 108 breast masses with RTE technology, respectively. Itoh *et al.* [17] also reported high sensitivity of 89.3% and specificity of 93.1% in the first and second stages for evaluating 111 masses. The reasons why the specificity reached 100% in this study were as follows: experience and skills; strictly complying with the elastic process, and strictly chosen cases [18-20]. The reasons why 12 cases were diagnosed incorrectly by RTE in this study were as follows. First, the fibrosis and calcifications in benign masses made the RTE score higher, while liquefaction and bleeding in malignant masses lowered the RTE score. Second, there was poor cooperation of patient breathlessness in the process of the actual data collection. Finally, the depth of the measurement and some unknown factors, such as the size of the mass.

SR evaluated the elasticity of suspected masses by calculating the average strain rate of suspected masses with that of adjacent gland or adipose tissues to obtain objective assessment values [21]. In this study, the SR values of 61 benign breast masses ranged from 1.06-6.41, and the average value was 2.392. The SR values of 36 malignant breast masses were from 2.16-16.33, and the average value was 5.665. The average SR value of the malignant masses was higher than the benign masses ($t = -8.387, p < 0.001$). The best cut-off value (2.89 m/s) for diagnosing benign and malignant breast masses had the largest Youden index. The sensitivity was 83.6%, the specificity was 97.2%, the accuracy rate was 88.7%, the Youden index was 0.808, the positive predictive value was 98.1%, the negative predictive value was 97.2%, and the best cut-off point was 2.89. The results in this study were lower than the results reported by Parajuly *et al.* [22] who designated 3.54 as the best cut-off value with a sensitivity of 94.6% and a specificity of 94.3%. The reasons may be related to race and cases.

ARFI is generated by applying acoustic radiation force to form taps force towards targeted tissues [23-25]. The tissues driven by radiation forces may result in lengthwise and horizontal shifting. The propagation velocity (m/s) of the shear wave was tested by transverse displacement per unit time of tissue, which reflects the flexibility of the tissues. The faster the shear wave velocity propagation velocity, the harder the mass. This study measured the SWV values of the center and border masses to explore the best SRFI for diagnosing benign and malignant breast masses. The results

of center masses were as follows: the SWV values of 61 benign breast masses ranged from 1.33-9.00 m/s, the average value was 3.19 m/s, 36 SWV values of malignant breast masses ranged from 1.74-9.00 m/s, and the average was 8.46 m/s. The SWV values of malignant breast masses were higher than the benign masses, and the difference was statistically significant ($t = -13.311$, $p < 0.001$). Using 8.85 m/s as the best cut-off value, the sensitivity, specificity, and accuracy rate for diagnosing benign and malignant breast masses with the ARFI method were 98.4%, 88.9%, and 94.8%, respectively. The Youden index was 0.873, the positive predictive value was 93.8%, and the negative predictive value was 97.0%. The two kinds of ARFI methods in this study had high diagnostic efficiency, which was similar to previous reports [26-28]. The misdiagnosis was caused by fibroadenomas, which were related to the hyperplasia of mesenchymal and glandular epithelial cells. The texture was usually soft when it was rich in mucopolysaccharides. The thick calcification foci, collagen, and hyaline degeneration internally would make the tissues hard, which could increase the RTE score and the Vm of SWV to cause false-positive results. If the IDC volume was relatively large and the disease course was relatively long, hemorrhage and necrosis would result to smaller RTE scores and the Vm of SWV, which would lead to misdiagnosis. The diagnostic accuracy would be affected by the low quality of elastography if the masses were too large, the locations were too shallow or too deep, lacking the control of surrounding normal gland tissue.

Some limitations existed in this study. First, the authors did not evaluate the inter- and intra-observer variability in data interpretation. Second, the number of cases is relatively small, especially for the breast cancer with special pathology. Large sample multicenter studies should be carried out in order to get better cut-off values and better diagnostic instruments.

Conclusions

To sum up, RTE, SR, the internal SWV values, and the marginal SWV values all have higher diagnostic values in diagnosing benign or malignant breast masses. The area under the ROC curve was > 0.9 . No significant difference occurred between any two models of the three elastic technologies in diagnostic efficiency.

References

- [1] Kamangar F., Dores G.M., Anderson W.F.: "Patterns of cancer incidence, mortality, and prevalence across five continents: defining priorities to reduce cancer disparities in different geographic regions of the world". *J. Clin. Oncol.*, 2006, 24, 2137.
- [2] Bai M., Du L., Gu J., Li F., Jia X.: "Virtual touch tissue quantification using acoustic radiation force impulse technology: initial clinical experience with solid breast masses". *J. Ultrasound Med.*, 2012, 31, 289.
- [3] Reinikainen H., Rissanen T., Päivänsalo M., Pääkkö E., Jauhiainen J.: "Power Doppler and contrast-enhanced power Doppler ultrasonography in the diagnosis of breast tumors". *Acta Radiol.*, 2001, 42, 106.
- [4] Athanasiou A., Tardivon A., Tanter M.: "Breast lesions: quantitative elastography with supersonic shear imaging—preliminary results". *Radiology*, 2010, 256, 297.
- [5] Corsetti V., Ferrari A., Ghirardi M.: "Role of ultrasonography in detecting mammographically occult breast carcinoma in women with dense breasts". *Radiol. Med.*, 2006, 111, 440.
- [6] Grajo J R., Barr R. G.: "Strain elastography for prediction of breast cancer tumor grades". *J. Ultrasound Med.*, 2014, 33, 129.
- [7] Kim Y.S., Park J.G., Kim B.S., Lee C.H., Ryu D.W.: "Diagnostic value of elastography using acoustic radiation force impulse imaging and strain ratio for breast tumors". *J. Breast Cancer*, 2014, 17, 76.
- [8] Raza S., Odulate A., Ong E.M., Chikarmane S., Harston C.W.: "Using real-time tissue elastography for breast lesion evaluation our initial experience". *J. Ultrasound Med.*, 2010, 29, 551.
- [9] Hooley R.J., Scoutt L.M., Philpotts L.E.: "Breast ultrasonography: state of the art". *Radiology*, 2013, 268, 642.
- [10] Goddi A., Bonardi M., Alessi S.: "Breast elastography: a literature review". *J. Ultrasound*, 2012, 15, 192.
- [11] Tozaki M., Isobe S., Yamaguchi M.: "Ultrasonographic elastography of the breast using acoustic radiation force impulse technology: preliminary study". *Jpn. J. Radiol.*, 2011, 29, 52.
- [12] Chang J.M., Won J.K., Lee K.B., Park I.A., Yi A.: "Comparison of shear-wave and strain ultrasound elastography in the differentiation of benign and malignant breast lesions". *AJR. Am. J. Roentgenol.*, 2013, 201, W347.
- [13] Tozaki M., Isobe S., Fukuma E.: "Preliminary study of ultrasonographic tissue quantification of the breast using the acoustic radiation force impulse (ARFI) technology". *Eur. J. Radiol.*, 2011, 80, e182.
- [14] Duma M.M., Chiorean A.R., Chiorean M.: "Breast Diagnosis: Concordance Analysis Between the BI-RADS Classification and Tsukuba Sonoelastography Score". *Chujul. Med.*, 2014, 87, 250.
- [15] Navarro B., Ubeda B., Vallespi M., Wolf C., Casas L., Browne J.L.: "Role of elastography in the assessment of breast lesions: preliminary results." *J. Ultrasound. Med.*, 2011, 30, 313.
- [16] Thomas A., Fischer T., Frey H.: "Real-time elastography - an advanced method of ultrasound: first results in 108 patients with breast lesions". *Ultrasound. Obstet. Gynecol.*, 2006, 28, 335.
- [17] Itoh A., Ueno E., Tohno E.: "Breast disease: clinical application of US elastography for diagnosis". *Radiology*, 2006, 239, 341.
- [18] Barr R.G.: "Sonographic breast elastography: a primer". *J. Ultrasound Med.*, 2012, 31, 773.
- [19] Barr R.G., Zhang Z.: "Effects of precompression on elasticity imaging of the breast development of a clinically useful semiquantitative method of precompression assessment". *J. Ultrasound. Med.*, 2012, 31, 895.
- [20] Yoon J.H., Kim M.H., Kim E.K., Moon H.J., Kwak J.Y.: "Interobserver variability of ultrasound elastography: how it affects the diagnosis of breast lesion". *AJR. Am. J. Roentgenol.*, 2011, 196, 730.
- [21] Athanasiou A., Tardivon A., Tanter M.: "Breast lesions: quantitative elastography with supersonic shear imaging—preliminary results". *Radiology*, 2010, 256, 297.
- [22] Parajuly S.S., Lan P.Y., Yun M.B., Gang Y.Z., Hua Z.: "Diagnostic potential of strain ratio measurement and a 5 point scoring method for detection of breast cancer: Chinese experience". *Asian. Pac. J. Cancer Prev.*, 2012, 13, 1447.
- [23] Jin Z.Q., Li X.R., Zhou H.L.: "Acoustic radiation force impulse elastography of breast imaging reporting and data system category 4 breast lesions". *Clin. Breast Cancer*, 2012, 12, 420.
- [24] Kumm T.R., Szabunio M.M.: "Elastography for the characterization of breast lesions: initial clinical experience". *Cancer Control*, 2010, 17, 156.
- [25] Nightingale K., Soo M.S., Nightingale R., Trahey G.: "Acoustic radiation force impulse imaging: in vivo demonstration of clinical fea-

- sibility". *Ultrasound. Med. Biol.*, 2002, 28, 227.
- [26] Tozaki M., Isobe S., Sakamoto M.: "Combination of elastography and tissue quantification using the acoustic radiation force impulse (ARFI) technology for differential diagnosis of breast masses". *Jpn. J. Radiol.*, 2012, 30, 659.
- [27] Meng W., Zhang G., Wu C., Wu G., Song Y.: "Preliminary results of acoustic radiation force impulse (ARFI) ultrasound imaging of breast lesions". *Ultrasound. Med. Biol.*, 2011, 37, 1436.
- [28] Teke M., Göya C., Teke F.: "Combination of Virtual Touch Tissue Imaging and Virtual Touch Tissue Quantification for Differential Diagnosis of Breast Lesions". *J. Ultrasound. Med.*, 2015, 34, 1201.

Corresponding Author:

JUN LI, M.D.

Department of Function, The First Affiliated Hospital
of Medical College of Shihezi University,
North Two Road, 32 District
Shihezi, Xinjiang 832008 (China)
e-mail: guilinlu0031@126.com