

# Effect of low molecular weight heparin on autotransplantation efficacy of ovarian tissues in rats

T. Toporcer<sup>1</sup>, T. Grendel<sup>2</sup>, I. Uhrinová<sup>3</sup>, S. F. Iannaccone<sup>4</sup>, A. Grendelová<sup>5</sup>, F. Sabol<sup>1</sup>, J. Belák<sup>6</sup>, S. Toporcerová<sup>7</sup>

<sup>1</sup>Department of Heart Surgery, <sup>2</sup>Department of Anaesthesiology and Intensive Medicine, Medical faculty, Pavol Jozef Šafarik University and Eastern Slovak Institute for Cardiovascular Diseases Ltd., Košice

<sup>3</sup>GynCare Centre of Assisted Reproduction, Košice

<sup>4</sup>Department of Forensic Medicine, Medical Faculty, Pavol Jozef Šafarik University, Košice

<sup>5</sup>Department of Gynaecology and Obstetrics, Medical Faculty, Pavol Jozef Šafarik University and 1st private Hospital Košice-Šaca Ltd., Košice

<sup>6</sup>Second Department of Surgery, Medical Faculty, Pavol Jozef Šafarik University and Louis Pasteur University Hospital, Košice

<sup>7</sup>Department of Gynaecology and Obstetrics, Medical Faculty, Pavol Jozef Šafarik University and Louis Pasteur University Hospital, Košice and GynCare - Centre of Assisted Reproduction, Košice (Slovakia)

## Summary

**Background:** One of the most important problems of ovarian transplantation is the significant reduction in the number of primordial follicles during the short period after transplantation due to post-transplantation ischemia. The aim of the work was to evaluate the effect of enoxaparin application on follicular survival after cryopreserved and fresh ovary transplantation in rats. **Materials and Methods:** The study used female Sprague Dawley rats (n=56). The animals were ovariectomized and the healing of fresh and cryopreserved ovarian tissue was evaluated. Estrogen blood level, percentage of ovarian live tissue, and angiogenesis were evaluated 16 days after transplantation of fresh ovary and 7, 14, and 28 days after transplantation of cryopreserved ovarian tissue. The animals in the experimental groups were treated after transplantation by enoxaparin subcutaneously in doses of 200 IU/kg per day. **Results:** A statistically significant higher ( $p < 0.05$ ) percentage of live tissue was recorded in the treated group ( $14.5 \pm 6.5$  vs.  $20.6 \pm 5.7\%$  in control vs. treated groups) 7 days after transplantation of cryopreserved ovarian tissue, and a significantly more intensive ( $p < 0.005$ ) neoangiogenesis was recorded in the treated group ( $12.7 \pm 1.9$  capillaries in  $250 \mu\text{m}^2$ ) in comparison with the control group ( $7.4 \pm 2.1$  capillaries in  $250 \mu\text{m}^2$ ) 28 days after transplantation of cryopreserved ovarian tissue. **Conclusions:** Administration of enoxaparin after transplantation of cryopreserved ovarian tissue may temporarily improve tissue survival. The use of enoxaparin does not adversely affect neoangiogenesis around the transplanted ovary. The positive effect of low molecular weight heparin application on neoangiogenesis was demonstrated four weeks after transplantation.

**Key words:** Low molecular weight heparin; Ovary autotransplantation; Cryopreservation; Angiogenesis.

## Introduction

Advances in the treatment of malignant diseases has led to a significant increase of life expectancy in cancer patients, especially in young ones. Therefore, one direction of contemporary medicine is focused on improving the quality of life of patients who have undergone cancer treatment. Because women are born with an irreplaceable supply of germ cells in their ovaries, cytotoxic damage to ovarian stromal and germ cells leads to unavoidable effects on ovarian function, resulting in female infertility [1]. Due to the increasing number of young women delaying childbearing to later life for various reasons, and to the growing number of women experiencing cancer before completing childbearing, preservation of fertility for patients undergoing chemotherapy has become a significant part of reproductive medicine [2]. There are several options currently available for preserving fertility in young cancer patients, such as cryopreservation of embryos and oocytes. How-

ever, cryopreservation of ovarian tissue is the only option available for prepubescent girls and women in need of immediate chemotherapy [3].

Experimental cryopreservation and transplantation of ovarian tissue has a long history, beginning in the 1960s. The first successful cryopreservation and transplantation of ovary in mice dates back to 1960, and the first successful mouse birth after this procedure dates to 1997 [4]. It was further demonstrated that mice have a normal reproductive lifespan after autografts of fresh tissue. Some papers in the 1990s showed that frozen ovarian tissue could be successfully thawed and autotransplanted in both mice and sheep, leading to normal ovarian function and live births. The first live birth from fresh human ovarian tissue transplantation between identical twins destined for premature ovarian failure was reported in 2004 [4]. Ladanyi *et al.* presented that ovarian tissue auto-transplantation is capable of restoring fertility, with over 80 live births reported with a corresponding pregnancy rate of 23% to 37% [5]. Despite those

Revised manuscript accepted for publication January 11, 2018.

80 live human births after ovarian tissue cryopreservation and transplantation, it is still an experimental method with many potential modifications to improve the method's success. If the whole ovary is cryopreserved and transplanted with pedicle and vessel anastomosis, low follicle survival (0.019-0.3%) is present, and to date, no auto-transplantation of frozen-thawed human whole ovary has resulted in a live birth [5, 6]. On the other hand, if small pieces of tissue are used, animal experiments have shown that 87% of primordial follicles survive with normal ultrastructure following vitrification, and there is no statistical difference between fresh and cryopreserved ovarian graft tissue survival five to ten months after transplantation (55.1% vs. 59.5%) [7, 8]. During the short period after transplantation, half of all primordial follicles are lost, persisting only three days after surgery until the stage of neoangiogenesis [9]. The work of the Damasio *et al.* favours heterotopic transplantation due to the lower apoptosis rate in comparison to the orthotopic position [10]. The next question of the authors is where the most favourable anatomical layout for the transplanted ovary lies. The literature presents many possible places for heterotopic ovarian transplantation with similar results, including the renal capsule, the retroperitoneum, granulation tissue and various muscles, including dorsal lumbar muscle [3, 8, 9, 11-13].

Low molecular weight heparin (LMWH) is a mixture of sulfated glycosaminoglycans with a molecular weight in the range of 3 to 10 kDa [14]. Heparin and LMWH are mostly known for their anticoagulant properties. Aside from these anticoagulant effects, several studies have shown that LMWH possesses various anti-inflammatory, immunomodulatory effects, as well as effects on chronic inflammatory diseases of bowel and lungs, wound healing, and angiogenesis [15, 16]. Several authors have presented a negative effect of LMWH on angiogenesis [17-19]. On the other hand, the results of more works have shown a positive effect on wound healing and angiogenesis by LMWH application [20, 21].

The aim of the work was to evaluate the effect of enoxaparin application on follicular survival after transplantation of cryopreserved and fresh ovarian tissue in rats.

## Materials and Methods

The experimental conditions were in compliance with the requirements of European rules of ethical standards of animal treatment and welfare. Hence, this experiment was approved by the Ethics Committee of the Faculty of Medicine of Pavol Jozef Šafárik University in Košice and by the State Veterinary and Food Administration of the Slovak Republic, no. Ro-982/15-221.

Female Sprague Dawley rats ( $n=56$ ), six months of age, were used in the study. These were randomly divided into eight groups of seven animals: (1) control, not frozen, evaluated 16 days after transplantation (C-NF-16), (2) treated, not frozen, evaluated 16 days after transplantation (T-NF-16), (3) control, cryopreserved, evaluated seven days after transplantation (C-F-7), (4) control, cryopreserved, evaluated 14 days after transplantation (C-F-14),

(5) control, cryopreserved, evaluated 28 days after transplantation (C-F-28), (6) treated, cryopreserved, evaluated seven days after transplantation (T-F-7), (7) treated, cryopreserved, evaluated 14 days after transplantation (T-F-14), and (8) treated, cryopreserved, evaluated 28 days after transplantation (T-F-28).

Every surgery was performed under inhalation anaesthesia (semi-closed circuit) with isoflurane. Tramadol was injected intramuscularly in all rats in doses of 0.5 mg/kg. Atropine was administered subcutaneously as premedication in a dose of 0.05 mg/kg. In all groups, both ovaries were surgically removed. After the fat was removed, each ovary was cut into small pieces of size  $1 \times 1 \times 1$  mm in HEPES-buffered tissue culture medium 199. In groups C-NF-16 and T-NF-16 autotransplantation of the ovarian blocks was performed immediately under the same anaesthesia for the same rat. In groups C-F-7, C-F-14, C-F-28, T-F-7, T-F-14, and T-F-28 ovarian blocks were cryopreserved for two months and then thawed and autotransplanted into the same rat. Bilateral incisions on the rat dorsum were performed. Blocks of the ovary were implanted under the fascia of the dorsal lumbar muscle, and the fascia and skin were sutured. In groups T-NF-16, T-F-7, T-F-14, and T-F-28 the animals were treated by enoxaparin subcutaneously in a dose of 200 IU/kg every 24 hours. In groups C-NF-16, C-F-7, C-F-14, and C-F-28 a saline solution was applied subcutaneously every 24 hours. In groups C-F-7 and T-F-7 euthanasia of the animal was performed seven days after transplantation. In groups C-F-14 and T-F-14 euthanasia of the animal was performed 14 days after transplantation. In groups C-NF-16 and T-NF-16 euthanasia of the animal was performed 16 days after transplantation, and in groups C-F-28 and T-F-28 euthanasia of the animal was performed 28 days after transplantation. At the time of euthanasia, blood and tissue from the dorsal lumbar muscle, including the ovarian blocks, were collected from all animals.

The recovered ovaries were transported immediately in a cell culture dish containing 2 mL of HEPES medium to the laboratory, where the ovarian cortex was processed at room temperature (25 °C) and cut into small sections (between  $1 \times 1 \times 1$  mm in size).

The ovarian cortical sections were transferred into cell culture dishes in a stepwise manner, with a solution containing 10% v/v ethylene glycol and 10% v/v dimethyl sulfoxide (DMSO) in HEPES for 20 minutes at room temperature. They were then transferred into a solution containing 17% v/v ethylene glycol, 17% v/v DMSO, and 0.75 M sucrose in HEPES for three minutes at room temperature.

The ovarian cortical sections were then loaded individually with minimal vitrification solution to the surface of 0.25 ml cryostraws cut angle-wise. The straws were inserted into larger precooled 0.5 ml cryostraws, sealed with an ultrasound sealer and stored in liquid nitrogen (-196°C).

Prior to reimplantation, the straws containing the samples were removed from liquid nitrogen storage. The contents of the straws were exposed to room temperature for one minute. Then each ovarian cortical section sample was expelled into a cell culture dish and submitted to three five-minute baths in a solution containing HEPES medium + 10% human serum albumin (HSA), and decreasing concentrations of sucrose (0.5, 0.25, and 0.0 M) at room temperature. These steps are done to wash out the cryoprotectants.

Blood was collected from all animals immediately before euthanasia. Serum was prepared and kept frozen at -20°C until determination of the serum hormone concentrations. Serum estradiol concentrations were measured using a chemiluminescent microparticle immunoassay (CMIA) for the quantitative determination of estradiol.

The ovarian tissue specimens from both sides of the dorsal mus-

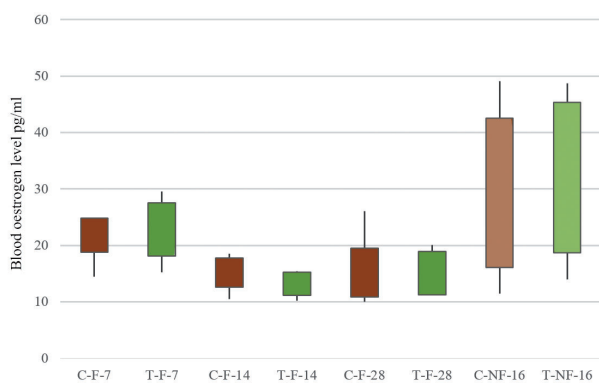


Figure 1. — Blood estrogen level in the groups.

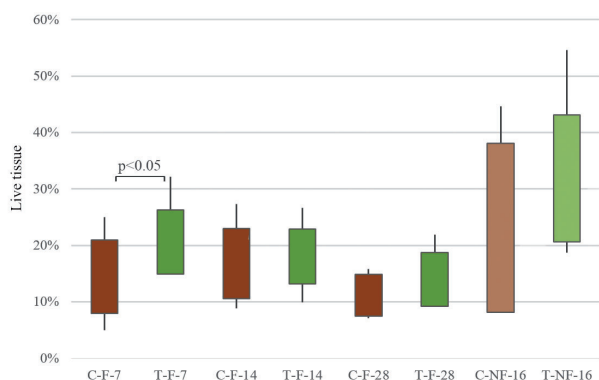


Figure 2. — Percentage of live ovarian tissue in the groups.

cle were processed routinely for light microscopy (fixation, dehydration, embedding, cutting, and staining with hematoxylin-eosin, immunohistology for Factor VIII and CD34).

The following histological structures and changes were evaluated: angiogenesis and percentage of live tissue. Angiogenesis was evaluated as number of capillaries in  $250 \mu\text{m}^2$  of live tissue of ovary. The percentage of live tissue was calculated as the ratio of live to all ovary tissue.

Data on the estrogen blood level, angiogenesis, and percentage of live tissue are presented as the mean  $\pm$  standard deviation. Analysis of variance followed by Tukey-Kramer multiple comparison tests were used to compare the differences in hormone serum levels and percentage of live tissue. The Kruskal-Wallis test was used to compare the data obtained from the angiogenesis measurement. For each test, significance was accepted at  $p < 0.05$ .

## Results

No statistically significant difference was recorded in the results of the fresh ovarian tissue transplantation groups 16 days after transplantation. Estrogen blood level was  $29.3 \pm 13.2$  pg/ml in the non-treated group (C-NF-16) and  $32.1 \pm 13.3$  pg/ml in the treated group (T-NF-16) (Figure 1). The percentage of the live tissue in the fresh transplanted ovary was  $23.1 \pm 14.9\%$  in control group (C-NF-16) and  $31.9 \pm$

Table 1. — Blood estrogen level, percentage of live tissue, and angiogenesis in the fresh transplanted groups (C-NF-16 and T-NF-16).

	Control group	Treated group
Blood estrogen level (pg/ml)		
16 days after TX	$29.3 \pm 13.2$	$32.1 \pm 13.3$
Live tissue (%)		
16 days after TX	$23.1 \pm 14.9$	$31.9 \pm 11.3$
Angiogenesis (number of capillaries in $250 \mu\text{m}^2$ )		
16 days after TX	$4.9 \pm 1.5$	$6.4 \pm 2.1$

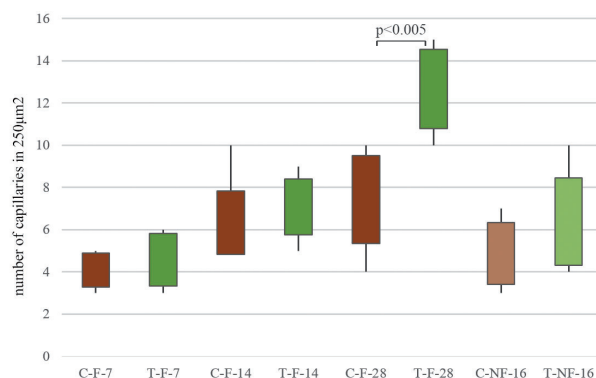


Figure 3. — Number of capillaries in  $250 \mu\text{m}^2$  in the groups.

11.3% in the treated group (T-NF-16) (Figure 2). In the control group (C-NF-16)  $4.9 \pm 1.5$  capillaries were recorded in  $250 \mu\text{m}^2$  and in the treated group (T-NF-16)  $6.4 \pm 2.1$  (Figure 3, Table 1).

In the comparison of cryopreserved ovarian tissue groups, the following results were recorded: Estrogen blood level in the control groups was  $21.7 \pm 3$  pg/ml seven days after transplantation (C-F-7),  $15.2 \pm 2.6$  pg/ml 14 days after transplantations (C-F-14), and  $15.2 \pm 4.3$  pg/ml 28 days after ovary transplantation (C-F-28). Estrogen blood level in the enoxaparin treated groups was  $22.8 \pm 4.7$  pg/ml seven days after transplantation (T-F-7),  $12.3 \pm 2$  pg/ml 14 days after transplantations (T-F-14), and  $15.1 \pm 3.8$  pg/ml 28 days after ovary transplantation (T-F-28). No statistically significant differences were recorded between the treated and control groups at the same time after transplantation (Figure 1, Table 2).

A statistically significant difference was recorded in the percentage of live ovarian tissue evaluation seven days after transplantation in the cryopreserved groups. The authors recorded  $14.5 \pm 6.5\%$  live tissue in group C-F-7 and  $20.6 \pm 5.7\%$  live tissue in group T-F-7 ( $p < 0.05$ ) (Figures 2 and 4, Table 2). Next, the authors recorded  $16.8 \pm 6.2\%$  live tissue in group C-F-14,  $18.6 \pm 4.8\%$  live tissue in group T-F-14,  $11.2 \pm 3.7\%$  live tissue in group C-F-28, and  $14.0 \pm 4.8\%$  live tissue in group T-F-28, with no statistically significant differences between the treated and control groups at the same time after transplantation (Figure 2, Table 2).

Table 2. — Blood estrogen level, percentage of live tissue, and angiogenesis in cryopreserved transplanted groups (C-F-7, C-F-14, C-F-28, T-F-7, T-F-14, and T-F-28) (\*- $p < 0.05$ , \*\*- $p < 0.005$ )

	Control group	Treated group
Blood estrogen level (pg/ml)		
7 days after TX	21.8 ± 3.0	22.8 ± 4.7
14 days after TX	15.2 ± 2.6	13.2 ± 2.0
28 days after TX	15.2 ± 4.3	15.1 ± 3.8
Live tissue (%)		
7 days after TX	14.5 ± 6.5	20.6 ± 5.7*
14 days after TX	16.8 ± 6.2	18.0 ± 4.8
28 days after TX	11.2 ± 3.7	14.0 ± 4.8
Angiogenesis (number of capillaries in 250 $\mu\text{m}^2$ )		
7 days after TX	4.1 ± 0.8	4.6 ± 1.2
14 days after TX	6.3 ± 1.5	7.1 ± 1.3
28 days after TX	7.4 ± 2.1	12.7 ± 1.9**

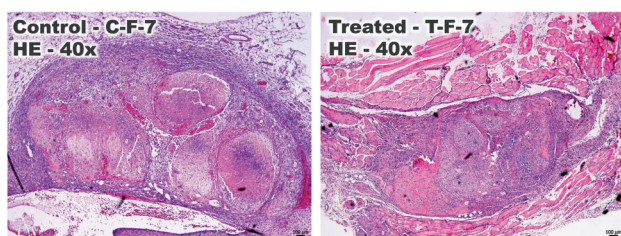


Figure 4. — Histological picture of transplanted cryopreserved ovarian tissue in group C-F-7 and T-F-7 7 days after transplantation (coloured by haematoxylin eosin).

Evaluation of angiogenesis showed  $4.1 \pm 0.8$  (C-F-7) and  $4.6 \pm 1.2$  (T-F-7) capillaries in  $250 \mu\text{m}^2$  in the control and treated group seven days after transplantation and  $6.3 \pm 1.5$  (C-F-14) and  $7.1 \pm 1.3$  (T-F-14) capillaries in  $250 \mu\text{m}^2$  in the control and treated group 14 days after transplantation, without statistically significant differences (Figure 3, Table 2). A statistically significant difference ( $p < 0.005$ ) in the number of capillaries in  $250 \mu\text{m}^2$  ( $7.4 \pm 2.1$  vs.  $12.7 \pm 1.9$  in C-F-28 and T-F-28) was recorded between the control group and treated group 28 days after transplantation (Figures 3 and 5, Table 2).

## Discussion

The results of published papers have indicated that the survival and development of different follicular types are significantly influenced by ischemia [13]. Neovascularization of heterotopic transplanted ovarian tissue could be observed as early as two days after transplantation in rats and three days in mice [8, 22]. Thus, investigation of neoangiogenesis is possible and usable as early as three days after transplantation [12]. Many studies have focused on the effect of post-transplant ischemia and the damage to transplanted tissue during the short period after ovary transplantation. Tavana *et al.* showed that hyaluronic acid

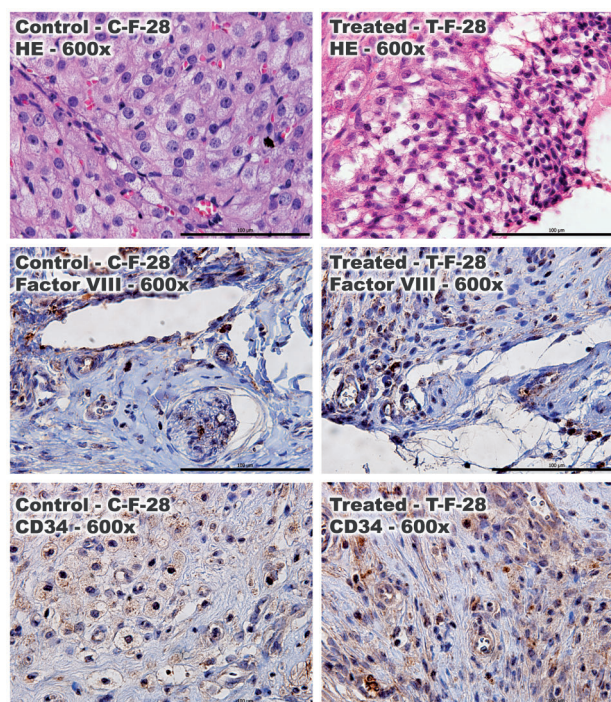


Figure 5. — Histological picture of neoangiogenesis in group C-F-28 and T-F-28 28 days after transplantation (coloured by haematoxylin eosin, factor 8 antibody, and CD34 antibody).

containing vascular endothelial growth factor (VEGF) and basic fibroblast growth factor (bFGF) can ensure follicular survival, decrease apoptosis, and recover ovarian function after auto-transplantation [23]. On the other hand, a subsequent work presented that ovarian encapsulation with hyaluronic acid-based hydrogel alone (without VEGF and bFGF) can prevent or minimize ischemia-induced follicle loss, preserve the follicular pool, promote follicular survival, facilitate angiogenesis, and restore hormone levels [12]. Other authors did not find a positive effect of hyaluronic acid hydrogel on follicular preservation after transplantation [11]. Zhou *et al.* presented that pretreatment with gonadotropin-releasing hormone analogues (GnRHa) before ovariectomy can effectively increase the follicle fraction with normal morphology, without a negative effect on physiological recovery of the grafted follicular tissue, and may increase the subsequent successful rate of transplantation [24]. Amorin *et al.* presented that in autologous ovarian transplantation, a high dose of N-acetylcysteine through removing reacting oxygen species, improving the action of nitric oxide and acting on the regulation of microcirculation promotes graft viability with recovery of the estrous cycle [9]. Tamadon *et al.* focused their study on superovulation after ovarian transplantation. The authors presented that secondary follicles can survive after autologous transplantation, but their reservoir gradually became diminished after transplantation. On the other hand, the number of tertiary follicles increases over time after transplantation.

Changes in the ovary are caused by tissue ischemia after transplantation [13]. Hayashi *et al.* presented hyperbaric oxygen therapy as a successful method for improving oxygenation and subsequent survival of the ovary after transplantation [3].

Several authors have presented the serum level of oestrogen as a marker of ovarian function, and this parameter is used for confirmation of ovarian tissue survival after fresh or cryopreserved transplantation [8, 9, 22]. An elevation in the estrogen level is recorded five to ten days after transplantation and it remains elevated throughout the life of the ovarian tissue graft [8, 22]. On the other hand, in the literature, the estrogen level parameter is a parameter of ovary function, not a qualitative parameter of ovary tissue survival. Deng *et al.* presented the elevation of estrogen levels two years after ovarian transplantation in sheep and six to 12 months in rats [8]. The present authors suggest that the estrogen elevation lifetime could be a useful marker for evaluating ovary tissue survival. In contrast, a comparison of estrogen in the same time frame after transplantation does not show quantitative changes in the ovarian tissue. This correlates with the recording of no statistical differences in estrogen levels between the treated and control groups.

The present authors presumed that LMWH may affect transplantation, healing, and neoangiogenesis via several routes. A direct effect of T-cells with a decrease in several interleukins and TNF- $\alpha$  after enoxaparin application was recorded [25]. Decreases in tumor necrosis factor  $\alpha$  (TNF $\alpha$ ), interleukin (IL)-1 $\beta$ , IL-6, IL-8, and IL-10 were recorded after LMWH application. A decrease of TNF $\alpha$  and IL-1 $\beta$  can lead to upregulation of syndecain-1, with increasing levels of basic fibroblast growth factor (bFGF) and fibroblast growth factor receptor, and decreasing levels of matrixmetalloproteinase-7 (MMP-7). This complex effect of growth factors and inflammation cytokines improves wound-healing, stimulates keratinocyte proliferation, and can affect neoangiogenesis [14]. Zhang *et al.* presented a positive effect of ultra LMWH on cerebral ischemia/reperfusion injury. They presented significantly decreased lactic acid content, increased ATP-ase activity, neural apoptosis inhibition and decreased expression of intercellular adhesion molecule 1 (ICAM-1) and caspase-3 mRNA after ultra-LMWH application [26]. They also describe a positive effect of LMWH for myocardial infarction healing and reperfusion injury [16]. The positive effect of LMWH on reperfusion injury and decrease of apoptosis correlates with a significantly higher percentage of live ovarian tissue recorded seven days after cryopreserved transplantation ( $20.6 \pm 5.7\%$  in treated group vs.  $14.5 \pm 6.5\%$  in control group). On the other hand, according to recorded data, the positive effect did not persist two and four weeks after transplantation. In the group with fresh ovarian transplantation, no statistically significant difference was recorded in the live tissue percentage after LMWH treatment.

Li *et al.* presented that LMWHs lead to a decrease of VEGF, transforming growth factor  $\beta$ 1 (TGF- $\beta$ 1), and hypoxia inducible factor 1 $\alpha$  (HIF-1 $\alpha$ ) production. HIF-1 $\alpha$  is a critical transcription factor in hypoxic tissue, responsible for angiogenesis and extracellular matrix (ECM) deposition, and VEGF is a well-known growth factor that promotes neoangiogenesis [17]. Goertz *et al.* presented a negative effect of Tinzaparin on VEGF-A production and neoangiogenesis, but only a marginal antiangiogenic action of fondaparinux [18]. Debergh *et al.* also presented antiangiogenic effects of LMWH and microvessel normalization in tumor angiogenesis. The authors point to the downregulation of tissue factor (TF) gene expression and enhanced release of TF pathway inhibitor (TFPI). LMWH also decreases the release of heparinase, which leads to a decrease of heparin-bound growth factors (VEGF, bFGF) release. Heparin fragments shorter than 18 saccharide units interfere with the binding of VEGF to its cellular receptor, and LMWH of molecular weight 2.5-5 kDa maximally suppresses VEGF-induced angiogenesis. The authors summarize that the most effective anti-angiogenic impact is presented by LMWH of 3 to 6 kDa or >8 kDa [19]. The molecular weight of enoxaparin varies from 3 to 8 kDa, which also includes the window of the molecular weight with anti-angiogenic and pro-angiogenic effects [27].

The proliferative phase of wound healing is significantly dependent on angiogenesis. Durmaz *et al.* presented the positive effect of enoxaparin on skin wound healing in rats [20]. Norrby *et al.* also presented a positive affect of dalteparin on VEGF-mediated angiogenesis. They stated that 5-kD fraction of tinzaparin has been shown to inhibit VEGF-induced angiogenesis. The different molecular weight between the drugs is highlighted [21]. Takikawa *et al.* presented a positive affect of FGF-2 containing fragmin/protamine nanoparticles on the healing of crush syndrome by improved blood flow, increased number of blood vessels, and faster recovery of muscle tissue [28]. Other authors present a positive effect of enoxaparin on intestine anastomosis healing [29]. The present results did not suggest an angiogenesis effect by enoxaparin application seven and 14 days after ovarian tissue transplantation. However a significantly positive effect of enoxaparin four weeks after transplantation was recorded. On the other hand, no effect was recorded on live tissue percentage in this time window. The present authors expect that for the effectiveness on ovary tissue survival, a positive effect of LMWH on angiogenesis in the earlier period after transplantation is needed.

In Denmark, demographers are predicting that 25% of woman today will live to age 100 [30]. Thus, this significant portion of the population will live half of their lives with postmenopausal changes. A number of works have focused on the possibility of overcoming the adverse effects of postmenopausal biology [31, 32]. A new point of view on ovary transplantation also includes preserving not only

their chance of having a child, but also the possibility of preventing them from ever having to go through menopause [30].

## Conclusion

The results presented in this paper show that enoxaparin administration after transplantation of cryopreserved ovarian tissue may temporarily improve tissue survival. The most important finding is that the use of enoxaparin does not adversely affect neo-angiogenesis around the transplanted ovary, which the results of other works have previously implied. Furthermore, a positive effect on neoangiogenesis was demonstrated four weeks after ovarian tissue transplantation in rats treated with enoxaparin.

## Acknowledgment

The present article was supported in part by the Grant Agency of the Ministry of Education, Science, Research and Sport of the Slovak Republic (VEGA 1/0660/16).

## References

- [1] Imai A., Ichigo S., Matsunami K., Takagi H., Kawabata I.: "Ovarian function following targeted anti-angiogenic therapy with bevacizumab". *Mol. Clin. Oncol.*, 2017, 6, 807.
- [2] Taylan E., Oktay K.H.: "Current state and controversies in fertility preservation in women with breast cancer". *World J. Clin. Oncol.*, 2017, 8, 241.
- [3] Hayashi S., Asano T., Kakizaki R., Suzuki H.: "Beneficial effect of hyperbaric oxygen therapy on the follicular survival in the mouse ovary after transplantation". *J. Reprod. Dev.*, 2012, 58, 260.
- [4] Silber S.: "Ovarian tissue cryopreservation and transplantation: scientific implications". *J. Assist. Reprod. Genet.*, 2016, 33, 1595.
- [5] Ladanyi C., Mor A., Christianson M.S., Dhillon N., Segars J.H.: "Recent advances in the field of ovarian tissue cryopreservation and opportunities for research". *J. Assist. Reprod. Genet.*, 2017, 34, 709.
- [6] Torre A., Vertu-Ciolino D., Mazoyer C., Selva J., Lornage J., Salle B.: "Safeguarding Fertility With Whole Ovary Cryopreservation and Microvascular Transplantation: Higher Follicular Survival With Vitrification Than With Slow Freezing in a Ewe Model". *Transplantation*, 2016, 100, 1889.
- [7] Behringer R.: "Mouse ovary transplantation". *Cold Spring Harb. Protoc.*, 2017, 2017: pdb.prot094458. doi: 10.1101/pdb.prot094458.
- [8] Deng X., Zheng H., Yu X., Yu H., Zhang C., Chao L., et al.: "Cryopreserved ovarian tissues can maintain a long-term function after heterotopic autotransplantation in rat". *Reproduction*, 2009, 138, 519.
- [9] Amorim E.M., Damous L.L., Durando M.C., Saraiva M.V., Koike M.K., Montero E.F.: "N-acetylcysteine improves morphologic and functional aspects of ovarian grafts in rats". *Acta Cir. Bras.*, 2014, 29, 22.
- [10] Damasio L.C., Soares-Junior J.M., Iavelberg J., Maciel G.A., de Jesus Simoes M., Dos Santos Simões R., et al.: "Heterotopic ovarian transplantation results in less apoptosis than orthotopic transplantation in a minipig model". *J. Ovarian Res.*, 2016, 9, 14.
- [11] Taheri M.A., Valojerdi M.R., Ebrahimi B.: "Intramuscular Autotransplantation of Vitrified Rat Ovary Encapsulated with Hyaluronic Acid Hydrogel". *Biopreserv. Biobank*, 2016, 14, 114.
- [12] Tavana S., Azarnia M., Valojerdi M.R., Shahverdi A.: "Hyaluronic acid-based hydrogel scaffold without angiogenic growth factors enhances ovarian tissue function after autotransplantation in rats". *Bio-med. Mater.*, 2016, 11, 055006.
- [13] Tamadon A., Raayat Jahromi A., Rahmanifar F., Ayaseh M., Koochi-Hosseinabadi O., Moghiminasr R.: "Histomorphometric Evaluation of Superovulation Effect on Follicular Development after Autologous Ovarian Transplantation in Mice". *Vet. Med. Int.*, 2015, 2015, 236436.
- [14] Wang X.F., Li A.M., Li J., Lin S.Y., Chen C.D., Zhou Y.L., et al.: "Low molecular weight heparin relieves experimental colitis in mice by downregulating IL-1beta and inhibiting syndecan-1 shedding in the intestinal mucosa". *PLoS One*, 2013, 8, e66397.
- [15] Mousavi S., Moradi M., Khorshidahmad T., Motamedi M.: "Anti-Inflammatory Effects of Heparin and Its Derivatives: A Systematic Review". *Adv. Pharmacol. Sci.*, 2015, 2015, 507151.
- [16] Cassinelli G., Naggi A.: "Old and new applications of non-anticoagulant heparin". *Int J Cardiol.*, 2016, 212, S14.
- [17] Li J., Guo Z.Y., Gao X.H., Bian Q., Jia M., Lai X.L., et al.: "Low molecular weight heparin (LMWH) improves peritoneal function and inhibits peritoneal fibrosis possibly through suppression of HIF-1alpha, VEGF and TGF-beta1". *PLoS One*, 2015, 10, e0118481.
- [18] Goertz L., Schneider S.W., Desch A., Mayer F.T., Koett J., Nowak K., et al.: "Heparins that block VEGF-A-mediated von Willebrand factor fiber generation are potent inhibitors of hematogenous but not lymphatic metastasis". *Oncotarget*, 2016, 7, 68527.
- [19] Debergh I., Van Damme N., Pattyn P., Peeters M., Ceelen W.P.: "The low-molecular-weight heparin, nadroparin, inhibits tumour angiogenesis in a rodent dorsal skinfold chamber model". *Br. J. Cancer*, 2010, 102, 837.
- [20] Durmaz C.E., Ozkan A., Senel B., Uyar H.A.: "Comparison of effects of unfractionated heparin and low molecular weight heparin on skin wound healing of rats". *Acta Cir. Bras.*, 2012, 27, 639.
- [21] Norrby K., Nordenhem A.: "Dalteparin, a low-molecular-weight heparin, promotes angiogenesis mediated by heparin-binding VEGF-A in vivo". *APMIS*, 2010, 118, 949.
- [22] Le A.H., Bonachea L.A., and Cargill S.L.: "Meloxicam and buprenorphine treatment after ovarian transplantation does not affect estrous cyclicity and follicular integrity in aged CBA/J mice". *PLoS One*, 2014, 9, e106013.
- [23] Tavana S., Valojerdi M.R., Azarnia M., Shahverdi A.: "Restoration of ovarian tissue function and estrous cycle in rat after autotransplantation using hyaluronic acid hydrogel scaffold containing VEGF and bFGF". *Growth Factors*, 2016, 34, 97.
- [24] Zhou X., He W., Zhu R., and Zheng Y.: "Impact of GnRHa pretreatment on the autotransplantation efficacy of cryopreserved rat ovarian tissue". *Biomed. Pharmacother.*, 2017, 86, 136.
- [25] Shastri M.D., Stewart N., Horne J., Zaidi S.T., Sohail S.S., Peterson G.M., et al.: "Non-Anticoagulant Fractions of Enoxaparin Suppress Inflammatory Cytokine Release from Peripheral Blood Mononuclear Cells of Allergic Asthmatic Individuals". *PLoS One*, 2015, 10, e0128803.
- [26] Zhang Z.G., Sun X., Zhang Q.Z., Yang H.: "Neuroprotective effects of ultra-low-molecular-weight heparin on cerebral ischemia/reperfusion injury in rats: involvement of apoptosis, inflammatory reaction and energy metabolism". *Int. J. Mol. Sci.*, 2013, 14, 1932.
- [27] Toporcer T., Lakyova L., Radonak J.: "Low molecular weight heparins and their non-antithrombotic effects on wound healing". *Cas Lek Cesk.*, 2009, 148, 481.
- [28] Takikawa M., Nakamura S., Ishihara M., Takabayashi Y., Fujita M., Hattori H., et al.: "Improved angiogenesis and healing in crush syndrome by fibroblast growth factor-2-containing low-molecular-weight heparin (Fragmin)/protamine nanoparticles". *J. Surg. Res.*, 2015, 196, 247.
- [29] Ergul E., Ozgun Y.M., Kiyak G., Barit Ozgun G., Korukluoglu B., Kudemir A.: "Does low molecular weight heparin impair anastomotic wound healing?" *J. Gastrointest. Surg.*, 2009, 13, 798.
- [30] Silber S.J.: "Ovary cryopreservation and transplantation for fertility preservation". *Mol. Hum. Rep.*, 2012, 18, 59.
- [31] Gal P., Toporcer T., Vidinsky B., Mokry M., Grendel T., Novotný

M., *et al.*: "Postsurgical administration of estradiol benzoate decreases tensile strength of healing skin wounds in ovariectomized rats". *J. Surg. Res.*, 2008, 147, 117.

- [32] Novotny M., Vasilenko T., Varinska L., Smetana K. Jr., Szabo P., Sarisky M., *et al.*: "ER-alpha agonist induces conversion of fibroblasts into myofibroblasts, while ER-beta agonist increases ECM production and wound tensile strength of healing skin wounds in ovariectomised rats". *Exp. Dermatol.*, 2011, 20, 703.

Corresponding Author:  
S. TOPORCEROVA PHD., MBA  
Department of Gynaecology and Obstetrics  
Louis Pasteur University Hospital  
Tr. SNP 1, Kosice 04001 (Slovakia)  
e-mail: s.toporcerova@gmail.com