

# Cesarean scar ectopic pregnancy, a life threatening condition: a case report

M. Meléndez Zalduegui<sup>1</sup>, S. Iglesias Ferreiro<sup>1</sup>, A. Rodríguez Vélez<sup>1</sup>, ML. Monje Beltrán<sup>1</sup>,  
EM. Vicedo Madrazo<sup>1</sup>, RJ. Martínez Portillo<sup>2</sup>, M. Llobet Roma<sup>3</sup>, M. Marqueta Sánchez<sup>1</sup>

<sup>1</sup>Department of Gynecology and Obstetrics, Hospital de Palamós, Girona; <sup>2</sup>Hospital Clinic, Barcelona

<sup>3</sup>Department of Pathology, Hospital de Palamós, Girona (Spain)

## Summary

A cesarean scar ectopic pregnancy (CSEP) is a rare and life-threatening condition with a prevalence of one over 3,000 pregnancies. If not promptly diagnosed, patients may undergo fatal results. There is no consensus for the management of this type of ectopic pregnancy. The authors present a series of three cases involving different clinical scenarios for the management of cesarean ectopic pregnancy. The diagnosis was made using laboratory results, ultrasound images, and surgery. Treatment was performed using different techniques according to this hospital's capabilities; from surgery to methotrexate use, all with satisfactory results. The authors discuss the clinical significance and differential diagnosis of CSEP in the setting of a second level reference hospital.

**Key words:** Cesarean scar; Ectopic pregnancy; Methotrexate; Hysterectomy; Cesarean scar ectopic pregnancy.

## Introduction

A cesarean scar ectopic pregnancy (CSEP) is a rare and dangerous condition that occurs when the blastocyst implantation abnormally locates between the myometrium and the fibrous scar tissue of a cesarean section (c-section) [1, 2]. CSEP Prevalence is estimated as one in 1,800 to one in 3,000 of all pregnancies, with a rate of 0.15% in women with a previous c-section and a rate of 6.1% of all ectopic pregnancies in women who had at least one cesarean delivery [3, 4].

C-section is the most common myometrial defect but not the only one; uterine scars have also been reported after other surgeries such as dilation and curettage, myomec-tomy, hysteroscopy, and even manual removal of the placenta.

Early diagnosis and clinical suspicious are important to avoid massive hemorrhages, uterine rupture, disseminated intravascular coagulation, and even death because CSEP is often misdiagnosed or confused with cervical pregnancy or abortion. No universal treatments exist for this pathology; nevertheless, the goal is to prevent maternal complications and to preserve fertility. [2, 5, 6]

Historically, ectopic pregnancy treatment was limited to surgery, being either hysterectomy, excision of the pregnancy located in the scarred uterus or dilation and curet-tage. Nowadays, the use of systemic methotrexate is a conservative option in selected cases and treatments like uterine artery embolization or endoscopic CSEP removal in combination, even along with the administration of

methotrexate, are becoming fruitful and widespread [7].

In this article, three clinical cases that occurred in this obstetrics department are presented; diagnosis and treat-ment were accomplished with available resources in a sec-ondary hospital.

## Cases Report

### Case 1

A 32-year-old woman with a previous c-section came to this emergency service after a massive bleeding at home. The patient had undergone dilation and curettage six weeks prior as treatment for a spontaneous abortion located in the uterine isthmus portion;

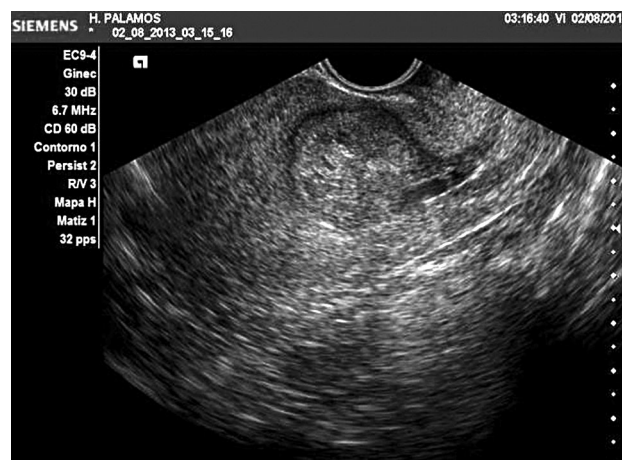

Figure 1. — Ultrasound findings suggestive of cesarean scar pregnancy.

Revised manuscript accepted for publication November 27, 2017

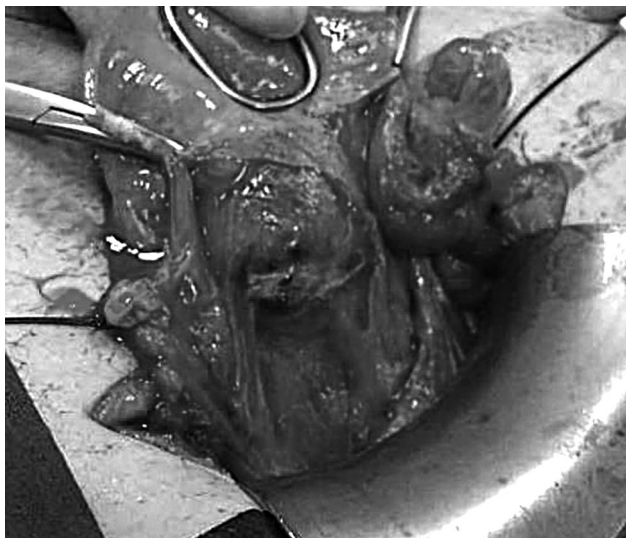


Figure 2. — Ectopic pregnancy bulging towards the serosa.

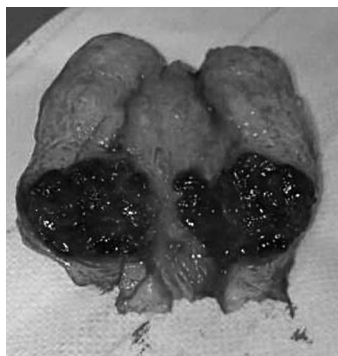


Figure 3. — Macroscopic piece containing cesarean scar pregnancy.

she had spotting since then. Her vital signs were stable; the initial blood test revealed serum  $\beta$ -hCG of 1,628 mU/ml, which indicated pregnancy despite the recent curettage. Ultrasonography showed a 3-cm heterogeneous bulk, located near the previous uterine c-section scar (Figure 1). Dilation and curettage under ultrasound guidance were performed due to significant hemorrhage, ultrasound images, and persistently elevated  $\beta$ -hCG. After curettage, ultrasound continued depicting the same suspicious image on the uterine scar; therefore, an exploratory laparotomy was performed. The authors found a 3-cm ectopic pregnancy within the uterine scar (Figure 2); the surgical team decided to perform a partial hysterectomy to avoid further complications. Pathology evaluation of the uterus confirmed an ectopic pregnancy located in the scarred uterus (Figure 3). The patient was discharged from the hospital after three days of adequate recovery.

#### Case 2

A 41-year-old woman, with a history of two c-sections in previous pregnancies and three curettages, came to this emergency department suffering from vaginal bleeding, vasovagal symptoms, and lower abdominal pain. She had undergone dilation and curettage because of a cervical abortion diagnosis, but due to high levels of  $\beta$ -hCG, another curettage and an exploration with laparoscopy had been performed, with normal results. Upon ar-

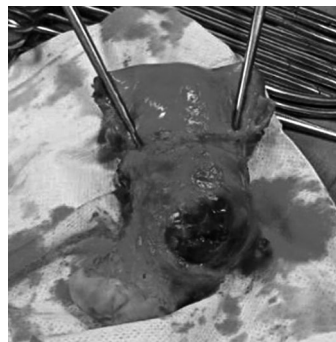


Figure 4. — Ectopic pregnancy located in the scarred uterus, infringing the uterus serosa.

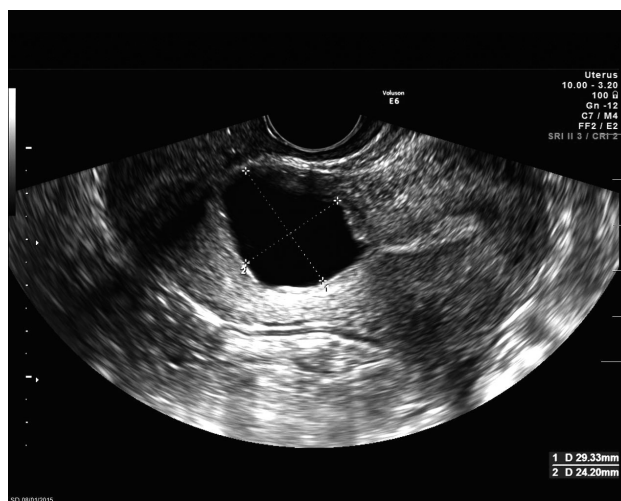


Figure 5. — Gestational sac located in the area of the uterine scar.

rival to the hospital, she was hemodynamically unstable. Transvaginal ultrasonography reported a heterogeneous 4-cm mass near the uterus scar. The  $\beta$ -hCG level was 1,181 mU/ml, suggesting the presence of an ongoing pregnancy. According to previous treatments and massive hemorrhage, a simple abdominal hysterectomy was performed. An embryonic sac located on the segment of the two previous caesarean scars, added to the posterior bladder wall was appreciated. The gross and pathological results of the mass showed the suspected ectopic pregnancy located in the scarred uterus, infringing the uterus serosa (Figure 4). The progress of the patient was satisfactory, being discharged from the hospital four days after surgery.

#### Case 3

A 37-year-old patient with 6.5 weeks of amenorrhea and history of a previous c-section and three curettages five years prior, arrived at this emergency unit with mild vaginal bleeding. The patient was hemodynamically stable. Vaginal sonography revealed a 25×12-mm gestational sac with a 1.7-mm embryo and no cardiac activity, located in the area of the uterine scar (Figure 5). Blood tests revealed high levels of maternal serum  $\beta$ -hCG (19,879 mU/ml). A conservative multi-dose treatment with methotrexate was selected due to her hemodynamic and clinical stability. One mg/kg IM systemic methotrexate was administered on days 1, 3, 5, and 7 interspersed with a daily 15 mg dose of folic acid on days 2, 4, 6, and 8. Blood tests were performed on the eighth day, showing a good response to treatment with a 18% decrease in serum

levels of  $\beta$ -hCG. Analytical and ultrasonographic controls were performed until both hormone and images disappeared six months later.

## Discussion

CSEP is one of the most unusual types of ectopic pregnancy, and a potentially life-threatening condition in case of an inadequate diagnose or non-timely treatment. Since 1978, when Larsen and Salomon reported the first case, the number of published cases has been increasing. The estimated incidence is one per 1,800 to one per 3,000 pregnancies [4, 8, 9]. CSEP rate has increased over the years due to rise in c-sections, as well as improvement in diagnostic equipment.

CSEP involves implantation into the myometrium via a microscopic funnel or a dehiscence in the previous uterine scar [5]. Previous c-sections, curettages or adenomyosis, are responsible for its pathogenesis. The time from a previous c-section to a CSEP is unknown, therefore, early diagnosis is necessary to avoid complications, such as massive hemorrhages, uterine rupture, disseminated intravascular coagulation or even death [4, 9].

Transvaginal ultrasound is the gold standard for the diagnosis of ectopic pregnancy. Despite not clearly defined diagnostic criteria, ultrasound findings such as a thin myometrium between the bladder and the gestational sac, as well as an empty uterine cavity, may be suggestive of an ectopic pregnancy [10]. Based on ultrasound findings, CSEP may be classified into two types: type 1 is characterized by a protruding amniotic sac towards the isthmic portion of the uterine cavity, while type 2 consists of an amniotic sac that bulges towards the serosa. [11, 12].

Inexperienced sonographers may confuse CSEP with an abortion or a cervical pregnancy; therefore, scans must be performed by experts in case of doubt. In some cases, magnetic resonance imaging may be helpful in achieving an accurate diagnosis [12]. An early diagnosis of an CSEP would permit a greater range of less invasive management options, with a lower rate of complications and a higher chance of preserving fertility, but no universal protocol exists due to the low prevalence of this pathology [13].

Several types of conservative treatments have been applied. Surgical approaches including dilation and curettage or excision of trophoblastic tissues (laparotomic, vaginal or laparoscopic approach) have been used [7]. Local and/or systemic administration of methotrexate along with curettage or selective uterine artery embolization have also been performed with equally successful results. [13]

Administration of methotrexate shows a prolonged time before the disappearance of the gestational sac, higher rates of treatment failure, and adverse effects [14]. Recently, selective uterine artery embolization combined with methotrexate administration shows fewer complications and better results [15]. Although the most used adjuvant treatment

is methotrexate, local vasopressin or potassium chloride associated with dilation and curettage, have also been performed with encouraging results [16].

Direct administration of methotrexate through the uterine arteries followed immediately by an occlusion seems to be a promising alternative [13]. The ischemic effect of the occlusion combined with the local effect of methotrexate increases drug concentration with a lower dose and less adverse effects. This treatment has also been used for managing cervical pregnancies or trophoblastic disease [17]. Slow disappearance of the ectopic bulk and the development of collateral circulation may cause bleeding some weeks after methotrexate injection and arterial occlusion. To avoid this collateral event, patients can undergo curettage 24 to 72 hours after treatment. However, more studies are needed to evaluate this technique.

In hospitals with limited resources, local excision should be considered through endoscopy, laparoscopy or laparotomy. In these cases, correction of the uterine wall must undergo, usually combined with methotrexate administration or dilation and curettage [16, 18].

## Conclusions

The low incidence of CSEP results in lack of diagnostic and therapeutic experience. The inability to design randomized controlled trials to evaluate treatment due to the low prevalence, leads to an uncertain terrain for treatment consensus. Most bibliography describes clinical cases, therefore, the present authors describe their experience as a small hospital with limited therapeutic options, where absence of an intensive care unit precludes the performance of an uterine artery embolization. Nonetheless, due to the severity of the disorder, an immediate treatment had to be implemented.

## References

- [1] Mackesy M.M., Chick J.F., Chauhan N.R., Mandell J.C., Khurana B.: "Cesarean section scar ectopic pregnancy". *J. Emerg. Med.*, 2014, 46, 685.
- [2] Zahalkova L., Kacerovsky M.: "Cesarean scar ectopic pregnancy". *Ceska. Gynkol.*, 2016, 81, 414.
- [3] Ash A., Smith A., Maxwell D.: "Caesarean scar pregnancy". *BJOG*, 2007, 114, 253.
- [4] Rheinboldt M., Osborn D., Delproposito Z.: "Cesarean section scar ectopic pregnancy: a clinical case series". *J. Ultrasound*, 2015, 18, 191.
- [5] Mahgoub S., Gabriele V., Faller E., Langer B., Wattiez A., Lecointre L., et al.: "Cesarean scar ectopic pregnancy. Laparoscopic resection and total scar dehiscence repair. A case report". *J. Minim. Invasive Gynecol.*, 2017 Feb 4. pii: S1553-4650(17)30098-5. doi: 10.1016/j.jmig.2017.01.022. [Epub ahead of print]
- [6] Stevens E.E., Ogburn P.: "Cesarean scar ectopic pregnancy: a case report of failed combination local and systemic methotrexate management requiring surgical intervention". *J. Reprod. Med.*, 2011, 56, 356.
- [7] Le A., Shan L., Xiao T., Zhuo R., Xiong H., Wang Z.: "Transvaginal surgical treatment of cesarean scar ectopic pregnancy". *Arch. Gy-*

- necol. Obstet.*, 2013, 287, 791.
- [8] Frishman G.N., Melzer K.E., Bhagavath B.: "Ectopic pregnancy in a cesarean-section scar: the patient >6 weeks into an ectopic pregnancy, underwent local treatment". *Am. J. Obstet. Gynecol.*, 2012, 207, 238.
- [9] Kochhar P.K., Sarangal M., Gupta U.: "Conservative management of cesarean scar pregnancy with uterine arteriovenous malformation: a case report". *J. Reprod. Med.*, 2013, 58, 81.
- [10] Ozkan S., Caliskan E., Ozeren S., Corakci A., Cakiroglu Y., Coskun E.: "Three-dimensional ultrasonographic diagnosis and hysteroscopic management of a viable cesarean scar ectopic pregnancy". *J. Obstet. Gynaecol. Res.*, 2007, 33, 873.
- [11] Ahmadi F., Moinian D., Pooransari P., Rashidi Z., Haghighi H.: "Ectopic pregnancy within a cesarean scar resulting in live birth: a case report". *Arch. Iran Med.*, 2013, 16, 679.
- [12] Chiang A.J., La V., Chou C.P., Wang P.H., Yu K.J.: "Ectopic pregnancy in a cesarean section scar". *Fertil. Steril.*, 2011, 95, 2388.
- [13] Liu W., Shen L., Wang Q., Wang W., Sun Z.: "Uterine artery embolization combined with curettage vs. methotrexate plus curettage for cesarean scar pregnancy". *Arch. Gynecol. Obstet.*, 2016, 294, 71.
- [14] Mergenthal M.C., Senapati S., Zee J., Allen-Taylor L., Whittaker P.G., Takacs P., et al.: "Medical management of ectopic pregnancy with single-dose and 2-dose methotrexate protocols: human chorionic gonadotropin trends and patient outcomes". *Am. J. Obstet. Gynecol.*, 2016, 215, 590.
- [15] Kwon J.H., Kim G.M., Han K., Kim M.D., Won J.Y., Lee D.Y.: "Safety and Efficacy of Uterine Artery Embolization in Ectopic Pregnancies Refractory to Systemic Methotrexate Treatment: A Single-Center Study". *Cardiovasc. Intervent. Radiol.*, 2017, 40, 1351
- [16] Uysal F., Uysal A.: "Spontaneous heterotopic cesarean scar pregnancy: conservative management by transvaginal sonographic guidance and successful pregnancy outcome". *J. Ultrasound Med.*, 2013, 32, 547.
- [17] Shen L., Tan A., Zhu H., Guo C., Liu D., Huang W.: "Bilateral uterine artery chemoembolization with methotrexate for cesarean scar pregnancy". *Am. J. Obstet. Gynecol.*, 2012, 207, 386.
- [18] Sun Y.Y., Xi X.W., Yan Q., Qiao Q.Q., Feng Y.J., Zhu Y.P.: "Management of type II unruptured cesarean scar pregnancy: Comparison of gestational mass excision and uterine artery embolization combined with methotrexate". *Taiwan J. Obstet. Gynecol.*, 2015, 54, 489.

Corresponding Author:  
M. MELÉNDEZ ZALDUEGUI, M.D.  
Department of Gynecology and Obstetrics  
Hospital de Palamós  
Plaza de la Independencia, 12  
Girona 17001 (Spain)  
e-mail: mirentxu\_mz@hotmail.com