

Vaginal endometrial stromal sarcoma: A literature review

Wu Hongwen^{a,1}, Luo Yi^{b,1}, Yin Nanlin^a, Gui Wenwu^a, Cao Yi^{b,*}

^a Reproductive Medical Center, The First Affiliated Hospital of Chongqing Medical University, Chongqing, China

^b Department of Gynecology, The First Affiliated Hospital of Chongqing Medical University, Chongqing China



ARTICLE INFO

Article history:

Received 13 March 2019
Received in revised form 23 August 2019
Accepted 25 August 2019
Available online 27 August 2019

Keywords:

Vaginal endometrial stromal sarcoma
Malignant transformation of endometriosis
Vaginal sarcoma
Endometrial stromal sarcoma

ABSTRACT

Vaginal endometrial stromal sarcoma (V ESS) is a rare disease. To the best of our knowledge, there have only been a few reported cases in the literature. Therefore, we conducted a literature review to obtain specific knowledge of this disease. Thirteen cases of V ESS were found by searching the Medline and EMBASE databases in the English language. The mechanism of V ESS may be associated with endometriosis, and its diagnosis largely depends on pathological examination because it has no typical symptoms. Treatment of V ESS incorporates surgery, chemotherapy, radiotherapy, and hormonal therapy. Some novel drugs targeting its mechanism may become alternative therapies. Its prognostic factors may include tumor stage and the expression of hormonal receptors.

© 2019 The Authors. Published by Elsevier B.V. This is an open access article under the CC BY-NC-ND license (<http://creativecommons.org/licenses/by-nc-nd/4.0/>).

Contents

Introduction	1
Material and methods	1
Results	1
Discussion	3
Conclusion	4
References	4

Introduction

Endometrial stromal sarcoma (ESS) is a rare neoplasm, accounting for only 0.2% of all uterine malignancies [1]. It is even less likely to be found in extra-uterine sites such as the vagina. Vaginal ESS (V ESS) could easily be misdiagnosed because of its rarity and atypical symptoms, and has a very high risk of recurrence, estimated at 50% [2]. Unfortunately, there are no treatment guidelines available. In order to further our understanding of V ESS, we conducted this review.

Material and methods

A computerized literature search was performed to identify relevant studies reported in the English language in the Medline

and EMBASE databases. Since the terms “high-grade endometrial stromal sarcoma” and “low-grade endometrial stromal sarcoma” have been replaced by “undifferentiated sarcoma”, and “endometrial stromal sarcoma” respectively [3], the following keywords were employed: ‘vaginal endometrial stromal sarcoma’, ‘endometriosis malignant transformation’, and ‘vaginal sarcoma’. A total of 13 cases were found. Their symptoms, diagnosis, treatment, and prognosis were summarized and analyzed in this review.

Results

The patients’ ages ranged from 32 to 57(43+/-8.7) years. Their symptoms included vaginal mass (4 patients), vaginal bleeding (7), vaginal discharge (1), pelvic mass (1), and pelvic pain (1). Their FIGO stages ranged from I-IVB, and pathological examination revealed that all cases were low-grade vaginal endometrial stromal sarcoma.

Only four cases had immunohistochemistry results. Three of these cases were positive for estrogen receptor (ER), progesterone receptor (PR), and CD10, and negative for desmin. Further results

* Corresponding author at: Department of Gynecology, The First Affiliated Hospital of Chongqing Medical University, Chongqing, China.
E-mail address: 2488705761@qq.com (Y. Cao).

¹ Co-first authors.

Table 1
Clinical pathological details of 13 patients from previous studies.

First author	Age	symptom	sites	Tumor size	FIGO stage	Grade	Treatment	follow-up length	Recurrence	Histochemistry	Endometriosis
1. Wang [21]	40	VM,VD	Left part of vagina	5cm	IVA	LGESS	Pelvic external radiotherapy + hormone therapy	DOD,12 months	-	Unknown	-
2. Wang [21]	32	VM	Right, lower one third of vagina	1.5cm	I	LGESS	Local wide excision + TAH + BSO	NED,21 months	-	Unknown	-
3. Thomas [6]	32	VM	Right lateral vaginal wall	2.5cm	I	LGESS	local exision + TAH + BSO	NED,3 years	+	Unknown	-
4. Sanverdi [26]	46	VB	posterior fornix	7cm	II	LGESS	TAH + BSO + partial vaginectomy	NED,22 months	-	ER(+), PR(+), CD10(+), desmin (-), and caldesmon (-).	+
5. Masand [4]	52	pelvic mass	Pelvis,rouond ligament, vagina	Unknown	IVB	LGESS	surgical treatment + chemotherapy + radiation therapy	DOD, 96months	+	Unknown	+
6. Masand [4]	51	unknown	Vagina	unknown	I-II ?	LGESS	surgical treatment	Lost follow-up	Unknown	Unknown	-
7. Masand [4]	40	VB	Vagina,pelvis	Unknown	III	LGESS	surgical treatment + hormone therapy + chemotherapy	AWD, 9months	+	Unknown	-
8. Masand [4]	44	VB	Vagina,colon	unknow	IVA	LGESS	Surgical treatment + chemotherapy	DOD,36months	+	Unknown	+
9. Masand [4]	49	Pelvic pain and VB	Ovary,uterine serosa, vagina,urinary bladder, colon,hypogastric LN	Unknown	IVB	LGESS	surgical treatment + hormone therapy + chemotherapy	NED,84months	+	Unknown	+
10. Liu [15]	32	VB	middle and upper segments of the right posterior vaginal wall	1cm	I	LGESS	hysterectomy, unilateral salpingo-oophorectomy (right) and partial vaginectomy + chemotherapy	NED,18months	-	serum AFP, CA125, CA199, CEA, HCG were all negative. CD10(+), ER(+), PR(+), Vimentin (+); desmin(-), muscle actin(-), S-100 protein(-)	-
11. Corpa [27]	40	VM	Vaginal nodule	2cm	I	LGESS	local excision	NED,38months	-	CD10(+), ER(+),PR(+), Desmin (-), muscle actin(-), S-100 protein(-), cytokeratin stains(-)	-
12. Ross [28]	57	VB	Vaginal apex	8cm	II	LGESS	Local excision + radiotherapy	Unknown	Unknown	Unknown	+
13. Kondi [29]	45	VB	Posterior vaginal wall	2cm	II	LGESS	Local excision	NED,36 months	-	Vementine(+)	Unknown

VM, vaginal mass. VD, vaginal discharge. H, hysterectomy. BSO, bilateral salpingo-oophorectomy. DOD, die of disease. NED, no evidence of disease. AWD, alive with disease. TAH, total abdominal hysterectomy.

are shown in Table 1. Twelve patients had received surgery (local excision, total abdominal hysterectomy (TAH), or bilateral salpingo-oophorectomy (BSO)). Five had received chemotherapy, three had received radiotherapy, and three had received hormonal therapy. During the follow-up period [32 (9–96) months], seven patients had no evidence of disease, three patients died of this disease, two patients were lost to follow-up, and one patient was alive with this disease. The three patients who died had advanced clinical stages (IVA/IVB). Five patients had a documented recurrence, including four with an advanced clinical stage (greater than stage III), and one with stage I. Among them, two patients died; two patients had no evidence of disease, and one patient was alive with disease (Table 1).

Discussion

VESS has a high rate of recurrence. The rate of recurrence in our study was 38.5%. Clinically, symptoms of ESS are atypical. The diagnosis of VESS depends on pathological examination after excluding metastatic endometrial stromal sarcoma. Its treatment varies in different medical centers.

Endometriosis may be one mechanism of VESS [4]. It has been estimated that almost 1% of endometrioses may become malignant [5], with 25% of endometriosis-related malignancies found in areas outside the ovaries such as the recto-vaginal septum or abdominal wall [6], and 3.6%–11.1% of these malignancies detected in the vagina [7]. Vaginal mass and vaginal bleeding were common initial symptoms. Because of its atypical symptoms, pathological examination was the main basis of VESS diagnosis. Furthermore, it must be diagnosed after excluding metastatic endometrial stromal sarcoma [8]. VESS is mostly low-grade endometrial stromal sarcoma. Microscopically, it reveals bland oval cells surrounding arterioles resembling endometrial spiral arterioles with no nuclear atypia or pleomorphism (Fig. 1) [2]. The histological morphology of VESS is very similar to some other tumors. Therefore, a comprehensive analysis of multiple immunohistochemical markers, such as desmin, SMA, CD34, CD117, Ki67, VIM, EMA, BCL2, CK, S100, caldesmon, calponin, CD10, ER, PR, STAT6, CD99, and cyclin D is needed to differentiate it from other disease. In low-grade endometrial stromal sarcoma, ER, PR, CD10, and vimentin are usually positive (Fig. 2) [3,9]. When there is epithelial differentiation, CK is usually positive, and when there is

smooth muscle differentiation, muscle markers are usually positive. Genetic testing is a promising tool in the diagnosis of ESS, especially for those tumors which lack typical morphologic features. It was reported that the JAZF1-SUZ12 fusion gene was positive in 30.8% of low-grade ESS cases, and the YWHAE-FAM22 fusion gene was positive in 12.5% of high-grade ESS cases [10]. This genetic testing could also be applied in the diagnosis of VESS.

Because of the rarity of VESS, there is no consensus on its treatment. Treatment often follows the guidelines for uterine ESS. For those with early stage disease or fertility requirements, excision of local lesions is usually performed. It was reported that one patient with uterine ESS achieved a successful pregnancy after hysteroscopic resection of the tumor [11]. For those with advanced clinical stage disease, TAH and BSO are usually performed. However, whether or not to retain the ovaries was controversial in premenopausal women. Some experts argued that BSO should be performed on all patients, while others felt that ovarian-sparing surgery was safe in young patients at early disease stages according to a population-based analysis of ESS. Furthermore, BSO did not appear to affect the time to recurrence or overall survival in stage I low-grade ESS [5,12].

Adjuvant therapy incorporated radiotherapy, chemotherapy, and hormonal therapy. Some argued that surgery and radiotherapy was the most effective treatment for ESS [13], while others thought that radiotherapy could only prevent local recurrence but was not beneficial for survival rate [13]. In our study, three patients (Nos. 1,5,12) received radiotherapy. Among them, two died due to advanced stage disease (Nos. 1,5) and one (No. 12) with early stage disease was lost to follow-up.

Chemotherapy drugs in ESS included cyclophosphamide, cisplatin, ifosfamide, epirubicin, and others [14]. In our study, oxaliplatin, docetaxel [15], and gemcitabine alone or in combination with docetaxel [4] were used. However, the effect of these drugs was not carefully evaluated. In our study, five patients (Nos. 5, 7–10) had single-agent or combined chemotherapy. Four (Nos. 5,7,8,9) of them had a recurrence. Finally, two of them (Nos. 1,8) died, two (Nos. 9,10) had no evidence of disease, and one (No. 7) was alive with disease.

Hormonal therapy was reported to have a favorable survival outcome in ER/PR positive ESS [16]. Mizuno reported three out of six patients with residual or recurrent ESS had a partial response after six months of hormonal therapy [17]. Yamazaki reported a higher response rate was attained with hormonal therapy (85.7%) in 11 ESS patients with initial recurrence of disease [14]. Hormonal therapy was also used as an alternative treatment for patients with fertility requirements. One woman with uterine ESS delivered a live-born male neonate at 34 gestational weeks. The patient had been on megestrol acetate therapy for 8 years before cessation to achieve pregnancy. She was then referred to a reproductive endocrinologist to hasten conception but achieved spontaneous pregnancy [18]. In our study, 3 out of 13 patients received hormonal therapy. One patient (No. 1) with stage IV disease died. One patient (No. 7) was alive with stage III disease, and one (No. 9, stage IVB) had no evidence of disease.

Some drugs targeting mechanisms of ESS could be novel treatment methods which could also be applied in VESS. Endometriosis is connected with angiogenesis, lymphangiogenesis, and neurogenesis, which is related to inflammation [19]. Mizuno evaluated the effects of long-term, high-dose medroxyprogesterone with aspirin and observed no thromboembolic complications over a median duration of 63 months [17]. Although the role of aspirin in preventing endometriosis-related malignancy was not evaluated in this study, it may have some effect due to its anti-inflammatory action. Since unopposed estrogens, type II diabetes, and obesity are risk factors of malignant transformation of endometriosis [20,21], and the insulin and insulin-like growth factor-I receptor family could

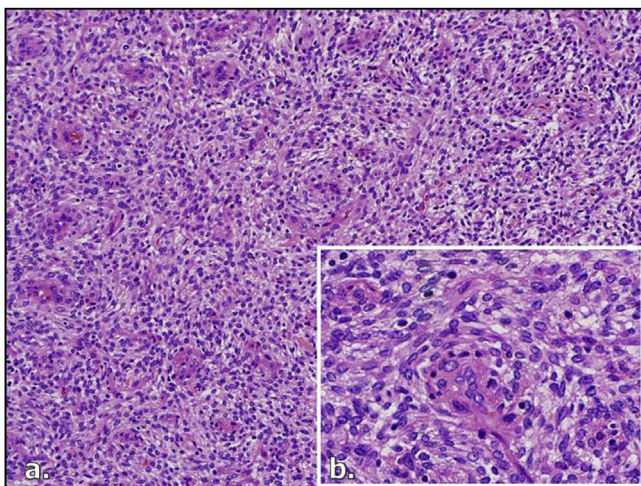


Fig. 1. Vaginal endometrial stromal sarcoma. (a) A cellular neoplasm composed of bland oval cells surrounding arterioles resembling endometrial spiral arterioles (hematoxylin and eosin stain, *200 magnification). (b) A higher magnification microphotograph showing the spindle cells surrounding a blood vessel (hematoxylin and eosin stain, *400 magnification).

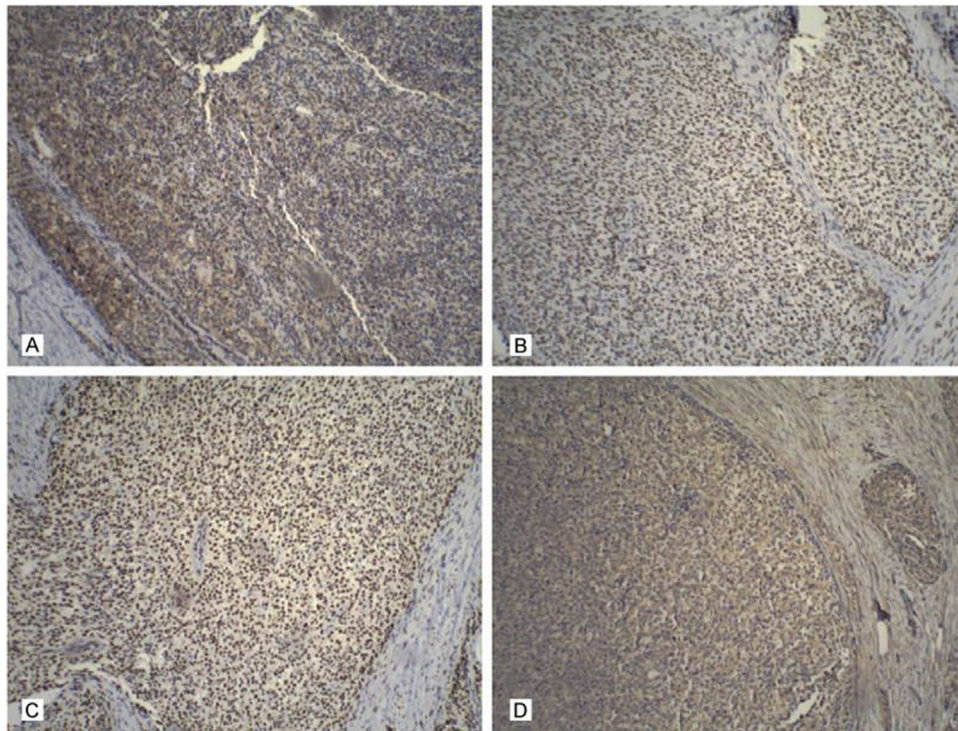


Fig. 2. Immunohistochemical staining of tumor cells. Immunohistochemical staining ($\times 100$) shows that the tumor cells were positive for CD10 (A), estrogen receptor (B), progesterone receptor (C) and vimentin (D).

stimulate DNA synthesis and cell proliferation, anti-insulin resistance drugs might help reduce the risk of malignant transformation of endometriosis [11]. Because follicle-stimulating hormonal receptor (FSHR) is reported to be expressed selectively on the surface of blood vessels in soft tissue sarcomas including ESS [23], FSHR could be a potential target for tumor imaging examination and therapy [23]. Low-grade ESS is often associated with JAZF1-SUZ12 (formerly JAZF1-JJAZ1) fusion gene re-arrangement and Wnt signaling [24]. Overexpression of the JAZF1-SUZ12 fusion protein in 293 T cells could destabilize Polycomb Repressive Complex 2 and decrease histone methyltransferase activity through the Wnt pathway. Therefore, exploring drugs that target the Wnt pathway may lead to a promising treatment.

In our study, patients who died of VESS all had advanced stage disease (Nos. 1,5,8), which was consistent with Ngan's study [25]. Therefore, tumor stage seems to be a prognostic factor of VESS. Hormonal receptors such as ER and PR were expressed in more than half of the ESS tissues in Park's study of 51 patients, and positive hormonal receptors were significantly associated with improved overall survival [17]. In our study, three patients with positive ER and PR had no evidence of disease. Therefore, hormonal receptor expression could be another prognostic factor of VESS.

Conclusion

VESS is a very rare disease without typical symptoms. Pathological examination is needed in order to make an accurate diagnosis. Surgery is highly recommended, and different adjuvant therapies should be adopted cautiously because of their inconclusive roles. Conservative surgery plus adjuvant hormonal therapy may be a good choice for patients at early disease stages, especially for women with fertility requirements. Exploring drugs according to the mechanism of the disease could lead to other treatment options. Tumor stage and expression of hormonal receptors may be prognostic factors of this disease. Further studies are needed because of the limited number of reported VESS cases.

Declaration of Competing Interest

The authors declare no conflict of interest.

References

- [1] Puliath G, Nair VR, Singh S. Endometrial stromal sarcoma. *Indian J Med Pediatr Oncol* 2010;31(Jan. (1)):21–3.
- [2] Zaza KJ, Arafah MA, Al-Badawi IA. Vulvar extrauterine endometrial stromal sarcoma: a case report and literature review. *Hematol Oncol Stem Cell Ther* 2015;8(Sep. (3)):125–9.
- [3] Liu Z, Ding J, Li X, Yu K. Endometrial stromal sarcoma arising in vagina. *Int J Clin Exp Pathol* 2013;6(12):2997–3002.
- [4] Masand RP, Euscher ED, Deavers MT, Malpica A. Endometrioid stromal sarcoma: a clinicopathologic study of 63 cases. *Am J Surg Pathol* 2013;37(Nov. (11)):1635–47.
- [5] Stern RC, Dash R, Bentley RC, Snyder MJ, Haney AF, Robboy SJ. Malignancy in endometriosis: frequency and comparison of ovarian and extraovarian types. *Int J Gynecol Pathol* 2001;20(Apr. (2)):133–9.
- [6] Ulbright TM, Kraus FT. Endometrial stromal tumors of extra-uterine tissue. *Am J Clin Pathol* 1981;76(Oct. (4)):371–7.
- [7] Shah C, Pizer E, Veljovich DS, Drescher CW, Peters 3rd WA, Paley PJ. Clear cell adenocarcinoma of the vagina in a patient with vaginal endometriosis. *Gynecol Oncol* 2006;103(Dec. (3)):1130–2.
- [8] Rivard C, Carter JS, Downs Jr. LS. Low-grade endometrial stromal sarcoma primarily arising in the vagina: a case report. *J Reprod Med* 2015;60(Sep.–Oct. (9–10)):433–5.
- [9] Rauh-Hain JA, del Carmen MG. Endometrial stromal sarcoma: a systematic review. *Obstet Gynecol* 2013;122(Sep. (3)):676–83.
- [10] Chang B, Lu LX, Tu XY, Cheng YF, Bi R, Yang WT. Endometrial stromal sarcoma: morphologic features and detection of JAZF1-SUZ12 and YWHAE-FAM22 fusion genes. *Chin J Pathol* 2016;45(5):308–13.
- [11] Koskas M, Morice P, Yazbeck C, Duvillard P, Walker F, Madelenat P. Conservative management of low-grade endometrial stromal sarcoma followed by pregnancy and severe recurrence. *Anticancer Res* 2009;29(Oct. (10)):4147–50.
- [12] Kim WY, Lee JW, Choi CH, Kang H, Kim TJ, Bim BG, et al. Low-grade endometrial stromal sarcoma: a single center's experience with 22 cases. *Int J Gynecol Cancer* 2008;18(5):1084–9.
- [13] Weitmann HD, Knocke TH, Kucera H, Potter R. Radiation therapy in the treatment of endometrial stromal sarcoma. *Int J Radiat Oncol Biol Phys* 2001;49(Mar. (3)):739–48.
- [14] Yamazaki H, Todo Y, Mitsube K, Hareyama H, Shimada C, Kato H, et al. Long-term survival of patients with recurrent endometrial stromal sarcoma: a multicenter, observational study. *J Gynecol Oncol* 2015;26(3):214.

- [15] Liu G, Zhang C, Ma Z, Zhang Q, Liu B. Endometrial stromal sarcoma with endometrioid adenocarcinoma of the uterus: a case report. *Int J Clin Exp Pathol* 2015;8(5):5242–6.
- [16] Park J-Y, Baek M-H, Park Y, Kim Y-T, Nam J-H. Investigation of hormonal receptor expression and its prognostic value in endometrial stromal sarcoma. *Virchows Arch* 2018;473(1):61–9.
- [17] Mizuno M, Yatabe Y, Nawa A, Nakanishi T. Long-term medroxyprogesterone acetate therapy for low-grade endometrial stromal sarcoma. *Int J Clin Oncol* 2012;17(Aug. (4)):348–54.
- [18] Delaney AA, Gubbels AL, Remmenga S, Tomich P, Molpus K. Successful pregnancy after fertility-sparing local resection and uterine reconstruction for low-grade endometrial stromal sarcoma. *Obstet Gynecol* 2012;120(Aug. (2 Pt. 2)):486–9.
- [19] Kobayashi H, Higashiura Y, Shigetomi H, Kajihara H. Pathogenesis of endometriosis: the role of initial infection and subsequent sterile inflammation (Review). *Mol Med Rep* 2014;9(1):9–15.
- [20] Zanetta GM, Webb MJ, Li H, Keeney GL. Hyperestrogenism: a relevant risk factor for the development of cancer from endometriosis. *Gynecol Oncol* 2000;79(1):18–22.
- [21] Wang C-T, Wang D-B, Liu K-R, Li Y, Sun C-X, Guo C-S, et al. Inducing malignant transformation of endometriosis in rats by long-term sustaining hyperestrogenemia and type II diabetes. *Cancer Sci* 2015;106(1):43–50.
- [23] Renner M, Goeppert B, Siraj MA, Radu A, Ghinea N. Follicle-stimulating hormonal receptor expression in soft tissue sarcomas. *Histopathology* 2013;63 (Jul. (1)):29–35.
- [24] Przybyl J, Kidzinski L, Hastie T, Debiec-Richter M, Nusse R, van de Rijn M. Gene expression profiling of low-grade endometrial stromal sarcoma indicates fusion protein-mediated activation of the Wnt signaling pathway. *Gynecol Oncol* 2018;149(May (2)):388–93.
- [25] Ngan HY, Fisher C, Blake P, Shepherd JH. Vaginal sarcoma: the Royal Marsden experience. *Int J Gynecol Cancer* 1994;4(Sep. (5)):337–41.
- [26] Sanverdi I, Temizkan O, Vural F, Koc N, Polat M. Primary vaginal endometrial stromal sarcoma associated with endometriosis: a case report with a review of the literature. *Eur J Gynaecol Oncol* 2016;3(7):717–21.
- [27] Corpa MV, Serafini EP, Bacchi CE. Low-grade endometrial stromal sarcoma presenting as vaginal nodule. *Ann Diagn Pathol* 2004;8(5):295–8.
- [28] Berkowitz RS, Ehrmann RL, Knapp RC. Endometrial stromal sarcoma arising from vaginal endometriosis. *Obstet Gynecol* 1978;51:34s–7s.
- [29] Kondi-Paphitis A, Smyrniotis B, Liapis A, Kontoyanni A, Deligeorgi H. Stromal sarcoma arising on endometriosis. A clinicopathological and immunohistochemical study of 4 cases. *Eur J Gynaecol Oncol* 1998;19(6): 588–90.