



Contents lists available at ScienceDirect

European Journal of Obstetrics & Gynecology and Reproductive Biology: X

journal homepage: www.elsevier.com/locate/eurox

Endometriosis and ovarian cancer: Their association and relationship

Ernesto Bas-Esteve^{a,1}, María Pérez-Arguedas^{a,2}, Gonzalo Ariel Guarda-Muratori^b,
Maribel Acién^c, Pedro Acién^{c,*}

^aObstetrics and Gynecology Service, Marina Baixa Hospital, 03735, Villajoyosa, Alicante, Spain

^bPathological Anatomy Service, Marina Baixa Hospital, 03735, Villajoyosa, Alicante, Spain

^cObstetrics and Gynecologic Service, San Juan University Hospital and Department/Division of Gynecology, Miguel Hernández University, San Juan. Campus, 03550, San Juan, Alicante, Spain

ARTICLE INFO

Article history:

Received 19 February 2019

Received in revised form 17 May 2019

Accepted 18 May 2019

Available online 22 May 2019

Keywords:

Endometriosis

Ovarian cancer

Endometrioid

Clear cell

Borderline

Ovarian tumors

ABSTRACT

Objectives: To study endometriosis-associated borderline or malignant ovarian epithelial tumors by analyzing their differential clinical features, as well as the histological pattern, survival and immunohistochemical data compared with those without associated endometriosis.

Study design: Setting: Hospital Marina Baixa and San Juan University Hospital, Alicante, Spain. This retrospective study included clinical and pathological data from 36 operated cases with endometriosis-associated ovarian epithelial tumors and 305 cases of ovarian epithelial tumors without endometriosis, including borderline and invasive tumors. We also studied hormonal receptors and p53 protein expression in 13 cases with endometriosis-associated endometrioid and clear cell tumors, and report two cases with histologically-confirmed previous endometriosis.

Results: Associated endometriosis was observed in 10.5% of patients with borderline or invasive ovarian epithelial tumor, 53% of those with endometrioid, and 22% with clear cell tumors. Patients with endometriosis-associated ovarian epithelial tumors were younger, had lower parity, were more frequently premenopausal, had a lower tumor stage or were borderline, and in general had better prognosis and longer survival, although they also more frequently had an associated endometrial carcinoma. Associated endometriosis and endometrioid tumors were generally estrogen-receptor positive, whereas they were negative in the clear cell tumor component. p53 protein positivity was generally observed in clear cell tumors and in associated endometriosis. Two reported cases with previous, known endometriosis were followed in their evolution to borderline endometrioid carcinoma and clear cell carcinoma, respectively.

Conclusions: Our results and review of the literature suggest that the association of ovarian epithelial tumors and endometriosis is a factor for good prognosis for ovarian cancer and that this association might correspond in many cases to an intermediate stage in the development of endometriosis to endometrioid, clear cell, or other invasive carcinomas.

© 2019 The Authors. Published by Elsevier B.V. This is an open access article under the CC BY-NC-ND license (<http://creativecommons.org/licenses/by-nc-nd/4.0/>).

Introduction

Ovarian epithelial tumors (OETs) represent 75% of all ovarian tumors and 90% of borderline or malignant tumors in this location [1]. OETs originate in the epithelium that lines the ovary, which in

turn is embryologically derived from the primitive peritoneum. The Müllerian ducts also derive from an invagination of the primitive peritoneum that results in the Fallopian tubes and uterus. OETs are, therefore, similar to tumors arising from the Müllerian duct in that they may be tubes (serous), endocervical (mucinous), endometrial (endometrioid and clear cell, and may undergo urothelial metaplasia (transitional cell tumors) [1]. Endometrioid and clear cell OETs are often associated with endometriosis [2], which has been suggested to be the origin of this type of tumor [3]. Atypical endometriosis [4] has also been suggested as a transitional phase from benign endometriosis to carcinoma, meaning that it could be a precursor lesion of endometrioid and clear cell ovarian cancers [3,5–7]. Ovarian cancers that are associated with endometriosis appear to be a

* Corresponding author.

E-mail addresses: erbases@hotmail.com (E. Bas-Esteve),

maria_p_a_22@hotmail.com (M. Pérez-Arguedas), g076@hotmail.com

(G.A. Guarda-Muratori), macien@umh.es (M. Acién), acien@umh.es (P. Acién).

¹ Present address: Obstetrics and Gynecology Service, La Fe Hospital, 46009 Valencia, Spain.

² Present address: Obstetrics and Gynecology Service, Manises Hospital, 46940, Manises, Valencia, Spain.

<http://dx.doi.org/10.1016/j.eurox.2019.100053>

2590-1613/© 2019 The Authors. Published by Elsevier B.V. This is an open access article under the CC BY-NC-ND license (<http://creativecommons.org/licenses/by-nc-nd/4.0/>).

different entity, with an earlier age of onset and a relatively better prognosis [8–10]; therefore, concurrent endometriosis could be a factor of good prognosis for associated ovarian cancers [11–13].

Sampson [14] was the first to describe the association between endometriosis and carcinoma, later followed by Scott [15], who defined the diagnosis of endometriosis-associated OET. Since then, numerous studies have analyzed this association [16–19]. Wei et al. [3] also reviewed the natural history of endometriosis and its possible progression to endometriosis-associated OET. Some cases of endometriosis-associated OETs seem to be the ultimate consequence of such processes. However, in most patients with associated endometriosis, this progression and malignant transformation are not so clear, as the finding of endometriosis associated with OET is synchronous in most cases and there is not enough evidence of patients with histologically confirmed endometriosis who have subsequently developed carcinoma [20,21].

The objectives of this study were to 1) analyze cases of endometriosis-associated borderline or malignant OET to assess their differential features in comparison with cases without associated endometriosis and factors that may influence the association or progression to carcinoma, and 2) to deduce from previous analyses whether the clinical, histopathological, and immunohistochemical findings support the possible progression of endometriosis to endometriosis-associated carcinoma and, ultimately, to ovarian cancer.

Material and methods

Study design

This retrospective study analyzed clinical and pathological data from operated patients having borderline or invasive OET with associated endometriosis compared to those of other cases also operated for OET without associated endometriosis.

Participants

Two series of patients were included in this study. Series 1 included all 131 cases of borderline (n=36) and invasive or malignant (n=95) diagnosed OETs operated and treated at Hospital Marina Baixa between June 1995 and June 2015. Review of the histopathological reports of all cases revealed that 15 (11.5%) patients had associated endometriosis. Series 2 included all 210 cases of borderline (n=67) and invasive or malignant (n=143) diagnosed OETs operated and treated at San Juan University Hospital during the same period, including 21 (10%) cases of OET with associated endometriosis. Therefore, this study included and analyzed data from 341 patients with OETs: 36 cases of endometriosis-associated OET (13 borderline and 23 invasive) and 305 without associated endometriosis, including 90 and 215 cases of borderline and invasive OETs, respectively.

Research plan and criteria

The epidemiological, clinical, histopathological, and survival data of the 341 included patients were revised, studied, and analyzed. The borderline OETs (103 cases, 30.2%, 13 with associated endometriosis and 90 without endometriosis) included serous, mucinous, endometrioid, and clear cell or mesonephroid tumors with marginal malignancy or low malignant potential according to World Health Organization (WHO) histological classification [22]. The invasive or malignant OETs (238 cases, 69.8%, 23 with and 215 without endometriosis, respectively) included serous, mucinous, endometrioid, clear cell or mesonephroid, and mixed malignant, as well as undifferentiated carcinomas. Patient clinical

characteristics, tumor markers, tumor histology and staging, associated pathology, surgery performed, postoperative clinical course, and data for survival analysis were collected. Data on the presence and type of endometriosis when associated with OET, as well as the association with other malignant tumors, especially endometrial carcinoma, were also collected.

In this study, endometriosis-associated ovarian carcinoma was defined by the presence of OET and endometriosis in the same or

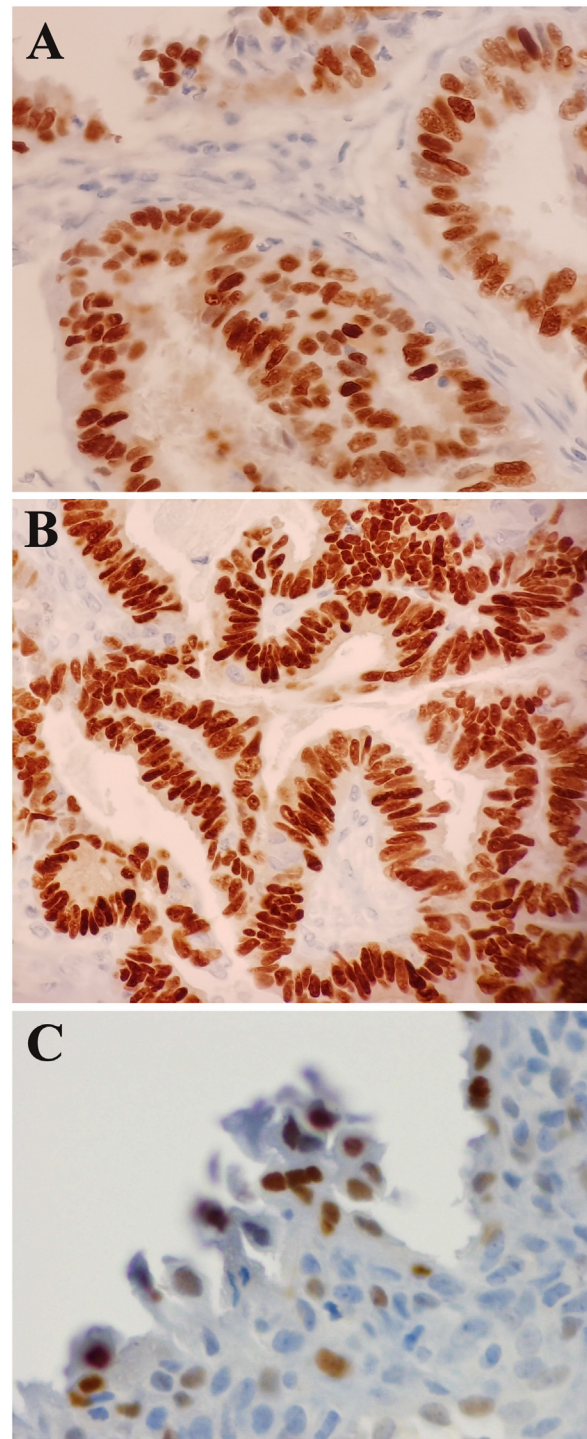


Fig. 1. Immunohistochemical study for estrogen and progesterone receptors and p53 protein. A) Endometrioid carcinoma: moderate positivity for estrogen receptors, 40 \times . B) Endometrioid carcinoma: moderate-intense positivity for progesterone receptors, 40 \times . C) Endometriosis: moderate-intense positivity for p53, 40 \times .

contralateral ovary or extraovarian pelvic endometriosis. Endometriosis was identified as tissue resembling endometrial stroma surrounding epithelial glands present in the ovaries or peritoneum. Atypical endometriosis was defined according to the criteria proposed by Thomas and Campbell [23] based on features identified in histological examinations as well as positivity for p53 expression. According to these criteria, atypical endometriosis was identified in postoperative pathological study of five cases associated with OET (all from series 2) and 3 of 15 patients in series 1 were possibly atypical (p53+). Furthermore, based on a dualistic model of carcinogenesis and Kurman and Shih's classification [24,25], we divided the OET cases included in this study into two groups: 1) type I tumors comprising borderline and low-grade serous carcinomas, mucinous, endometrioid, clear cell, and transitional cell carcinomas, and 2) type II tumors comprising high-grade serous cancer, malignant mixed mesodermal tumors, and undifferentiated carcinomas.

The clinical and pathological characteristics as well as the survival (%) at two, five and 10 years and the actuarial survival (Kaplan-Meier method) of the different subtypes, with or without associated endometriosis, were compared.

Immunohistochemical studies were also performed in cases with endometriosis-associated endometrioid and clear cell OETs from series 1, to analyze any differences in the presence or absence of estrogen-receptor, progesterone-receptor, and p53 protein expression both in endometriosis and in the tumor (see Fig. 1). Finally, we individually analyzed and described two cases (from series 2) with histologically confirmed endometriosis prior to OET diagnosis and with data on previous and subsequent evolution.

Statistical analysis

The statistical analysis was performed as follows: qualitative data were analyzed in terms of frequencies and percentages and quantitative data in terms of means and standard deviation (SD). Comparison of independent means (Student's t-test), comparison of two proportions (relative risk [RR]), 95% confidence intervals (CIs), and Chi-square tests were used to compare groups. Finally, the actuarial survival was analyzed in all OET groups after two, five, and 10 years of follow-up according to the Kaplan-Meier method of estimated survival. Statistical treatment of the data was performed using IBM SPSS Statistics, version 20.0 and 25 (IBM-Spain), Ccalculator, and Rsigma (Systat Software, San Jose, Calif., USA). All p-values reported were 2-tailed and $p < 0.05$ was considered statistically significant.

Results

Baseline characteristics

The characteristics of two subseries of studied patients with OETs (131 cases from Hospital Marina Baixa and 210 from San Juan University Hospital) are shown in Table 1. There were no significant differences in the data corresponding to age, parity, menopause status, tumor markers, invasiveness, histological subtype, atypical endometriosis, associated endometrial carcinoma, and survival between the subgroups. However, it was significantly more frequent stage III, and less frequent stage I, in series 2. Subsequently, the survival at 5 years in series 2 was somewhat lower, but without reaching statistical significance.

Table 1
Baseline characteristics of studied patients with ovarian epithelial tumors.

Characteristics	Series 1: Patients operated in HMB, 131 cases	Series 2: Patients operated in SJUH, 210 cases
Age, years, m \pm SD (range)	55,9 \pm 14,8 (45-87)	56,2 \pm 14,6 (44-88)
Parity: Nulliparous, n (%)	37 (28,2)	62 (29,5)
\geq Primiparous, n (%)	94 (71,8)	148 (70,5)
Menopause age, (n) m \pm SD (range)	(79) 48,7 \pm 4,6 (36-57)	(90) 49,1 \pm 3,8(35-57)
Premenopausal, (n, %)	45 (34,4)	78 (37,1)
Postmenopausal, (n, %)	86 (65,6)	132 (62,9)
CA-125 U/mL (n), m \pm SD	(114) 521,8 \pm 1085,4	(107) 627,5 \pm 1383,8
CA-19-9 U/mL (n), m \pm SD	(109) 638,3 \pm 4873,1	(104) 332,0 \pm 1194,7
BSR mm/h (n), m \pm SD	(77) 35,9 \pm 32,4	(103) 35,9 \pm 26,2
Borderline n (%)	36 (27,5)	67 (31,9)
Invasive (n, %)	95 (72,5)	143 (68,1)
With associated endometriosis, n(%)	15 cases (11.5%)	21 cases (10%)
[BL/Inv]	[4 (26.7)/11 (73.3)]	[9 (42.8)/12 (57.1)]
Atypical endometriosis or p53+	p53+ = 3(20)	Atypical end = 5(23.8)
Associated endometrial Ca in End/No end	3/15(20%)/7/116(6%)	3/21(14.3%)/8/189(4.2%)
Type I tumors, n (%) / [Inv]	84 (64,1) / [48]	116 (55,2) / [50]
Type II tumors, n (%) / [Inv]	47 (35,9) / [47]	94 (44,8) / [93]
Endometrioid, CC, and mix / [Inv]	35 (26,7) / [34]	39 (18,6) / [33]
Serous, mucinous, undiff. / [Inv]	96 (73,3) / [61]	171 (81,4) / [110]
FIGO stage (all/invasive cases)*		
I, n (%) /	70 (53,4) / 37(38,9)*	84(40) / 32(22,4)
II, n (%) /	8(6,1) / 6(6,3)	25(11,9) / 17(11,9)
III, n (%) /	38(29,0) / 37(38,9)*	79(37,6) / 73(51,0)
IV, n (%) /	15(11,5) / 15(15,8)	22(10,5) / 21(14,7)
Survival at 5 years (all/inv)		
• Operated <5 years	26(19,8) / 17(17,9)	50(23,8) / 30(21,0)
• Dead < 5 years	34(26,0) / 32(33,7)	70(33,3) / 66(46,2)
• Survival > 5 years	52(39,7) / 32(33,7)*	64(30,5) / 34(23,8)
• Unknown.	19(14,5) / 14(14,7)	26(12,4) / 13(9,1)

*chi-squared test 0,000; +, chi-squared test 0,066 (NS).

n = number; m = mean; SD = standard deviation; (r) = range; % = percentage; BSR: blood sedimentation rate; NS: not statistically significant.

Table 2
Differential clinical features between ovarian epithelial tumors (OETs) associated and not associated with endometriosis.

	OET with endometriosis	OET without endometriosis	RR (CI)	P, Chi ²
Number of cases	36	305		–
Age, years [n] m ± SD (r)	[36] 50.9 ± 11.2 (32-76)	[305] 56.7 ± 14.9 (16-87)		<0.025
Parity, (n, %)	[36] 1.03±1.23	[305] 1.74±1.49		<0.005
Nulliparous	18 (50)	81 (26.6)	1,5(1,05-2,05)	
≥Primiparous	18 (50)	224 (73.4)		NS
Premenopausal, (n, %)	20 (55.6)	103 (33.8)		
Postmenopausal, (n, %)	16 (44.4)	201 (65.9)		<0.035
Age of menopause, years [n] m ± SD	[16] 50.3 ± 4.6	[153] 48.8 ± 4.2		NS
Personal history (n, %)				
• No history	22 (61.1)	[121] 86 (71.1)		NS
• Breast cancer	1 (2.8)	2 (1.7)		
• Endometrial cancer	0 (0)	1 (0.8)		
• Endometriosis	2 (5.6)	4 (3.3)		
• Other	11 (30.5)	28 (23.2)		
Family history (n, %)				
• No history	28 (77.8)	[124] 82 (66.1)		NS
• Ovarian cancer	1 (2.8)	2 (1.6)		
• Endometrial cancer	0 (0)	6 (4.8)		
• Breast cancer	2 (5.6)	10 (8.1)		
• Other	5 (13.8)	24 (19.5)		
CA-125 U/mL [n, m ± SD]	(29) 224.9 ± 311.18	(192) 625.6 ± 1314.3		NS
CA-19–9 U/mL [n, m ± SD]	(28) 244.7 ± 484.6	(185) 525.7 ± 3836.6		NS
BSR mm/h [n, m ± SD]	(26) 41.50 ± 34.6	(154) 34.9 ± 27.8		NS
Ascites (n, %)				
Abundant	[23]2 (8.7)	[113]27 (23.9)	NS	NS
Mild	3 (13.0)	16 (14.2)		
No ascites	18 (78.3)	70 (61.9)		
Surgery (n, %)				
Conservative surgery: laparotomy	3 (8.3)	[282] 54 (19.1)		NS
Conservative surgery: laparoscopy	2 (5.6)	9 (3.2)		
Hysterectomy + bilateral adnexectomy	3 (8.3)	29 (10.3)		
Extended surgery	28 (77.8)	190 (67.4)	–	
Cytoreduction, (n, %)				
Optimal	34 (94.3)	[121] 83 (68.6)	0,7 (0,6-0,8)	0,008
>1 cm remaining	2 (5.7)	24 (19.8)		
Biopsy only and closure	0 (0)	14 (11.6)		
FIGO stage (n, %)				
I	23 (63.9)	131 (43.0)	0,7(0,5-0,9)	0,07
II	6 (16.7)	27 (8.9)	2,2(1,02-4,56)	
III	6 (16.7)	110 (36.1)		
IV	0 (0)	37 (12.1)		

[n]=number; m=mean; SD=standard deviation; (r)=range; %=percentage; RR: relative risk; CI: confidence interval; BSR: blood sedimentation rate; FIGO: International Federation of Gynecology and Obstetrics; NS: not statistically significant.

Differential clinical features

Table 2 shows the differential clinical features of OETs associated (n = 36) or not associated (n = 305) with endometriosis. The most important of these differential features were significantly lower age (50.9 years versus 56.7), parity (50% nulliparous versus 26.6%), and premenopausal status (55.6% versus 33.8%). There were no significant differences in personal or family history of cancer or endometriosis. Moreover, endometriosis was classed as atypical or with p53+ in eight of the 36 cases (22.2%). With regard to the analytical data, the blood sedimentation rate was similar and tumor markers carbohydrate antigen (CA)-125 and CA-19-9 were higher in patients with OETs without endometriosis, but the differences did not reach statistical significance. Neither the differences for the presence of ascites nor for the surgery performed were significant, but it was significant that the percentage of cytoreduction was optimal in cases with associated endometriosis (94.3% versus 68.6% in OETs without

endometriosis). This pattern was the same for International Federation of Gynecology and Obstetrics (FIGO) cancer stage, which was significantly lower in those with endometriosis-associated OET (63.9% were FIGO stage I versus 43% in OETs without endometriosis; and 16.7% were FIGO stage III versus 36.1% in OETs without endometriosis).

Histological subtypes, invasiveness, recurrence, and survival were also compared between OETs with and without endometriosis. As shown in Table 3, the total percentage of endometrioid and clear cell OETs, both individually and jointly, was greater in the endometriosis-associated OET group (75% versus 15.4%), while the opposite was observed for serous, mucinous, and undifferentiated OET. A statistically significant association was found between endometriosis and an increased risk of endometrioid and clear cell OET versus OET without endometriosis (RR 6.4; 95% CI, 4–10.5 and RR 4.2; 95% CI, 2–9.2 for endometrioid and clear cells OET respectively). However, most serous and mucinous tumors were not associated with endometriosis; when they were, they were

Table 3

Comparisons of ovarian epithelial tumors (OETs) associated or not associated with endometriosis according to histological type, invasiveness, recurrence, and survival.

	OET with Endometriosis (36)	OET without Endometriosis (305)	RR (CI)	P Chi ²
<i>Histological Subtype (n, %)</i>				
Serous	3 (8.3)	146 (47.9)	0.17	
(BL=51; Inv=98)	(2 BL, 1 Inv)	(49 BL, 97 Inv)	0.05-0.5)	
Mucinous	6 (16.7)	69 (22.6)	NS	
(BL=45; Inv=30)	(6 BL)	(39 BL, 30 Inv)		
Endometrioid	19 (52.8)	25 (8.2)	6.4	
(BL=6; Inv=38)	(5 BL, 14 Inv)	(1 BL, 24 Inv)	(4-10.5)	
Clear cell	8 (22.2)	16 (5.2)	4.2	
(BL=1; Inv=23)	(8 Inv)	(1 BL, 15 Inv)	(2-9.2)	
Endometrioid + clear	27 (75.0)	47 (15.4)	4.9	
cell+mix	(5 BL, 22 Inv)	(2 BL, 45 Inv)	(3.5-6.7)	
Undifferentiated	0(0)	43 (14.1)	-	
	(0)	(43 Inv)		
Borderline (n, %)	13 (36.1)	90 (29.5)	NS	
Invasive (n, %)	23 (63.9)	215 (70.5)		
<i>Kurman and Shih's classification (n, %)</i>				
Type I	35 (97.2)	165 (54.1)	1.8	<0.000
Type II	1 (2.8)	140 (45.9)	(1.6-2.02)	
No. of recurrences, in months	[2] {5.2} 15 ± 12.72; (6-24)	[19] {16.4} 20.68 ± 13.35; (1-47)	NS	
[n] {%} m ± SD (r)				
Associated endometrial cancer, (n, %)	6 (16.8)	15 (4.9)	3.4 (1.4-8.2)	
Survival in BL/Inv and total, n (%) at:				
>2 years	9 (69.2)/13 (56.5), 22 (61.1)	68 (75.6)/104(48.4), 172 (56.4)	NS	0,027
>5 years	3(23.1)/8(34.8), 11(30.6)	47(52.2)/58(27.0), 105(34.4)	NS	0,006
>10 years	1(7.7)/5(21.7), 6(16.7)	19(21.1)/28(13.0), 47(15.4)	NS	0,039
<i>Kaplan-Meier survival (%)</i>				
2 years (BL/Inv)	(100/ 84,6)	(97,4*/64,4*)	0,8 (0,6-0,9)	
5 years (BL/Inv)	(84,6/ 76,9)	(92,4*/46,6*)	0,6 (0,5-0,8)	
10 years (BL/Inv)	(84,6/ 65,9)	(90,1*/33,6*)	0,5 (0,4-0,6)	

(n)=number; m = mean; SD = standard deviation; (r)=range; %= percentage; RR = relative risk; CI = confidence interval; BL = borderline; Inv = invasive; NS = not statistically significant. +, RR, not significant (BL) / x, RR, significant (Inv).

more often borderline tumors. Differences in type I Kurman and Shih's classifications were also significant (97% versus 46%; Chi-squared test, 0.000)

There were no significant differences in recurrences due to the low number of cases considered. Likewise, the finding of synchronous endometrial cancer and OET was not significant, but there was an increased risk of this association (RR 3.4; 95% CI, 1.4-8.2) in the endometriosis-associated OET group, although endometrioid was the only subtype. We observed increased survival (significant for invasive tumors) in the endometriosis-associated OET group for all assessed time intervals (two, five, and 10 years).

As shown in Fig. 2A, comparison of the survival rates for OETs with and without endometriosis and according to borderline or invasive status revealed worse two-, five-, and 10-year survival rates for invasive tumors without associated endometriosis. Patients with borderline tumors survived longer than those who presented with an invasive tumor but women with invasive tumors that were not associated with endometriosis had a lower survival rate than those with associated endometriosis ($p < 0.05$). As shown in Fig. 2B, analysis and representation of two-, five-, and 10-year survival by Kaplan-Meier analysis in invasive OETs with or without associated endometriosis according to histological subtype revealed lower survival rates in cases without associated endometriosis and undifferentiated histology, mucinous, clear cell and serous (in this same reverse order) and the best survival rates in clear cell and endometrioid with endometriosis. Finally, Fig. 2C also shows the analysis and representation of two-, five-, and 10-year survival by Kaplan-Meier analysis in invasive OET with or without associated endometriosis according to FIGO stages. Survival was greater than 90% at 10 years in stage I and II with associated endometriosis; between 60% and 80% in stages I and II

without associated endometriosis; and less than 30% in stage III and IV (usually without associated endometriosis).

Comparison of immunohistochemical data

Table 4 shows the immunohistochemical results in patients with endometriosis-associated endometrioid (n = 7) or clear cell (n = 6) OET. The endometrioid subtypes presented estrogen-receptor, progesterone-receptor, and p53 positivity, in both the endometriotic tissue and the tumor. However, in the clear cell subtype, estrogen-receptor and progesterone-receptor positivity was observed in the endometriotic tissue and not in the tumor, a statistically significant difference. The p53 protein was present in both the endometriotic tissue and the tumor, especially in clear cell OET.

Cases with histologically confirmed previous endometriosis

Finally, Table 5 shows two cases with endometriosis-associated OET but with histologically confirmed previous endometriosis whose progress was monitored. Case 1 (endometrioid OET and endometriosis) had previously been diagnosed with atypical endometriosis and was estrogen-receptor (-), progesterone-receptor (-), and p53-positive; CA-19-9, in particular, was increased when she suffered a recurrence and the histopathology of the second operation once again showed endometriosis together with a borderline endometrioid tumor, with positive staining for estrogen-receptor, progesterone-receptor, and aromatase in the tumor and endometriotic tissues. P53 protein positivity was observed in tumor but not in endometriotic tissue. After her endometriosis diagnosis, Case 2 (clear cell carcinoma and endometriosis) was followed-up for infertility and underwent in

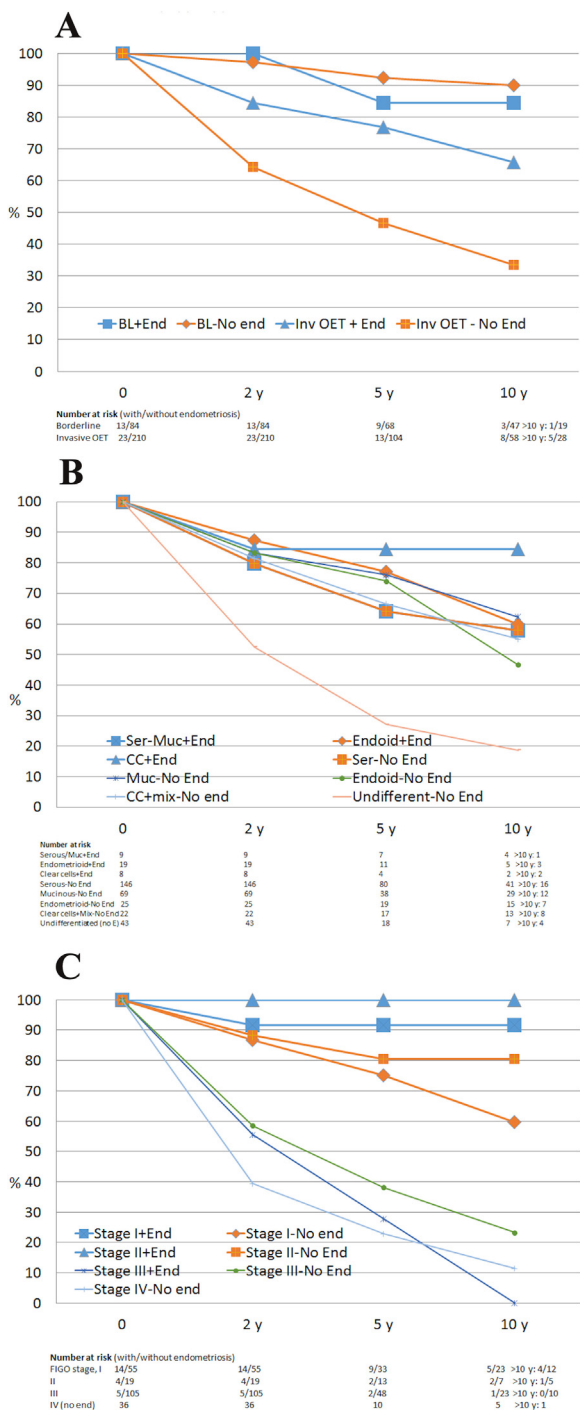


Fig. 2. Kaplan-Meier survival curves for ovarian epithelial tumors at two, five, and 10 years. A) In borderline and invasive ovarian epithelial tumors with or without endometriosis. B) In invasive ovarian epithelial tumors (according to histological subtype) with and without endometriosis. C) In invasive OET (according to FIGO stage) with and without endometriosis.

vitro fertilization and a twin pregnancy. Three years later, she required urgent hospital admission for a superinfected ovarian cyst or endometrioma and hemorrhagic ascites. Her blood sedimentation rate, CA-125, and CA-19-9 values were all elevated, particularly CA-125. Surgery and histopathology showed undifferentiated clear cell carcinoma and foci of endometriosis throughout the pelvis. Immunohistochemical study showed positive staining for p53 protein in the endometriosis and tumor and estrogen-

Table 4

Immunohistochemistry (ER, PR, and p53) of patients with endometrioid versus clear cell ovarian epithelial tumors (OETs) with associated endometriosis at Hospital Marina Baixa (HMB).

IHC	Endometrioid OET (n, %)	Clear cell OET (n, %)	P-value
Endometriosis	ER(+) 4/4 (100)	2/2 (100)	NS
	PR(+) 4/4 (100)	1/2 (50)	NS
	P53 2/4 (50)	2/2 (100)	NS
Tumor	ER(+) 6/7 (85.7)	0/6 (0)	<0.05
	PR(+) 6/7 (85.7)	1/6 (16.6)	<0.05
	P53 5/7 (71.4)	5/6 (83.4)	NS
	(+)		

(n)=number; %= percentage; IHC = immunohistochemistry; ER = estrogen receptor, PR = progesterone receptor; NS = not statistically significant.

receptor and progesterone-receptor positivity in the endometriotic tissue but not in the tumor.

Comment

Our results show that the patients with OET and associated endometriosis represent 10.6% of cases with borderline or invasive OETs but they are younger, with lower parity, and more frequently premenopausal than those in patients with OET without associated endometriosis. In addition, the first showed a lower elevation of the CA-125 and CA-19-9 tumor markers and more frequently were borderline tumors, but the differences were not statistically significant. There were statistically significant differences in the lower tumor stage of the invasive cases, which in the majority of the OETs with associated endometriosis were type I of the Kurman and Shih's classification [24,25]. They also had higher possibility of optimal cytoreduction, and generally, therefore, they have a better prognosis and greater chances of survival, although they may also more frequently have an associated endometrial carcinoma. Histologically, in the majority of patients with OET and associated endometriosis, the ovarian tumor is of endometrioid (53%) or clear cell (22%) lineage; and in most cases with associated endometriosis with serous or mucinous OET, it was more frequently borderline, which also justifies the better prognosis of OETs associated with endometriosis. From the immunohistochemical point of view, estrogen-receptors are generally positive in associated endometriosis and in endometrioid tumors and negative in the clear cell tumor component of these OETs with associated endometriosis. The determination of p53 protein was generally positive in the clear cell tumor and in associated endometriosis, possibly atypical. Furthermore, two cases with previous histologically confirmed endometriosis were followed-up to assess their evolution to borderline endometrioid carcinoma (after frequent episodes of recurrence) and clear cell carcinoma (after acute inflammatory episode), respectively, showing persisting foci of endometriosis, good postoperative evolution, and being also the clinical and immunohistochemical data concordant with the previously exposed. All these findings could suggest that in certain women with benign endometriosis, inflammatory or other intercurrent factors could induce a variable malignant transformation towards endometrioid or clear cell tumor, depending on such factors and their action, among others, about the hormonal receptors, as indicated by several authors [26–32].

Study limitations and strengths

The main limitation was the retrospective analysis of cases presenting OET and associated endometriosis operated at two different hospitals over a long period of time (1995–2015), in which the criteria for pathologists to categorize borderline tumors

Table 5

Cases of ovarian epithelial tumors (OETs) with histologically confirmed previous endometriosis.

	Case 1 (Endometrioid)	Case 2 (Clear cell)
Years since initial surgical diagnosis	2	9
Primary infertility	Yes	Yes
Histopathology in first surgery	Atypical endometriosis	Endometriosis
Immunohistochemistry in first surgery	ER+, PR+, p53+	Unknown
Subsequent pregnancy	No	Yes, IVF, twin pregnancy
Episode of recurrence	Frequent	No. Stable endometrioma of the right ovary. Last follow-up visit 3 years earlier
CT/Transvaginal ultrasound	Bilateral endometrioma	Heterogeneous mass suspicious of infected endometrioma or abscess or intracystic hemorrhage or hemorrhagic ascites??
Hb	11.8 – 11.9 g/dL	9.7 – 9.3 – 9.1 g/dL
CRP	Unknown	4.16 – 15.8 – 23.6 mg/dL
BSR	10 – 18 mm/h	71 mm/h
CA-125	71 U/mL	489 U/mL
CA-19-9	442 U/mL	104 U/mL
Surgery	Conservative	Radical
Age	32	45
Histopathology	Right ovary: atypical endometriosis + borderline endometrioid tumor Left ovary: endometrial cyst	Undifferentiated clear cell carcinoma in the right ovary + foci of endometriosis throughout the pelvis.
p53 in endometriosis	Negative	Positive (+)
p53 in the tumor	Positive (++)	Positive (+)
ER and PR in endometriosis	Positive (+++)	Positive (++)
ER and PR in the tumor	Positive (+++)	Negative
Aromatase	Positive	Unknown
Recurrence	Yes, after GnRH analogues + anastrozole	No, chemotherapy

ER = estrogen receptor; PR = progesterone receptor; IVF = in vitro fertilization; CT = computed tomography; Hb = hemoglobin; BSR = blood sedimentation rate; CRP = C-reactive protein.

and cases with atypical endometriosis may have differed according to hospital and over time. However, a significant number of cases showing OET and endometriosis were analyzed ($n = 36$); and also there were statistically significant differences with the cases without associated endometriosis ($n = 305$), similar to the results of other studies [7,33,34]. In addition, we also analyzed hormonal receptors and p53 protein expression in endometriosis and endometrioid or clear cell tumors in a small number of cases and described the evolution of two interesting cases with previous histologically confirmed endometriosis that later evolved into a borderline endometrioid tumor and clear cell carcinoma, respectively.

Implications of the findings and place in the context of prior reports

Since Sampson [14], many studies have analyzed the relationship between endometriosis and OETs, with a reported frequency of this association of 8–12% [19,20,35], with a higher incidence in cases of endometrioid and clear cell OET. In addition, endometriosis is considered a risk factor for ovarian carcinoma (RR 4.6; 95% CI, 1.12–12.11) [36], although their association has also been considered a good prognostic factor. Some authors [11,13,20,37] have reported more favorable characteristics in endometriosis-associated OETs, such as a higher proportion of low-grade and Kurman and Shih's type I tumors, less elevated serologic marker values, and higher survival rates; however, the presence of synchronous endometrial cancer besides OET + endometriosis has been also reported [38]. We also observed this in our data, in which 33.3% of endometriosis-associated OETs with the endometrioid subtype also presented synchronous endometrioid endometrial cancer.

Inflammation and the effect of sex steroids are two factors that may play a role in the development of clear cell and endometrioid OET [3,26,27,39,40]. Estrogens appear to be a mitogen for endometriosis and estrogen-receptor positivity is observed in endometrioid OET [3,41]. In addition, a link between inflammation and estrogen production in endometriosis has been observed, describing a positive feedback cycle that favors overexpression of

key steroidogenic genes, most notably aromatase, overexpression of COX2, and continuous local production of estradiol and PGE2 in endometriotic tissue [42–45]. Moreover, most endometrioid carcinomas present functioning stroma and in situ production of estrogens [3,39,46,47]. However, clear cell OETs do not present estrogen-receptor positive expression in the tumor tissue [29]; thus, endometriosis could develop into clear cell (hormone-independent) OET if the hormone receptors are destroyed during malignant transformation [21,48]. Various authors [27,28,30,32] have suggested a dualistic model of progression and development from endometriosis to OET, as follows: 1) endometriosis-associated endometrioid (estrogen- and progesterone-receptor positive), and 2) endometriosis-associated clear cell (estrogen-receptor negative and progesterone-receptor negative, perhaps associated with iron-mediated oxidative stress) [31]. It has also been suggested that the chronic inflammation caused by endometriosis [27], together with genetic changes (mutation of the p53 tumor suppressor gene), may promote progression to an endometriosis-associated OET and p53 mutations are commonly found in endometriosis-associated endometrioid (21–42%) and clear cell (0–27.3%) OETs [39,49]. The results our immunohistochemical studies indicate the same, suggesting that inflammatory processes may destroy the hormone receptors, favoring progression to clear cell OETs. However, in the endometrioid subtype, estrogen-receptor, progesterone-receptor, and p53 expression remain positive in both endometriotic and tumor tissues, suggesting local hormone production in the functioning tumor stroma or stromal hyperplasia in the healthy residual ovary, which could favor malignant transformation. The findings of the two patients with a diagnosis and histological confirmation of endometriosis prior to the development of endometriosis-associated OET also suggest a greater risk of developing ovarian endometrioid (hormone-dependent) carcinoma in cases of endometriosis with frequent episodes of recurrence and a greater increase in CA-19-9. However, Case 2 presented acute inflammatory episodes and hemorrhagic ascites (possibly associated with iron-mediated oxidative stress), with a severely increased blood sedimentation rate, which could promote the downregulation of estrogen-receptors and multifocal

transformation of endometriosis into a hormone-independent clear cell carcinoma. The eventual outcome could be a complete transformation into either endometrioid or clear cell carcinoma (type I tumors). Indeed, Kurman and Shih [25] have pointed out that "type I tumors develop from benign extraovarian lesions that implant on the ovary and which can undergo malignant transformation, whereas many type II carcinomas develop from intraepithelial carcinomas in the fallopian tube and, as a result, disseminate as carcinomas that involve the ovary and extraovarian sites, which probably accounts for their clinically aggressive behavior".

In summary, our findings and review of the literature suggest that patients with surgical findings of OET and associated endometriosis could correspond to an intermediate stage within the possible progression and malignant transformation of endometriosis to endometrioid or clear cell carcinomas or other type I carcinomas without associated endometriosis.

Author contributions

E B-E participated in the surgery and follow-up of patients, performed the review, constructed tables and figures, and wrote the manuscript. M P-A participated in the revision of the cases, helped with the bibliographic search, and reviewed the manuscript. GA G-M reported the results of the histopathological and immunohistochemical studies and reviewed the manuscript. MI A participated in the surgery and follow-up of patients from San Juan University Hospital and reviewed the manuscript. P A performed the surgery and follow-up of patients from San Juan University Hospital, designed the study, constructed tables and figures and reviewed the manuscript. E B-E and P A had full access to all study data and take responsibility for the integrity of the data and the accuracy of the data analysis.

Conflict of interest statement

No conflict of interest.

Acknowledgements and funding

This study was partially supported by the Instituto de Salud Carlos III, Ministry of Health, and FEDER (PI07/0417 and PI10/01815) (Madrid, Spain), inside of the "Plan Nacional de I+D+I 2008-2011" (P. Ación, University Hospital of San Juan, Alicante, Spain).

References

- Ación P. Tumores malignos y borderline del Ovario. Cáncer de Ovario. Otra patología tumoral y cáncer de trompa. In: Ación P, editor. Tratado de Obstetricia y Ginecología. Alicante, Spain: Ediciones Molloy; GINECOLOGÍA; 2004. p. 1237–94.
- Prat J. Ovarian carcinomas: five distinct diseases with different origins, genetic alterations, and clinicopathological features. *Virchows Arch* 2012;460:237–49.
- Wei JJ, William J, Bulun S. Endometriosis and ovarian cancer: a review of clinical, pathologic, and molecular aspects. *Int J Gynecol Pathol* 2011;30:553–68.
- Czernobilsky B, Morris WJ. A histologic study of ovarian endometriosis with emphasis on hyperplastic and atypical changes. *Obstet Gynecol* 1979;53:318–23.
- Fukunaga M, Nomura K, Ishikawa E, Ushigome S. Ovarian atypical endometriosis: its close association with malignant epithelial tumors. *Histopathology* 1997;30:249–55.
- Ogawa S, Kaku T, Amada S, Kobayashi H, Hirakawa T, Ariyoshi K, et al. Ovarian endometriosis associated with ovarian carcinoma: a clinicopathological and immunohistochemical study. *Gynecol Oncol* 2000;77:298–304.
- Akbarzadeh-Jahromi M, Shekarkhar G, Sari Aslani F, Azarpira N, Heidari Esfahani M, Momtahan M. Prevalence of endometriosis in malignant epithelial ovarian tumor. *Arch Iran Med* 2015;18:844–8.
- Boyras G, Selcuk I, Yazicioglu A, Tuncer Zs. Ovarian carcinoma associated with endometriosis. *Eur J Obstet Gynecol Reprod Biol* 2013;170:211–3.
- Schmidt D, Ulrich U. Endometriosis-related ovarian tumors. *Pathologie* 2014;35:348–54.
- Lyttle B, Bernardi L, Pavone ME. Ovarian cancer in endometriosis: clinical and molecular aspects. *Minerva Ginecol* 2014;66:155–64.
- Gates MA, Rosner BA, Hecht JL, Tworoger SS. Risk factors for epithelial ovarian cancer by histologic subtype. *Am J Epidemiol* 2010;171:45–53.
- Melin A, Lundholm C, Malki N, Swahn ML, Sparen P, Bergqvist A. Endometriosis as a prognostic factor for cancer survival. *Int J Cancer* 2011;129:948–55.
- Kumar S, Munkarah A, Arabi H, Bandyopadhyay S, Semaan A, Hayek K, et al. Prognostic analysis of ovarian cancer associated with endometriosis. *Am J Obstet Gynecol* 2011;204(63):e1–7.
- Sampson JA. Endometrial carcinoma of the ovary arising in endometrial tissue in that organ. *Arch Surg* 1925;10:1–72.
- Scott RB. Malignant changes in endometriosis. *Obstet Gynecol* 1953;2:283–9.
- Van Gorp T, Amant F, Neven P, Vergote I. Endometriosis and the development of malignant tumors of the pelvis. A review of literature. *Best Pract Res Clin Obstet Gynaecol* 2004;18:349–71.
- Somigliana E, Vigno P, Parazzini F, Stoppelli S, Giambattista E, Vercellini P. Association between endometriosis and cancer: a comprehensive review and a critical analysis of clinical and epidemiological evidence. *Gynecol Oncol* 2006;101:331–41.
- Nezhat F, Datta MS, Hanson V, Pejovic T, Nezhat C. The relationship of endometriosis and ovarian malignancy: a review. *Fertil Steril* 2008;90:1559–70.
- Pearce CL, Templeman C, Rossing MA, Lee A, Near AM, Webb PM, et al. Association between endometriosis and risk of histological subtypes of ovarian cancer: a pooled analysis of case-control studies. *Lancet Oncol* 2012;13:385–94.
- Wang S, Qiu L, Lang JH, Shen K, Yang JX, Huang HF, et al. Clinical analysis of ovarian epithelial carcinoma with coexisting pelvic endometriosis. *Am J Obstet Gynecol* 2013;208(413):e1–5.
- Wang S, Qiu L, Lang JH, Shen K, Huang HF, Pan LY, et al. Prognostic analysis of endometrioid epithelial ovarian cancer with or without endometriosis: a 12-year cohort study of Chinese patients. *Am J Obstet Gynecol* 2013;209(241):e1–9.
- Prat J. Ovarian tumors of borderline malignancy (tumors of low malignant potential): a critical appraisal. *Adv Anat Pathol* 1999;6:247–74.
- Thomas EJ, Campbell IG. Molecular genetic defects in endometriosis. *Gynecol Obstet Invest* 2000;50(Suppl. 1):44–50.
- Kurman RJ, Shih le M. Pathogenesis of ovarian cancer: lessons from morphology and molecular biology and their clinical implications. *Int J Gynecol Pathol* 2008;27:151–60.
- Kurman RJ, Shih le M. The dualistic model of ovarian carcinogenesis: revisited, revised, and expanded. *Am J Pathol* 2016;186:733–47.
- Attar E, Bulun SE. Aromatase and other steroidogenic genes in endometriosis: translational aspects. *Hum Reprod Update* 2006;12:49–56.
- Tariverdian N, Theoharides TC, Siedentopf F, Gutiérrez G, Jeschke U, Rabinovich GA, et al. Neuroendocrine-immune disequilibrium and endometriosis: an interdisciplinary approach. *Semin Immunopathol* 2007;29:193–210.
- Suzuki F, Akahira J, Miura I, Suzuki T, Ito K, Hayashi S, et al. Loss of estrogen receptor beta isoform expression and its correlation with aberrant DNA methylation of the 5'-untranslated region in human epithelial ovarian carcinoma. *Cancer Sci* 2008;99:2365–72.
- Soslow RA. Histologic subtypes of ovarian carcinoma: an overview. *Int J Gynecol Pathol* 2008;27:161–74.
- Mandai M, Yamaguchi K, Matsumura N, Baba T, Konishi I. Ovarian cancer in endometriosis: molecular biology, pathology, and clinical management. *Int J Clin Oncol* 2009;14:383–91.
- Tanase Y, Yamada Y, Shigetomi H, Kajihara H, Oonogi A, Yoshizawa Y, et al. Modulation of estrogenic action in clear cell carcinoma of the ovary (Review). *Exp Ther Med* 2012;3:18–24.
- Worley MJ, Welch WR, Berkowitz RS, Ng SW. Endometriosis-associated ovarian cancer: a review of pathogenesis. *Int J Mol Sci* 2013;14:5367–79.
- Kadan Y, Fiascone S, McCourt C, Raker C, Granai CO, Steinhoff M, et al. Predictive factors for the presence of malignant transformation of pelvic endometriosis. *Eur J Obstet Gynecol Reprod Biol* 2015;185:23–7.
- Oral E, Aydin O, Kumbak BA, Ilvan S, Yilmaz H, Tustas E, et al. Concomitant endometriosis in malignant and borderline ovarian tumours. *J Obstet Gynaecol* 2018;8(June):1–6, doi:http://dx.doi.org/10.1080/01443615.2018.1441815.
- Dzatic-Smiljkovic O, Vasiljevic M, Djukic M, Vugdalic R, Vugdalic J. Frequency of ovarian endometriosis in epithelial ovarian cancer patients. *Clin Exp Obstet Gynecol* 2011;38:394–8.
- Kok VC, Tsai HJ, Su CF, Lee CK. The Risks for ovarian, endometrial, breast, colorectal, and other cancers in women with newly diagnosed endometriosis or adenomyosis. *Int J Gynecol Cancer* 2015;25:968–76.
- Taniguchi F, Harada T, Kobayashi H, Hayashi K, Momoeda M, Terakawa N. Clinical characteristics of patients in Japan with ovarian cancer presumably arising from ovarian endometrioma. *Gynecol Obstet Invest* 2014;77:104–10.
- Falkenberg SS, Steinhoff MM, Gordinier M, Rappoport S, Gajewski W, Granai CO. Synchronous endometrioid tumors of the ovary and endometrium. A clinicopathologic study of 22 cases. *J Reprod Med* 1996;41:713–8.
- Tokunaga H, Akahira J, Suzuki T, Moriya T, Sasano H, Ito K, et al. Ovarian epithelial carcinoma with estrogen-producing stroma. *Pathol Int* 2007;57:285–90.

- [40] Ness RB. Endometriosis and ovarian cancer: thoughts on shared pathophysiology. *Am J Obstet Gynecol* 2003;189:280–94.
- [41] Lacey Jr JV, Mink PJ, Lubin JH, Sherman ME, Troisi R, Hartge P, et al. Menopausal hormone replacement therapy and risk of ovarian cancer. *JAMA* 2002;288:334–41.
- [42] Noble LS, Takayama K, Zeitoun KM, Putman JM, Johns DA, Hinshelwood MM, et al. Prostaglandin E2 stimulates aromatase expression in endometriosis-derived stromal cells. *J Clin Endocrinol Metab* 1997;82:600–6.
- [43] Tsai SJ, Wu MH, Lin CC, Sun HS, Chen HM. Regulation of steroidogenic acute regulatory protein expression and progesterone production in endometriotic stromal cells. *J Clin Endocrinol Metab* 2001;86:5765–73.
- [44] Bulun SE, Yang S, Fang Z, Gurates B, Tamura M, Zhou J, et al. Role of aromatase in endometrial disease. *J Steroid Biochem Mol Biol* 2001;79:19–25.
- [45] Sun HS, Hsiao KY, Hsu CC, Wu MH, Tsai SJ. Transactivation of steroidogenic acute regulatory protein in human endometriotic stromal cells is mediated by the prostaglandin EP2 receptor. *Endocrinology* 2003;144:3934–42.
- [46] Ación P, Velasco I, Gutiérrez M, Martínez-Beltrán M. Aromatase expression in endometriotic tissues and its relationship to clinical and analytical findings. *Fertil Steril* 2007;88:32–8.
- [47] Hayasaka T, Nakahara K, Kojimahara T, Saito-Sekiguchi M, Motoyama T, Kurachi H. Endometrioid adenocarcinoma with a functioning stroma. *J Obstet Gynaecol Res* 2007;33:381–3.
- [48] Gilks CB. Molecular abnormalities in ovarian cancer subtypes other than high-grade serous carcinoma. *J Oncol* 2010;2010:740968.
- [49] Chuarie-Noack L, Sánchez-Corredor MC, Ramírez-Clavijo S. P53 and its role in the ovarian surface epithelium. A review. *Invest Clin* 2008;49:561–93.