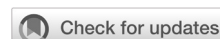

# Clinical profiles and treatment evaluation of tuberculous uveitis in tertiary eye hospital in Jakarta

Ni Made Widya Mahayani<sup>1,2</sup>, Made Susiyanti<sup>2</sup>, Soedarman Sjamsoe<sup>2</sup>, Anna Nur Utami<sup>2</sup>



pISSN: 0853-1773 • eISSN: 2252-8083  
<https://doi.org/10.13181/mji.oa.257609>  
**Med J Indones. 2025;34:83–91**

**Received:** May 30, 2024  
**Accepted:** March 11, 2025  
**Published online:** May 08, 2025

## Authors' affiliations:

<sup>1</sup>Faculty of Medicine, Universitas Mahasaraswati Denpasar, Bali, Indonesia, <sup>2</sup>Jakarta Eye Center (JEC) Eye Hospitals and Clinics, Jakarta, Indonesia

## Corresponding author:

Ni Made Widya Mahayani  
 Faculty of Medicine, Universitas Mahasaraswati Denpasar, Jalan Kamboja No. 11A, Dangin Puri Kangin, North Denpasar, Denpasar, Bali 80233, Indonesia  
 Tel/Fax: +62-361-227019  
**E-mail:** mahayani@unmas.ac.id

## ABSTRACT

**BACKGROUND** Tuberculous uveitis (TU) is the second most common cause of intraocular inflammation in Indonesia. This study aimed to determine the clinical characteristics of patients with TU and the therapies used at Jakarta Eye Center (JEC) Eye Hospitals and Clinics.

**METHODS** This retrospective descriptive study included 265 eyes of 189 patients diagnosed with TU at the JEC Eye Hospital and Clinics between January 2018 and June 2022. This study used secondary data collected by reviewing patient medical records, including clinical profiles and therapeutic characteristics recorded during treatment. Data were analyzed using SPSS software version 24 for Windows.

**RESULTS** Most patients (68.3%) complained of blurry vision, and 99 (52.4%) underwent an interferon-gamma release assay. HIV infection was present in 8.5% of the patients, and 4.8% had diabetes mellitus. Among them, 27 (14.3%) had posterior uveitis, 34 (18.0%) had anterior uveitis, and 127 (67.2%) had panuveitis. The most common feature of inflammation was vitreous opacity. Visual acuity (VA) improved to 0.4 (1.11) after treatment. The most common complication was cataract formation (71 patients). In the group that received combination therapy with systemic steroids and anti-tuberculosis treatment (ATT), 58.7% had a better VA.

**CONCLUSIONS** TU has several clinical manifestations. Treatment with systemic steroids, ATT, or a combination of both can improve VA.

**KEYWORDS** clinical medicine, tuberculosis, uveitis

Uveitis is inflammation of the uveal layer that commonly affects the iris, ciliary body, and choroid. It can involve one or more parts of the uvea and may also affect other eye tissues, such as the retina, optic nerve, and vitreous.<sup>1</sup> Uveitis accounts for 5% of blindness cases, particularly when accompanied by macular edema, ocular hypertonia, and retinal ischemia.<sup>1</sup> The condition can be infectious or non-infectious and may be linked to systemic disorders.<sup>2</sup> In developing countries, uveitis is more common, accounting for 50% of cases, often caused by toxoplasmosis, tuberculosis (TB),

and onchocerciasis, or less frequent by cysticercosis, leprosy, and leptospirosis. In developed countries, such as Europe and the USA, infectious uveitis accounts for only 13–21% of cases, typically caused by herpes simplex, varicella zoster, or toxoplasma.<sup>3</sup>

The prevalence of tuberculous uveitis (TU) varies globally based on a country's endemic status. In endemic countries with high TB infection rates, 9–11% of uveitis cases are caused by TB, compared to 1–6% of cases in non-endemic regions.<sup>4</sup> In Indonesia, a country with a high TB burden from 2016 to 2020, TU is the

second leading cause of intraocular inflammation after toxoplasmosis, accounting for 8% of cases.<sup>5,6</sup> Data from the World Health Organization indicate a lack of definitive data on ocular TB and other uveitis potentials in Indonesia.<sup>6</sup> Among pulmonary TB patients, ocular TB occurs in 1.4–18% of cases, with the highest rate found in HIV-positive cases.<sup>5</sup> Ocular TB has been divided into primary or secondary. In primary cases, the eye is the initial site of microbial invasion (conjunctiva, cornea, and sclera), whereas in secondary cases, it occurs through hematogenous spread, which is believed to cause TU.<sup>7</sup>

Diagnosing TU is challenging for ophthalmologists. A proper history of contact with patients with TB is necessary. Diagnostic examinations for suspected TU include the tuberculin skin test (TST), interferon-gamma release assay (IGRA), chest X-ray, and polymerase chain reaction (PCR).<sup>8</sup> Currently, data on diagnosis and management remain varied and complex, highlighting the need to profile its incidence and address variations and complications of TU. Therefore, this study aimed to determine the clinical characteristics of patients with TU and the therapies used at Jakarta Eye Center (JEC) Eye Hospitals and Clinics.

## METHODS

### Study design and subjects

This retrospective descriptive study utilized the medical records of patients diagnosed with TU who were referred to the Infection and Immunology Division of Ophthalmology at JEC Eye Hospitals and Clinics in Menteng, Kedoya, Tambora, Tanjung Priuk, and Cibubur in Jakarta, Indonesia. The study was conducted from January 2018 to June 2022. Ethical approval (No: KE/FK/0339/EC/2025) was obtained from the Medical and Health Research Ethics Committee of the Faculty of Medicine, Public Health and Nursing, Universitas Gadjah Mada – Dr. Sardjito General Hospital. The need for patient consent and ethical clearance was waived because the study was descriptive, non-interventional, and utilized secondary data from medical records.

This study included patients diagnosed with TU, confirmed TB, probable TB, or possible TB based on the 2020 national guidelines for medical services. Exclusion criteria included patients who did not undergo a follow-up examination at least 1 week

after receiving therapy to assess treatment progress, patients with untraceable medical records, and those with incomplete medical records.

### Data collection

Data for this study were collected from patients' medical records. The relevant variables included age, sex, occupation, supporting examination results, history of systemic steroid use, and history of anti-tuberculosis treatment (ATT). Ophthalmological status was assessed by visual acuity (VA) using the logarithm of the minimum angle of resolution (logMAR), ocular clinical manifestations, eye laterality, complications, relapse, comorbidities, and healing duration.

Best-corrected VA refers to the best possible vision an eye can achieve with corrective lenses, measured during the visit using a projector and expressed in logMAR decimals. The initial VA was measured at the patient's first visit, while the final VA was obtained at follow-up after treatment completion. Eye laterality refers to an inflamed eye divided as unilateral if one eye is involved and bilateral if both eyes are involved. According to the Standardization of Uveitis Nomenclature, the location of inflammation is categorized as anterior uveitis, intermediate uveitis, posterior uveitis, and panuveitis.<sup>9</sup> Clinical improvement, assessed through medical record data and fundus photographs, was indicated by improved visual examination and the absence of inflammation.

Comorbidities, including HIV and diabetes mellitus (DM), were assessed using medical, radiological, and laboratory examination records. Laboratory findings included TST, IGRA, chest radiography, and PCR examination results. Treatment was categorized into three groups: systemic steroid therapy, ATT, and systemic steroid combination therapy with ATT.

The complications recorded in this study included cataracts, secondary glaucoma, macular edema, macular scarring, retinal detachment, and retinal scarring. The healing duration was defined as the time required to undergo therapy until clinical improvements, such as improved vision or no inflammatory reactions as assessed from medical records. The healing group was further categorized as >6 months, 6–12 months, and >12 months. Relapse was defined as the recurrence of clinical symptoms after being declared cured, identified through medical records and showing signs, such as worsening

vision or reappearance of an inflammatory reaction indicative of TB.

The diagnosis of TU was based on the patient history, clinical signs of uveitis, exclusion of other potential causes, serological examination, and chest radiography. Diagnostic criteria included the presence of eye lesions suggestive of TU, confirmed by ophthalmic examination, positive TST and IGRA results, PCR, and chest radiographic changes.

### Statistical analysis

Data were analyzed using SPSS software version 24 (IBM Corp., USA). Collected data were recorded on data collection sheets, grouped, and presented in tabulated form. Descriptive analysis was performed, with results expressed as mean, standard deviation (SD), frequency distribution, and percentage.

## RESULTS

A total of 265 eyes from 189 patients with TU were analyzed in this study. Table 1 shows that 122 patients were female and 67 were male, resulting in a female-to-male ratio of 2:1. Patients' ages ranged from 1 to 88 years. The most common occupation was housewives (35.4%). Most cases were unilateral. Most patients complained of blurred vision. Comorbidity screening revealed that 8.5% of the patients had HIV infection, while 4.8% had a history of DM. The IGRA was the most frequently performed test, with positive results in 98 (51.9%) patients.

Posterior synechiae were the most common features, present in 19% of anterior uveitis cases and 79% of panuveitis cases. Keratic precipitates were observed mostly in the panuveitis group. Iris nodules are often observed in panuveitis, whereas vitreous opacification is the only visible feature of intermediate uveitis. Vitreous opacities (89%) and vasculitis (76%) were observed in the panuveitis group (Table 2).

VA after correction was calculated using logMAR at patient arrival, with most patients (53.6%) having a VA between 0 and 0.5. After therapy, there was an improvement, with 164 patients (61.9%) achieving a VA between 0 and 0.5. Patients with TU received three types of systemic therapy: systemic steroids, ATT, or a combination of systemic steroids and ATT (Table 3). Most patients showed improvement within 6 months. Relapses occurred in three patients: one experienced relapse at 5 months, another at 7

**Table 1.** Demographic and clinical characteristics of patients with TU

Variables	n (%)
Female sex	122 (64.6)
Occupation (n = 189)	
Housewife	67 (35.4)
Employee	49 (25.9)
Student	23 (12.2)
Entrepreneur	18 (9.5)
Government employees	8 (4.2)
Professional	3 (1.6)
Retirement	1 (0.5)
Others*	20 (10.6)
Age (years), mean (SD), min-max (n = 189)	43.03 (15.89), 1-88
<20	15 (7.9)
21-40	70 (37.0)
41-60	77 (40.7)
61-80	26 (13.8)
>80	1 (0.5)
Laterality of the affected eye (n = 189)	
Unilateral	113 (59.8)
Bilateral	76 (40.2)
Symptoms (n = 189)	
Blurred vision	129 (68.3)
Red eye	47 (24.9)
Floaters	12 (6.3)
Dry eye	1 (0.5)
Supporting investigation (n = 189)	
TST (+)	41 (21.7)
IGRA (+)	98 (51.9)
Chest radiography (+)	20 (10.6)
PCR (+)	1 (0.5)
TST & IGRA (+)	2 (1.1)
TST & chest radiography (+)	15 (7.9)
IGRA & chest radiography (+)	8 (4.2)
TST, IGRA, & chest radiography (+)	1 (0.5)
Without supporting examination	3 (1.6)
Comorbidities (n = 25)	
HIV	16 (8.5)
DM	9 (4.8)
Diagnosis (n = 189)	
Anterior uveitis	34 (18.0)
Intermediate uveitis	1 (0.5)
Posterior uveitis	27 (14.3)
Panuveitis	127 (67.2)

DM=diabetes mellitus; IGRA=interferon-gamma release assay; PCR=polymerase chain reaction; SD=standard deviation; TST=tuberculin skin test; TU=tuberculous uveitis

\*Others are freelancers, workers, unemployed, and self-employed

**Table 2.** Eye manifestation

Variables	Anterior uveitis, n (%)	Intermediate uveitis, n (%)	Posterior uveitis, n (%)	Panuveitis, n (%)
Anterior segment				
Anterior synechia	1 (17)	-	-	5 (83)
Posterior synechia	15 (19)	-	1 (1)	62 (79)
Keratic precipitate	14 (18)	-	2 (3)	62 (79)
Iris nodule	-	-	-	7 (100)
Corneal edema	3 (75)	-	-	1 (25)
Hypopyon	1 (50)	-	-	1 (50)
Posterior segment				
Neuroretinitis	-	-	3 (43)	4 (57)
Vitreous haze & hemorrhage	-	1 (1)	10 (9)	93 (89)
Choroiditis, choroidal infiltrate, tubercle, & tuberculoma	-	-	7 (37)	12 (63)
Retinal vasculitis	-	-	16 (23)*	52 (76)*

\*A case of uveitis with multiple clinical manifestations

months, and the third at 14 months after treatment. The most common complication in patients with TU was cataracts, which was observed in 71 eyes (58.2%). Among patients with complicated cataracts, 23 underwent phacoemulsification surgery to improve VA. For glaucoma, five patients underwent surgery, including two with a glaucoma drainage device, two who underwent laser peripheral iridotomy, and one who underwent iridectomy. Additionally, five patients with macular edema received intravitreal injections, and two underwent vitrectomy (Table 3).

The data were arranged in a scatter diagram to compare the VA before and after treatment, allowing for an assessment of the improvement in VA (Figure 1). Most patients showed VA improvement after treatment, with most data points clustered near the x-axis.

Table 4 shows the ATT initiation in patients with TU. In anterior uveitis, most patients had positive IGRA results, with three patients not receiving ATT. All patients with intermediate uveitis had positive TST results and underwent ATT. In posterior uveitis, 44% of the patients achieved IGRA results, with one patient not receiving ATT. For panuveitis, 50% of the patients had positive IGRA results, and one did not receive ATT.

Evaluation of the clinical improvement duration based on treatment is shown in Table 5. The combination of systemic steroids and ATT resulted in clinical improvement within 6 months (47%). Patients

who received steroids alone experienced faster clinical improvement; however, this percentage may not accurately represent the real situation, as this group comprised only two patients.

## DISCUSSION

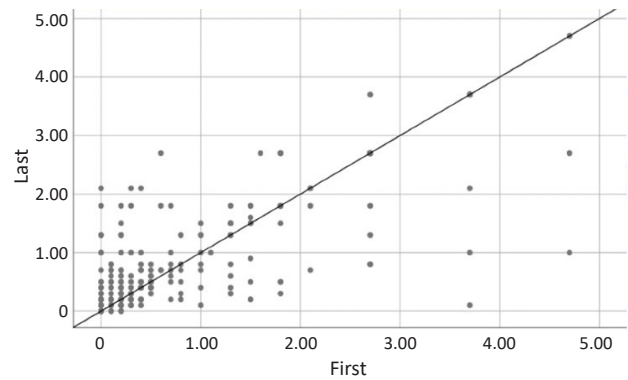
Our study found that TU was more common in women. This finding aligns with La Cava et al,<sup>4</sup> who reported a 57.1% incidence of TU in women, while Llorenç et al<sup>10</sup> in Spain reported 54.87% of uveitis cases in men. Similarly, Fernandes et al<sup>11</sup> found an increased likelihood of *Mycobacterium* infection in men because they had more contact with the public, thereby increasing the risk of TB infection. The correlation between sex hormone levels and microbial exposure was also investigated. Hormonal, chromosomal, and environmental factors influence immune cell activation and play important roles in infectious and autoimmune diseases.<sup>2</sup>

The incidence of TB is higher in densely populated environments due to airborne transmission. In our study, housewives accounted for 35.4% of patients with TB. Employment status integrating with people's values will shape community knowledge, behavior, and attitudes toward certain diseases. Data suggest that employment status is a key factor in health promotion, as it impacts patients' knowledge of TB, while the latest education degree increases their perception of TB.<sup>12</sup> Alfaray et al<sup>13</sup> reported a TB incidence rate of

**Table 3.** VA (logMAR), TU treatment, and complications

Variables	n (%)
VA first visit, mean (SD) (n = 265)	0.8 (1.16)
0–0.5	142 (53.6)
0.6–1	45 (17.0)
1.1–2.0	41 (15.5)
2.1–4.7	37 (14.0)
VA last visit, mean (SD) (n = 265)	0.4 (1.11)
0–0.5	164 (61.9)
0.6–1	28 (10.6)
1.1–2.0	33 (12.5)
2.1–4.7	40 (15.1)
Medication (n = 189)	
Systemic steroids	2 (1.1)
ATT	49 (25.9)
Combined therapy	134 (70.9)
No systemic therapy	4 (2.1)
Duration of healing (months), mean (SD), median (min–max)	7.54 (5.72), 6 (1–36)
Time duration in heal (within group) (months) (n = 189)	
<6	98 (51.9)
6–12	64 (33.9)
>12	27 (14.3)
Time duration in relapse (within group) (months) (n = 3)	
<6	1 (33.3)
6–12	1 (33.3)
>12	1 (33.3)
Complication (n = 122)	
Complicated cataract	71 (58.2)
Corneal scar	17 (13.9)
Glaucoma	12 (9.8)
Retinal scar	9 (7.4)
Retinal detachment	7 (5.7)
Macular edema	6 (4.9)
Treatment after complication (n = 35)	
Phacoemulsification	23 (32.3)
Glaucoma operation	5 (41.7)
Intravitreal injection	5 (83.3)
Vitrectomy	2 (28.6)

ATT=anti-tuberculosis treatment; logMAR=logarithm of the minimum angle of resolution; SD=standard deviation; TU=tuberculous uveitis; VA=visual acuity

**Figure 1.** The scatter diagram of visual acuity (VA) first visit and last visit

9 per 100,000 among workers compared to 31 per 100,000 among unemployed individuals. Homemakers tended to have lower education levels, less access to information and knowledge about TB, and less exposure to social interactions.<sup>10</sup>

Our study found that TU was most prevalent in the 41–60 year age group, followed by the 21–40 year age group. Similarly, Nora et al<sup>12</sup> found that the highest incidence of ocular TB was in the 25–45 years age group (66.7%). Llorenç et al<sup>10</sup> found the median age for TU to be 40 years, while La Cava et al<sup>4</sup> reported a mean age for TU is 48.79 (16.26). The higher prevalence in productive age may be attributed to their high mobility and increasing TB exposure.<sup>11</sup> Cases of uveitis over the age of 60 years are rare, and Masquerade syndrome, especially intraocular lymphoma, must be immediately considered.<sup>3</sup>

This study found that unilateral diseases were more common than bilateral diseases. This is contrary to the findings of Alli et al<sup>14</sup> which found that bilateral cases (76%) were more prevalent than unilateral cases. Moreover, Ang et al<sup>15</sup> demonstrated a comparable incidence of unilateral and bilateral cases, whereas Tsirouki et al<sup>2</sup> highlighted that unilateral and bilateral cases had similar incidences. There is currently no theoretical basis for the predominance of unilateral and bilateral TU.

The clinical symptoms experienced by most patients in this study were blurred vision, followed by complaints of red eyes, floaters, and dry eyes. Patients with acute anterior uveitis usually present with ocular redness, pain, and prominent photophobia. Vision is usually slightly impaired, whereas chronic conditions are generally asymptomatic and can only be detected during screening or when the vision is impaired. Intermediate uveitis usually presents as floats and can



**Table 4.** Initiation of ATT in patients with TU

	Test				n (%)	ATT	
	TST	IGRA	Radiology	PCR		Yes	No
Anterior uveitis	+	-	-	-	6 (18)	6 (100)	-
	+	-	+	-	1 (3)	1 (100)	-
	-	+	+	-	2 (6)	2 (100)	-
	-	+	-	-	23 (68)	20 (87)	3 (13)
	-	-	+	-	2 (6)	2 (100)	-
Intermediate uveitis	+	-	-	-	1 (100)	1 (100)	-
Posterior uveitis	+	-	-	-	7 (26)	7 (100)	-
	+	-	+	-	3 (11)	3 (100)	-
	-	+	+	-	2 (7)	2 (100)	-
	-	+	-	-	12 (44)	11 (92)	1 (8)
	-	-	+	-	3 (11)	3 (100)	-
Panuveitis	+	+	+	-	1 (1)	1 (100)	-
	+	+	-	-	2 (2)	2 (100)	-
	+	-	+	-	11 (9)	1 (100)	-
	+	-	-	-	27 (21)	27 (100)	-
	-	+	+	-	4 (3)	4 (100)	-
	-	+	-	-	63 (50)	62 (98)	1 (2)
	-	-	+	-	15 (12)	1 (100)	-
	-	-	-	+	1 (1)	1 (100)	-
	-	-	-	-	3 (2)	3 (100)	-

ATT=anti-tuberculosis treatment; IGRA=interferon-gamma release assay; PCR=polymerase chain reaction; TST=tuberculin skin test; TU=tuberculous uveitis

**Table 5.** VA after therapies and evaluation of clinical improvement based on therapies

Therapy	VA, n (%)				Total	Duration of clinical improvement (months), n (%)			Total
	0–0.5	0.6–1	1.1–2.0	2.1–4.7		<6	6–2	>12	
Medication									
Systemic steroid	2 (100)	-	-	-	2	1 (50)	1 (50)	0 (0)	2
ATT	26 (53)	7 (14)	6 (12)	10 (20)	49	29 (59)	17 (35)	3 (6)	49
Systemic steroid + ATT	56 (42)	21 (16)	27 (20)	30 (22)	134	63 (47)	44 (33)	27 (20)	134
Without systemic therapy	4 (100)	-	-	-	4	4 (100)	-	-	4

ATT=anti-tuberculosis treatment; VA=visual acuity

cause various degrees of visual impairment; however, mild cases may be asymptomatic. Posterior uveitis may also present as floaters, scotomas (blind spots), or central vision. Patients with panuveitis may present with all these symptoms.<sup>16,17</sup>

This study reported that panuveitis was the most common condition in patients. In contrast, La Cava et al<sup>4</sup> observed that 43% of cases were anterior uveitis, while Câmara et al<sup>18</sup> also found it to be the most

common type of inflammation (35%) in Brazil. The high prevalence of panuveitis in this study reflects a similar pattern in referral hospitals in South Africa, where most cases of anterior and intermediate uveitis are treated in an outpatient setting and are rarely referred to a larger hospital.<sup>11</sup>

In this study, three patients experienced relapse after treatment. Ang et al<sup>19</sup> found that patients who received ATT for more than 9 months (median [range]:

10 [9–15] months) had a significantly lower chance of relapse than those who were not treated with ATT. Another study by Tomkins-Netzer et al<sup>20</sup> reported that 68 eyes (34.9%) had TU recurrence. They found that patients who received ATT were less likely to have a recurrence than those who did not receive ATT. In this study, the use of ATT was associated with the recurrence of ocular inflammation ( $p = 0.006$ ), whereas factors such as age at presentation, endemic region, non-anterior uveitis, and systemic steroid use had a statistically insignificant effect.

Patients in this study who experienced relapse were administered systemic steroid drugs to relieve the inflammatory process that occurred without ATT administration. Relapse of uveitis can be caused by several factors, such as inadequate treatment after 6 months or drug-resistant organisms, thus requiring longer treatment or a combination of drugs. Other possibilities include infection not caused by mycobacteria, a positive IGRA test indicating latent TB, a previous infection not associated with the current uveitis, or a false-positive IGRA test, which may be caused by factors such as commensal mycobacteria or HIV infection.<sup>21</sup>

In this study, IGRA yielded the best results. A retrospective cohort study by Ang et al<sup>19</sup> found that IGRA was more specific but less sensitive than the TST for diagnosing TU. These findings suggest that both tests should be interpreted simultaneously. Currently, the diagnosis of TU can be made through positive TST, positive IGRA test, mycobacterial cultures or PCR ophthalmic fluid tests, and the presence of lesions on chest radiographs.<sup>22</sup> The IGRA is a blood-based diagnostic test that detects active and latent mycobacterial infection in the body with high specificity and sensitivity. While it is insufficient for a definitive diagnosis, its diagnostic accuracy increases when associated with clinical signs or a positive TST.<sup>23</sup> The IGRA test can differentiate exposure of *Mycobacterium tuberculosis* from the Bacille Calmette-Guérin vaccine strain but cannot differentiate between latent and active TB infection. Quantitative PCR provides a more definitive diagnosis and appropriate therapy, but is expensive.<sup>22</sup> In this study, TST was mostly performed on patients at the clinic due to its lower cost than IGRA. Most patients had normal chest results and consistent TU occurred, even without lung infection.

After screening for comorbidities, 8.5% of the patients were infected with HIV, and 4.8% had a history

of DM. In Brazil, the incidence of TB remains high when accompanied by DM, tumors, alcohol consumption, and HIV.<sup>22</sup> People with poor immune conditions are more susceptible to active TB than those with normal immune system conditions. Approximately 50–60% of HIV-positive individuals infected with TB develop active disease. It can also occur in other medical conditions in which the immune system is suppressed, such as silicosis, DM, and the long-term use of corticosteroids or other immunosuppressant drugs.<sup>5</sup>

In this study, posterior synechiae were the most common presentation of anterior uveitis and panuveitis, whereas vitreous opacities were observed in panuveitis. Moreover, panuveitis presents with keratic precipitates and iris nodules. Tuberculous anterior uveitis is often accompanied by other ocular manifestations of chronic granulomatous inflammation, such as mutton-fat keratic precipitates in the posterior aspect of the cornea and Koeppe and Busacca nodules on the iris. Non-granulomatous uveitis also occurs in TB, usually manifesting as small white keratic precipitates without iris nodules. Both granulomatous and non-granulomatous inflammation affect the anterior segment, with inflammatory cells and flares visible in the anterior chamber. Inflammation mainly involves the posterior uvea or choroid, leading to various clinical presentations including choroidal tuberculoma, choroidal tubercles, multifocal choroiditis, and serpiginous-like choroiditis.

This study found that patients experienced an improvement in VA after receiving treatment. This is strengthened by the trend line, which is more inclined towards the horizontal axis, indicating an improvement in VA. This demonstrated a significant change in the initial and final VA scores, highlighting the effectiveness of the treatment. Most patients in this study received a combination of systemic steroids and ATT, which has been shown to be particularly effective in improving VA outcomes. Putera et al<sup>24</sup> reported that this combination was necessary to achieve optimal treatment outcomes. Nora et al<sup>12</sup> demonstrated that steroids without ATT were associated with decreased VA and frequent relapses. The limited improvement in VA in patients treated with ATT may be due to a selection bias, as these patients had a lower initial VA. Bitzler et al<sup>25</sup> stated that treating TU with a combination of ATT and corticosteroids significantly enhanced the resolution of inflammation. The odds ratio for inflammatory recurrence was 0.33 in patients treated with a

combination of ATT and corticosteroids compared to those who did not receive ATT.

A collaborative ocular tuberculosis study (COTS) was used to evaluate the role of ATT in various types of TU. However, the use of ATT for the treatment of TU remains controversial. COTS found that adding ATT did not have a significant effect, while other studies reached a moderate consensus to start ATT. In cases of intermediate, posterior, or panuveitis, ATT may be effective, considering the presence of positive immunological and radiological signs, regardless of whether the area is endemic. The COTS also established guidelines for using ATT in patients with TB based on evidence and expert opinions. The COTS study is also useful for evaluating the role of the ATT in various types of TU.<sup>26</sup>

Patients received ATT based on the Centers for Disease Control and Prevention guidelines for at least 6 months. This included an initial 2-months phase with four drugs: isoniazid, rifampicin, pyrazinamide, and ethambutol, followed by a 4-months continuation phase with rifampin and isoniazid. Systemic corticosteroids were added if inflammatory activity increased after ATT. In patients with posterior inflammation for whom ATT is not indicated, oral prednisone is used, starting at a dose of 1 mg/kg and tapered slowly.<sup>19</sup> Systemic corticosteroids could theoretically treat the inflammation associated with the lesion, and starting ATT without corticosteroids may worsen the initial lesion because of a paradoxical reaction. Thus, the concomitant use of corticosteroids is recommended to restrict progressive inflammation and subsequent complications.<sup>22</sup>

A limitation of this study is its retrospective design, focusing on cases of TU in patients seeking treatment at the JEC Eye Hospitals and Clinics, where TU is the most common infectious uveitis in Indonesia. Studies have shown that active pulmonary TB remains a frequent cause of uveitis in Indonesia (8% of all uveitis cases) and ranks second after toxoplasmosis among the infectious causes of uveitis.<sup>27</sup> Patients typically present with vision problems and complications. This late presentation limits the visual prognosis and precludes the recognition of typical clinical manifestations, potentially obscuring the accurate diagnosis of uveitis. Furthermore, the small sample size and the limited follow-up duration may have affected our results.

Future researchers should conduct prospective studies with real-time data to provide more accurate

information regarding the progression and treatment response in this condition. Additionally, multicenter studies involving several hospitals or clinics across different regions will expand the sample size and enhance the generalizability of the findings. Longer follow-up periods are essential to evaluate the long-term effects of treatment and any potential complications that may arise, thereby providing a more comprehensive understanding of the management of TU.

In conclusion, most cases of TU at JEC Eye Hospitals and Clinics were found in women, with the highest age range of 41–60 years, mean (SD) age of 43.03 (15.89) and mostly working as housewives. Most of the patients had unilateral uveitis, with blurry vision being the most common complaint. The most commonly used supporting examination was the IGRA. Panuveitis was the most common diagnosis, and primary treatment involved a combination of systemic steroids and ATT.

#### Conflict of Interest

The authors affirm no conflict of interest in this study.

#### Acknowledgment

None.

#### Funding Sources

None.

## REFERENCES

1. Sève P, Cacoub P, Bodaghi B, Trad S, Sellam J, Bellocq D, et al. Uveitis: diagnostic work-up. A literature review and recommendations from an expert committee. *Autoimmun Rev*. 2017;16(12):1254–64.
2. Tsiroki T, Dastiridou A, Symeonidis C, Tounakaki O, Brazitikou I, Kalogeropoulos C, et al. A focus on the epidemiology of uveitis. *Ocul Immunol Inflamm*. 2018;26(1):2–16.
3. Krishna U, Ajanaku D, Denniston AK, Gkika T. Uveitis: a sight-threatening disease which can impact all systems. *Postgrad Med J*. 2017;93(1106):766–73.
4. La Cava M, Bruscolini A, Sacchetti M, Pirraglia MP, Moramarco A, Marengo M, et al. Clinical and epidemiological study on tubercular uveitis in a tertiary eye care centre in Italy. *J Ophthalmol*. 2020;2020:4701820.
5. Ministry of Health of the Republic of Indonesia. [National guidelines for medical services in tuberculosis management]. Jakarta: Ministry of Health of the Republic of Indonesia; 2020. Indonesian.
6. World Health Organization (WHO). Global tuberculosis programme: TB reports [Internet]. Geneva: World Health Organization (WHO); 2021 [cited 2024 Jan 12]. Available from: <https://www.who.int/teams/global-tuberculosis-programme/tb-reports>.
7. Gogia V, Venkatesh P, Garg SP, Takkar B, Sheemar A. Patterns of uveitis in patients with proven systemic (pulmonary and extrapulmonary) tuberculosis. *Int Ophthalmol*. 2019;39(8):1665–7.
8. Shah JS, Shetty N, Shah SK, Shah NK. Tubercular uveitis with ocular manifestation as the first presentation of tuberculosis: a



- case series. *J Clin Diagnostic Res.* 2016;10(3):NR01–3.
9. Jabs DA, Nussenblatt RB, Rosenbaum JT; Standardization of Uveitis Nomenclature (SUN) Working Group. Standardization of uveitis nomenclature for reporting clinical data. Results of the first international workshop. *Am J Ophthalmol.* 2005;140(3):509–16.
  10. Llorenç V, Benejam G, Mesquida M, Sainz de la Maza M, Molins B, Alba C, et al. Antituberculous treatment itself might prevent visual impairment in presumed tuberculosis-related uveitis. *Ocul Immunol Inflamm.* 2020;28(1):103–10.
  11. Fernandes P, Ma Y, Gaedert M, Tsacogianis T, Marques-Rodrigues P, Fregona G, et al. Sex and age differences in *Mycobacterium tuberculosis* infection in Brazil. *Epidemiol Infect.* 2018;146(12):1503–10.
  12. Nora RL, Sitompul R, Susiyanti M, Edwar L, Sjamsoe S. Clinical characteristic and therapy results of presumed ocular tuberculosis and their relation to HIV status. *Med J Indones.* 2012;21(4):214–9.
  13. Alfary RI, Mochtar NM, Zharfan RS, Subkhan M. Occupational status and educational stage as a valuable factors affecting knowledge and perception level of Indonesian tuberculosis patient. *Med Leg Updat.* 2021;21(2):1000–8.
  14. Alli HD, Ally N, Mayet I, Joseph L, Omar S, Madhi S. Treatment outcome of tubercular uveitis in a high TB and HIV setting: a prospective cohort study. *Clin Ophthalmol.* 2021;15:4839–46.
  15. Ang M, Hedayatfar A, Wong W, Chee SP. Duration of anti-tubercular therapy in uveitis associated with latent tuberculosis: a case-control study. *Br J Ophthalmol.* 2012;96(3):332–6.
  16. Semilan HM, Abugad HA, Mashat HM, Abdel Wahab MM. Epidemiology of tuberculosis among different occupational groups in Makkah region, Saudi Arabia. *Sci Rep.* 2021;11(1):12764.
  17. Puzyreva LV, Safonov AD, Lebedev OI, Mordyk AV. [Ocular tuberculosis]. *Vestn Oftalmol.* 2016;132(3):103–7. Russian.
  18. Câmara SN, Barbosa Júnior JB, Barbosa KC. Anterior uveitis as a manifestation of ocular tuberculosis. *Rev Bras Oftalmol.* 2019;78(3):195–8.
  19. Ang M, Hedayatfar A, Zhang R, Chee SP. Clinical signs of uveitis associated with latent tuberculosis. *Clin Exp Ophthalmol.* 2012;40(7):689–96.
  20. Tomkins-Netzer O, Leong BC, Zhang X, Lightman S, McCluskey PJ; Sydney-London Latent Ocular TB Study Group. Effect of antituberculous therapy on uveitis associated with latent tuberculosis. *Am J Ophthalmol.* 2018;190:164–70.
  21. Krassas N, Wells J, Bell C, Woodhead M, Jones N. Presumed tuberculosis-associated uveitis: rising incidence and widening criteria for diagnosis in a non-endemic area. *Eye (Lond).* 2018;32(1):87–92.
  22. Setyaningrum R, Zubaidah T, Anhar VY. Correlation between gender, age, education level, and working status with anti-tuberculosis drug uses (OATS) in patients with lung TB in Indonesia 2013. *Int J Chem Mater Sci.* 2018;1(1):7–13.
  23. Koller K, Ricci LH, Lindoso JA, Lindoso AA, Muccioli C. Clinical description and treatment of patients with presumed ocular tuberculosis in São Paulo, Brazil. *Rev Bras Oftalmol.* 2019;78(6):384–8.
  24. Putera I, Schrijver B, Ten Berge JC, Gupta V, La Distia Nora R, Agrawal R, et al. The immune response in tubercular uveitis and its implications for treatment: from anti-tubercular treatment to host-directed therapies. *Prog Retin Eye Res.* 2023;95:101189.
  25. Betzler BK, Putera I, Testi I, La Distia Nora R, Kempen J, Kon OM, et al. Anti-tubercular therapy in the treatment of tubercular uveitis: a systematic review and meta-analysis. *Surv Ophthalmol.* 2023;68(2):241–56.
  26. Agrawal R, Testi I, Bodaghi B, Barisani-Asenbauer T, McCluskey P, Agarwal A, et al. Collaborative ocular tuberculosis study consensus guidelines on the management of tubercular uveitis—report 2: guidelines for initiating antitubercular therapy in anterior uveitis, intermediate uveitis, panuveitis, and retinal vasculitis. *Ophthalmology.* 2021;128(2):277–87.
  27. La Distia Nora R, Sitompul R, Bakker M, Susiyanti M, Edwar L, Sjamsoe S, et al. Tuberculosis and other causes of uveitis in Indonesia. *Eye (Lond).* 2018;32(3):546–54.