

A successful separation of omphalopagus twins during COVID-19 pandemic: A case report

Monica Bellynda¹ , Muhammad David Perdana Putra¹ , Suwardi Suwardi² , Nunik Agustriani², Faizal Muhammad³ 

¹Surgery Department, Dr. Moewardi General Hospital, Faculty of Medicine, Sebelas Maret University, Surakarta, Indonesia

²Pediatric Surgery Department, Dr. Moewardi General Hospital, Faculty of Medicine, Sebelas Maret University, Surakarta, Indonesia

³Surgery Department, UNS Hospital, Faculty of Medicine, Sebelas Maret University, Surakarta, Indonesia

Abstract

Background: Omphalopagus is a rare condition involving digestive system and abdominal wall fusion. This study reports an omphalopagus case during the early phase of the coronavirus disease 2019 (COVID-19) pandemic in Indonesia.

Case: Male conjoined twins, aged 14 months, were diagnosed with omphalopagus and several organ failures. We performed separation surgery of the omphalopagus with primary closure and post-surgical care for fifteen days. The early surgery was preferable in this case due to life-threatening issues of COVID-19, despite omphalopagus separation may cause post-surgical complications. Furthermore, the emerging pandemic conditions also required a more stringent procedure to avoid the risk of viral spread.

Conclusion: We conclude that, in the lack of evidence-based instruction for hospital care during the early phase of COVID-19 in Indonesia, life-saving surgical considerations from death due to complications of COVID-19 infection and acute respiratory distress syndrome must be performed and prioritized. However, potential omphalopagus complications must be evaluated.

Keywords: congenital abnormalities; conjoined twins; COVID-19; omphalopagus

Introduction

Conjoined twins are a rare embryologic developmental disorder of uncertain etiology. Its prevalence, although variable, has been estimated to be 1 in 50,000 to 1 in 100,000 births (Mutchinick et al., 2011). However, the latest data showed that conjoined twins occur in one per 250,000 births (Zainuddin et al., 2021). The separation of conjoined twins presents a unique challenge due to its rarity (Poudel et al., 2022). Although omphalopagus twins have the best survival chances, adequate pre-operative planning is required (Van Klei et al., 2012). In addition, radiological investigations must evaluate any presence of shared organs, anomalies, and cross circulation (Sultan & Tawfeek, 2016).

Lung infection and bacterial septicemia due to Methicillin-Resistant Staphylococcus Aureus (MRSA) contribute to higher mortality, especially following the thoracopagus and omphalopagus separation (Sultan & Tawfeek, 2016). Several COVID-19 patients are high-risk to develop pulmonary super-infection or bacterial co-infection causing unfavorable outcome (Bassetti et al., 2022). Furthermore, surgical pediatric nursing roles become challenging in socio-psychological emotional management



OPEN ACCESS

Jurnal Keperawatan Padjadjaran (JKP)

Volume 11(1), 65-70
© The Author(s) 2023
<http://dx.doi.org/10.24198/jkp.v11i1.2129>

Article Info

Received : October 04, 2022
Revised : November 01, 2022
Accepted : November 10, 2022
Published : April 27, 2023

Corresponding author

Monica Bellynda
Surgery Department, Dr. Moewardi General Hospital, Faculty of Medicine, Sebelas Maret University, Surakarta, Indonesia 57126, Jalan Ir. Sutami 36 Kentingan, Jebres, Surakarta, Jawa Tengah, Indonesia 57126, Phone: (+62) 812-8824-0912, E-mail: bellyndaamonica@gmail.com

Citation

Bellynda, M., Putra, M.D.P., Suwardi, S., Agustriani, A., Muhammad, F. (2023). A Successful Separation of Omphalopagus Twins during COVID-19 Pandemic: A Case Report. *Jurnal Keperawatan Padjadjaran*, 11(1), 65-70. <http://dx.doi.org/10.24198/jkp.v11i1.2129>

Website

<http://jkp.fkep.unpad.ac.id/index.php/jkp>

This is an **Open Access** article distributed under the terms of the [Creative Commons Attribution-NonCommercial 4.0 International License](https://creativecommons.org/licenses/by-nc/4.0/).

E-ISSN: 2442-7276
P-ISSN: 2338-5324

Bellynda, M., et al. (2023)

(Yosep et al., 2022). Hence, this study reports omphalopagus twins of 14-month-old males with high risk pulmonary infection co-infection during the early COVID-19 global pandemic.

Case Presentation

A Male conjoined twins named Ba and Be, aged 14 months, were delivered through the C-section procedures from G3P2A0 at 36 weeks of pregnancy. They were fully vaccinated based on Indonesian Pediatric Society recommendation (Tan et al., 2020). Their bodies were fused from epigastrium to umbilicus with one umbilical cord. Ba's distal extremities did not appear blue with 98% pulse oximetry, while Be's distal extremities were cyanotic with 83% pulse oximetry (Figure 1). Hematological work-up showed hemoglobin levels of 13.9 g% and 9.1 g% for baby Ba and Be, respectively, with normal biochemistry parameters. These results were related to the history of Be's Pentalogy of Fallot (POF).

The physical examination showed a compos mentis consciousness, normal vital signs, ± 9.1 kg bodyweight for each baby, 82 cm and 80 cm height for baby Ba and Be, respectively. Ba showed a normal-regular first and second heart sound, while Be showed grade V of continuous murmurs with maximum punctum in intercostal space III-IV of left midclavicular line, without gallop rhythm. The initial babygram found intestinal system interconnection in the anterior abdominal. This finding confirmed the omphalopagus diagnosis.

Be's echocardiography showed POF. The abdominal contrast CT-scan showed a fused liver with Be's vascularization directly inside Ba's liver. Be's intestine was partially merged with Ba's vascularization with splenomegaly (Figure 2). The contrast-filled oesophagography showed that Be's jejunum had entered Ba's abdominal space through an abdominal defect. The percutaneous

transhepatic biliary drainage showed proximal common bile duct obstruction in Be. In addition, the magnetic resonance cholangiopancreatography of the biliary systems showed that the intrahepatic bile duct of Be had entered Ba's liver.

This case was late for omphalopagus separation because their mother lived in a rural area without a surgery-capable referral hospital. Moreover, the scheduled separation was postponed from late March to September 2020 due to the uncertainty of healthcare during the early months of the COVID-19 pandemic in Indonesia. Fortunately, there were no partial membranous ruptures and pulled vena cava during the C-section labor. We assessed this case with POF, moderate pulmonary valve stenosis, failure to thrive, and hepatic-intestinal omphalopagus. We planned surgical separation with primary closure (Figure 3). The SARS-CoV-2 polymerase chain reaction (PCR) test was conducted one day before the surgery. It showed a negative result.

Intervention or Clinical Examination

The patients' mother gave written consent regarding the entire medical care and case presentation for the medical publication purpose. The written consent is available for review by the editorial board of this journal. The anesthesiologists considered inducing Be before Ba due to Be's cyanotic congenital heart disease (CHD) in one omphalopagus separation surgical table. Thus, the surgeons also prepared two surgery tables for the primary abdominal closure following omphalopagus separation

An incision was made in the marked skin, connective tissue, and muscles beneath (Figure 3). The fused portion of the liver was separated by harmonic scalpel instead of an electrosurgical instrument. The remaining fused parts were cut and resutured. The malrotated-intestines were corrected. We found unpredicted intraoperative findings included minor diaphragm defect and

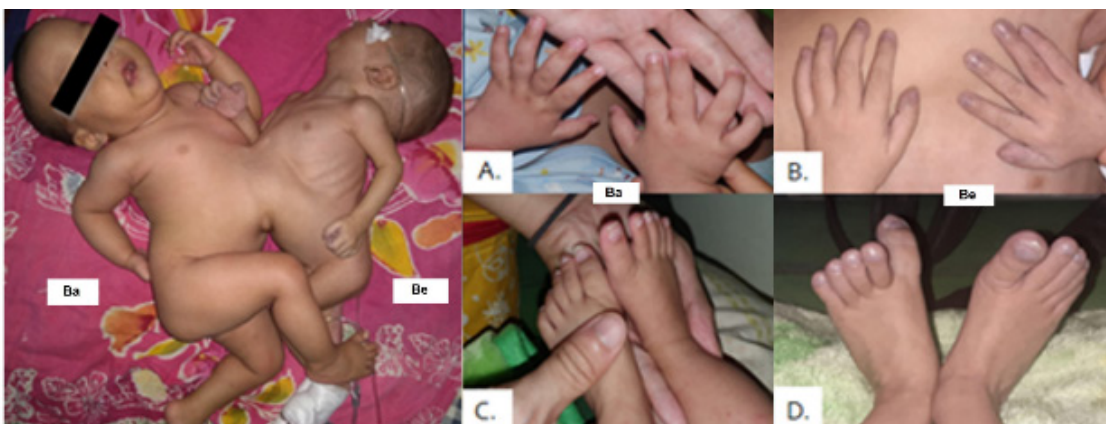

Figure 1. Omphalopagus or conjoined twins in September 2020. (A, C) Baby Ba's hands and feet. (B, D) Baby Be's hands and feet.

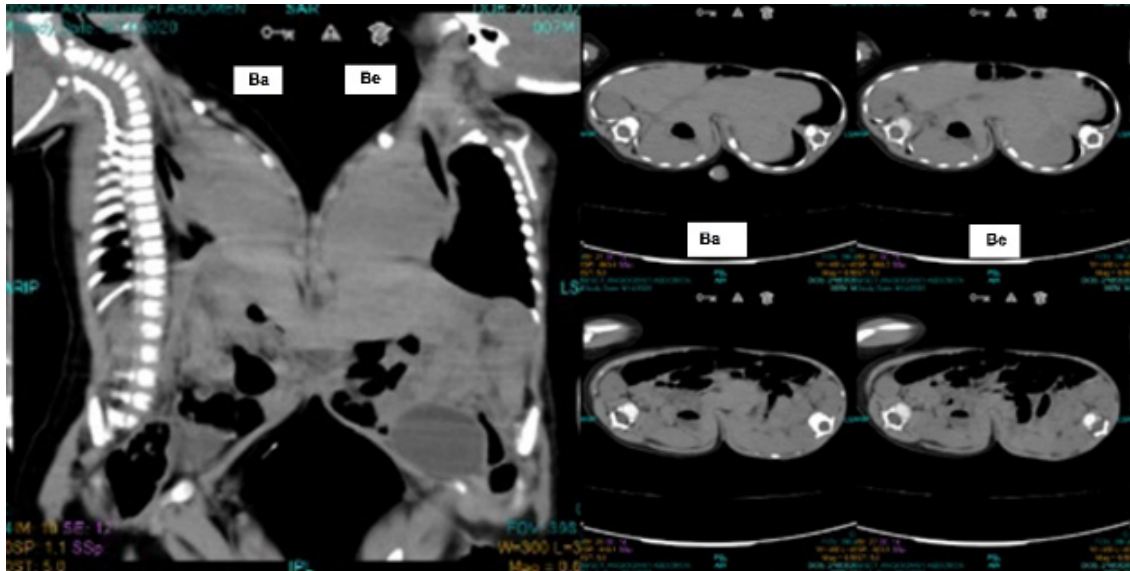


Figure 2. Pre-operative abdominal computerized tomography scan with contrast.

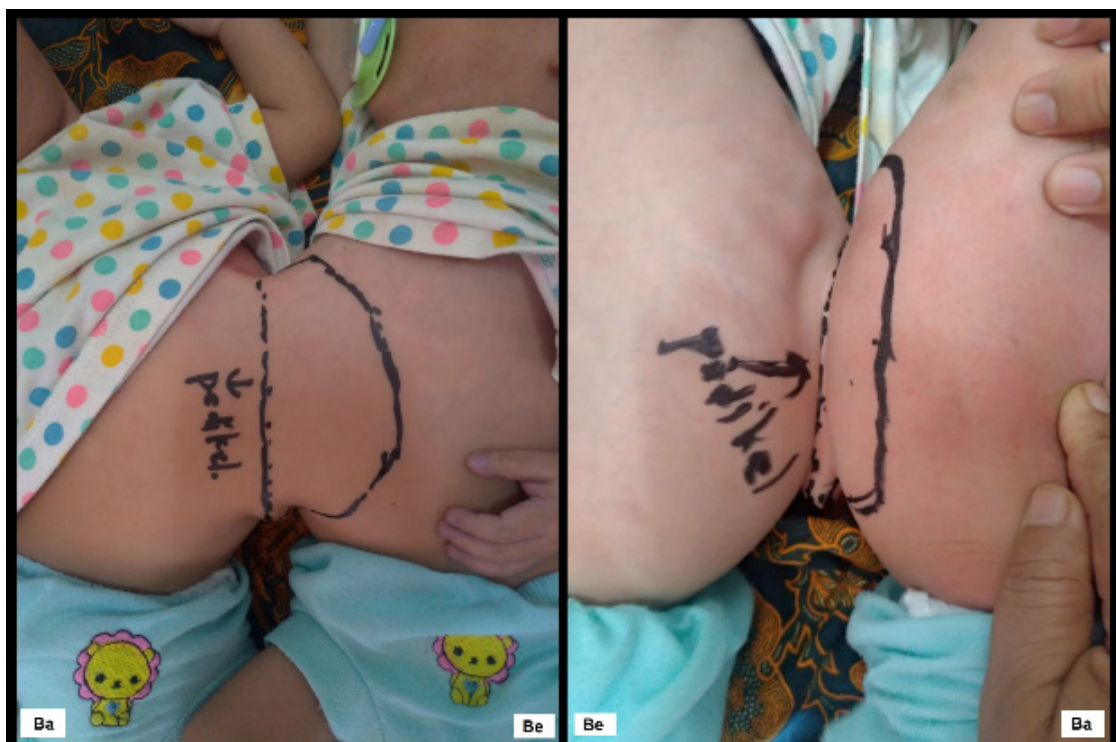

Figure 3. Surgical incision plan of omphalopagus separation. (Left) Anterior view. (Right) Posterior view.

underdeveloped ribs and sternum. Thus, the inferior portion of the sternum was connected to the cartilaginous rib with many ligations of secondary vascular connections. Finally, drainage and primary abdominal wall defect closure were performed using fascia and skin. The overall procedure took 10 hours to be accomplished. Be suffered oxygen desaturation, but returned to the normal range

above 97% one-hour after the surgery. Furthermore, the babies received approximately 35 cc of packed red blood cells intraoperatively. They satisfactorily tolerated the surgery, and we extubated them two hours later. Our cardiothoracic-vascular and interventional radiologists colleagues suggested delaying Be's POF surgery until age five.

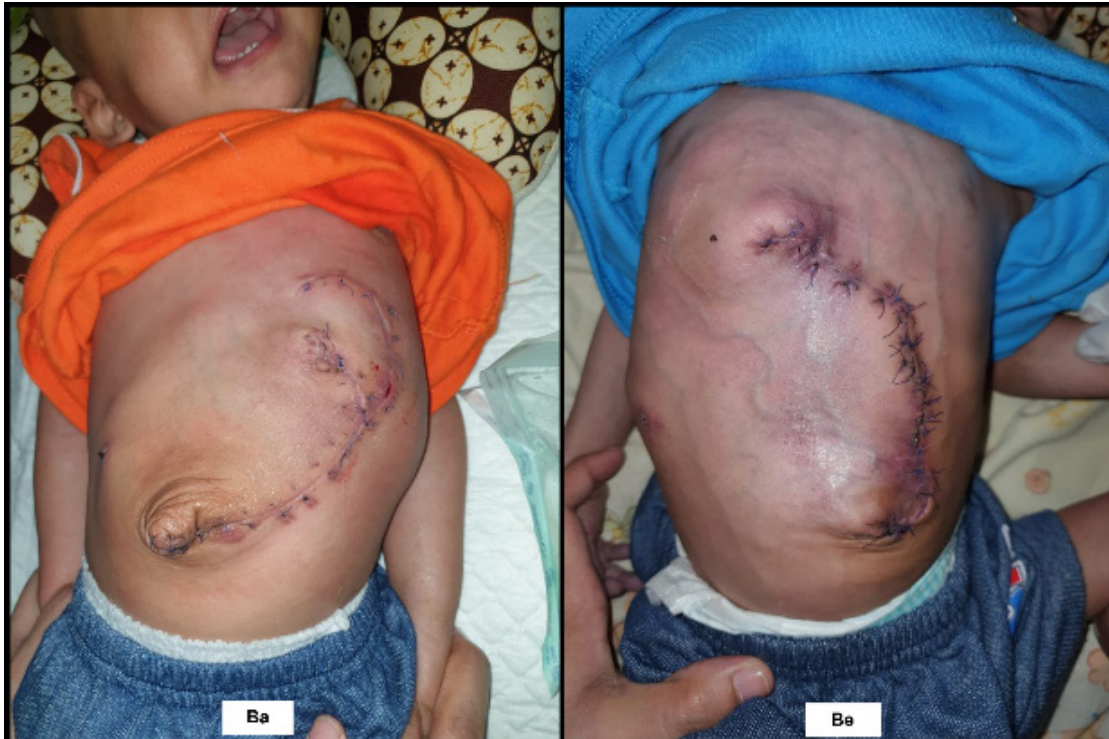

Figure 4. The twins on the seventh day of post-surgery.

Results

In the pediatric intensive care unit (PICU), Ampicillin-Sulbactam 50 mg/kg/12hours and Amoxicillin 45 mg/kg/12hours were administered intravenously until the ninth-day post-surgery to prevent MRSA infection (Nelson & Gallagher, 2012). Both babies also received antivirals (Lopinavir, Ritonavir), and Hydroxychloroquine due to high exposure and risk of COVID-19 infection and acute respiratory distress syndrome (ARDS) complications. The sutured skin was not infected (Figure 4). On the sixth-day post-surgery, we started to give 90 kcal/kg/day oral route feeding. The twins showed normal vital signs on the seventh days post-surgery. Meanwhile, Be remained cyanotic with 95% oxygen saturation. The SARS-CoV-2 PCR test results were negative before the hospital discharge. The patients were discharged after fifteen days. Two weeks later during hospital follow-up, they gained sufficient bodyweight of 10.3 kg and 10.1 kg for baby Ba and Be, respectively.

Discussion

Conjoined twins is an uncommon congenital case that leads to severe complications (Liu et al., 2021). The twins frequently share ventral parts of the cardiovascular and gastrointestinal systems. Omphalopagus twins are frequently connected to the umbilical cord, which involves the lower chest (Omran et al., 2020). However, the external anterior fusion is identical between the thoracopagus and omphalopagus. Thoracopagus has a conjunction of

the heart, while omphalopagus refers to those with separate hearts (Osmanağaoğlu et al., 2011). These differences define the prognosis and treatment, in which thoracopagus are almost inseparable (Grizelj et al., 2019).

Although omphalopagus twins have the best chances of survival, the surgical timing remains controversial. Several months delay offers a better chance of survival (Patil et al., 2016). However, early separation is indicated when one twin worsens the other's hemodynamic circulation. However, significant cardiac anomalies are contraindicated for separations (Sultan & Tawfeek, 2016).

Before omphalopagus separation, we considered the age, shared organs, organ anomalies, and possible bones and soft tissue defects post-surgery to improve the post-surgical outcomes (Zainuddin et al., 2021). However, the COVID-19 pandemic caused several challenges leading to surgical delays (Byrnes et al., 2021). In the absence of contraindication, separation is usually performed at three months. Meanwhile, early separation may cause recovery and wound closure disturbance (Sandy-Hodgetts et al., 2015). Moreover, late separation of more than ten months old can worsen the lung infection risk and aesthetic-developmental aspects (Mian et al., 2017). Besides MRSA and COVID-19 infection, Necrotizing enterocolitis (NEC) is one of the most reported pre-surgery and post-surgery complications in the omphalopagus (Omran et al., 2020). In this case, the age of 14 months offered beneficial protection from NEC, as the intestinal tissue was not prone to inflammation

or perforation (Pammi et al., 2020). In regard to nursing role, the overall medical condition should be assessed to establish adequate care of nurse plan based on disease severity (Wahyuningsih et al., 2020). Thus, prevention of infection is a major concern in pediatric nursing care units (Okpara, 2018).

The primary limitation of this study is no well-established consensus for omphalopagus surgery before or during the COVID-19 pandemic era. However, this successful omphalopagus separation strengthens personal-to-personal approach as conjoined twins is a complex medical issues requiring multi-disciplinary team consideration (Giwangkancana et al., 2022). In this case, we performed early surgery when both babies were stable. We followed Centers for Disease Control and Prevention guidelines to prevent COVID-19 infection (Reich & Elward, 2022). We used an N95 mask and standardized-level-3 hazmat suits. We also restricted the number of operating room staff during surgery, despite this case involved multidisciplinary team intervention. A mandatory SARS-CoV-2 PCR was also tested to surgical teams.

Conclusions

A successful 10-hour omphalopagus separation was performed by pediatric, cardiothoracic, and plastic surgeons. In the early phase of the COVID-19 pandemic and with the lack of evidence-based recommendations for hospital care during COVID-19 in Indonesia, a well-established basic knowledge about the COVID-19 transmission routes and well-planned surgery strategies were mandatory to be understood. Aside from several surgical considerations, a life-saving omphalopagus separation from death due to complications of COVID-19 infection and ARDS must be prioritized. Moreover, nursing care should consider comprehensive outcome including history taking, patient assessment on admission, vital sign monitoring, operative care, especially prevention of infection in this present case. Furthermore, social-psychological-emotional supports could enhance the compliance to medication leading to better medical outcomes.

Declaration of Interest

The authors confirm that they have no competing interests.

Acknowledgment

The authors thank all surgery colleagues of Dr. Moewardi General Hospital for providing manuscript proofreading and feedback.

Funding

The authors did not receive any funding or grant for this publication.

Data Availability

The supplementary data are available on reasonable request. Please contact by e-mail belllyndamonica@gmail.com.

References

- Bassetti, M., Magnasco, L., Vena, A., Portunato, F., & Giacobbe, D. R. (2022). Methicillin-resistant *Staphylococcus aureus* lung infection in coronavirus disease 2019: How common?. *Current Opinion in Infectious Diseases*, 35(2), 149–162. <https://doi.org/10.1097/QCO.0000000000000813>
- Byrnes, M. E., Brown, C. S., De Roo, A. C., Corriere, M. A., Romano, M. A., Fukuhara, S., Kim, K. M., & Osborne, N. H. (2021). Elective surgical delays due to COVID-19. *Medical Care*, 59(4), 288–294. <https://doi.org/10.1097/MLR.0000000000001503>
- Giwangkancana, G., Kusmayadi, D. D., Kadi, F., Utariani, A., & Haryawan, Z. (2022). The multidisciplinary perioperative management of conjoined twin separation surgery during the pandemic. *Journal of Multidisciplinary Healthcare*, 15, 2669–2678. <https://doi.org/10.2147/JMDH.S390419>
- Grizelj, R., Dessardo, N. S., Bulić, K., Luetić, T., Mikulić, D., Antabak, A., Sjekavica, I., Alduk, A. M., Konosić, S., Tomašić, K. R., Čaleta, T., Pleško, S., Šarić, D., & Vuković, J. (2019). Successful separation of xypho-omphalopagus conjoined twins with extrauterine twin-twin transfusion syndrome: A case report. *Croatian Medical Journal*, 60(4), 301. <https://doi.org/10.3325/CMJ.2019.60.301>
- Yosep, S. K. . M. S. . P. ., Hikmat, R., & Mardhiyah, A. (2022). The impact of domestic violence on cognitive and psychological development of children: A scoping review. *Jurnal Keperawatan Padjadjaran*, 10(3), 196–203. <https://doi.org/10.24198/JKP.V10I3.2076>
- Liu, H., Deng, C., Hu, Q., Liao, H., Wang, X., & Yu, H. (2021). Conjoined twins in dichorionic diamniotic triplet pregnancy: A report of three cases and literature review. *BMC Pregnancy and Childbirth*, 21(1), 687. <https://doi.org/10.1186/s12884-021-04165-x>
- Mian, A., Gabra, N. I., Sharma, T., Topale, N., Gielecki, J., Tubbs, R. S., & Loukas, M. (2017). Conjoined twins: From conception to separation, a review. *Clinical Anatomy*, 30(3), 385–396. <https://doi.org/10.1002/ca.22839>
- Mutchinick, O. M., Luna-Muñoz, L., Amar, E., Bakker, M. K., Clementi, M., Cocchi, G., da Graça Dutra, M., Feldkamp, M. L., Landau, D., Leoncini, E., Li, Z., Lowry, B., Marengo, L. K., Martínez-Frías, M.-L., Mastroiacovo, P., Métneki, J., Morgan, M., Pierini, A., Rissman, A., ... Arteaga-Vázquez, J. (2011). Conjoined twins: A worldwide collaborative epidemiological study

Bellynda, M., et al. (2023)

- of the International Clearinghouse for birth defects surveillance and research. *American Journal of Medical Genetics Part C: Seminars in Medical Genetics*, 157(4), 274–287. <https://doi.org/10.1002/ajmg.c.30321>
- Nelson, M. U., & Gallagher, P. G. (2012). Methicillin-resistant *Staphylococcus aureus* in the neonatal intensive care unit. *Seminars in Perinatology*, 36(6), 424–430. <https://doi.org/10.1053/j.semperi.2012.06.004>
- Okpara, P. (2018). Challenges of nursing care of the paediatric surgical patient. *African Journal of Paediatric Surgery*, 15(3), 154. https://doi.org/10.4103/ajps.AJPS_28_13
- Omran, A., Nassif, M., Salhab, N., Abdo, A., Ahmad, M., Alkhalil, A., Taishori, N., & Dayoub, A. (2020). Early separation of omphalopagus conjoined twins: A case report from Syria. *Journal of Surgical Case Reports*, 2020(1), 1–3. <https://doi.org/10.1093/JSCR/RJZ374>
- Osmanağaoğlu, M. A., Aran, T., Güven, S., Kart, C., Özdemir, Ö., & Bozkaya, H. (2011). Thoracopagus conjoined twins: A case report. *ISRN Obstetrics and Gynecology*, 2011, 1–3. <https://doi.org/10.5402/2011/238360>
- Pammi, M., De Plaen, I. G., & Maheshwari, A. (2020). Recent advances in necrotizing enterocolitis research. *Clinics in Perinatology*, 47(2), 383–397. <https://doi.org/10.1016/j.clp.2020.02.011>
- Patil, P. S., Kothari, P., Gupta, A., Kekre, G., Dikshit, K. V., Kamble, R., & Deshmukh, S. (2016). Successful separation of omphalopagus twins: A case report. *Journal of Neonatal Surgery*, 5(1), 5. <http://www.ncbi.nlm.nih.gov/pubmed/26793597>
- Poudel, D., Shrestha, S., Aryal, R., Adhikari, A., & Bajracharya, S. (2022). Thoraco-omphalopagus conjoined twin: A rare case report. *International Journal of Surgery Case Reports*, 99, 107683. <https://doi.org/10.1016/j.ijscr.2022.107683>
- Reich, P., & Elward, A. (2022). Infection prevention during the coronavirus disease 2019 pandemic. *Infectious Disease Clinics of North America*, 36(1), 15–37. <https://doi.org/10.1016/j.idc.2021.12.002>
- Sandy-Hodgetts, K., Carville, K., & Leslie, G. D. (2015). Determining risk factors for surgical wound dehiscence: A literature review. *International Wound Journal*, 12(3), 265–275. <https://doi.org/10.1111/iwj.12088>
- Sultan, O. M., & Tawfeek, A. S. (2016). Conjoined twins—thoraco-omphalopagus (type A). *BJR | Case Reports*, 2(1), 20150016. <https://doi.org/10.1259/BJRCR.20150016>
- Tan, T. Q., Gunardi, H., Smith, S., Goentoro, P. L., Foehringer Merchant, H., Carter, T., Patterson, J., & Pulungan, A. (2020). Global immunization systems strengthening through pediatric societies: The promise of private–public partnerships in Indonesia. *Human Vaccines & Immunotherapeutics*, 16(5), 1194–1201. <https://doi.org/10.1080/21645515.2019.1697108>
- Van Klei, W. A., Hoff, R. G., van Aarnhem, E. E. H. L., Simmermacher, R. K. J., Regli, L. P. E., Kappen, T. H., van Wolfswinkel, L., Kalkman, C. J., Buhre, W. F., & Peelen, L. M. (2012). Effects of the introduction of the WHO “surgical safety checklist” on in-hospital mortality. *Annals of Surgery*, 255(1), 44–49. <https://doi.org/10.1097/SLA.0b013e31823779ae>
- Wahyuningsih, I. S., Janitra, F. E., Hapsari, R., Sarinti, S., Mahfud, M., & Wibisono, F. (2020). The nurses’ experience during the caring of coronavirus (COVID-19) patients: A descriptive qualitative study. *Jurnal Keperawatan Padjadjaran*, 8(3), 255–263. <https://doi.org/10.24198/jkp.v8i3.1559>
- Zainuddin, N., Ishak, A., & Draman, N. (2021). Omphalopagus conjoined twins: A case report. *Bangladesh Journal of Medical Science*, 20(3), 642–645. <https://doi.org/10.3329/bjms.v20i3.52808>